

Wynn Kapit / Lawrence M. Elson

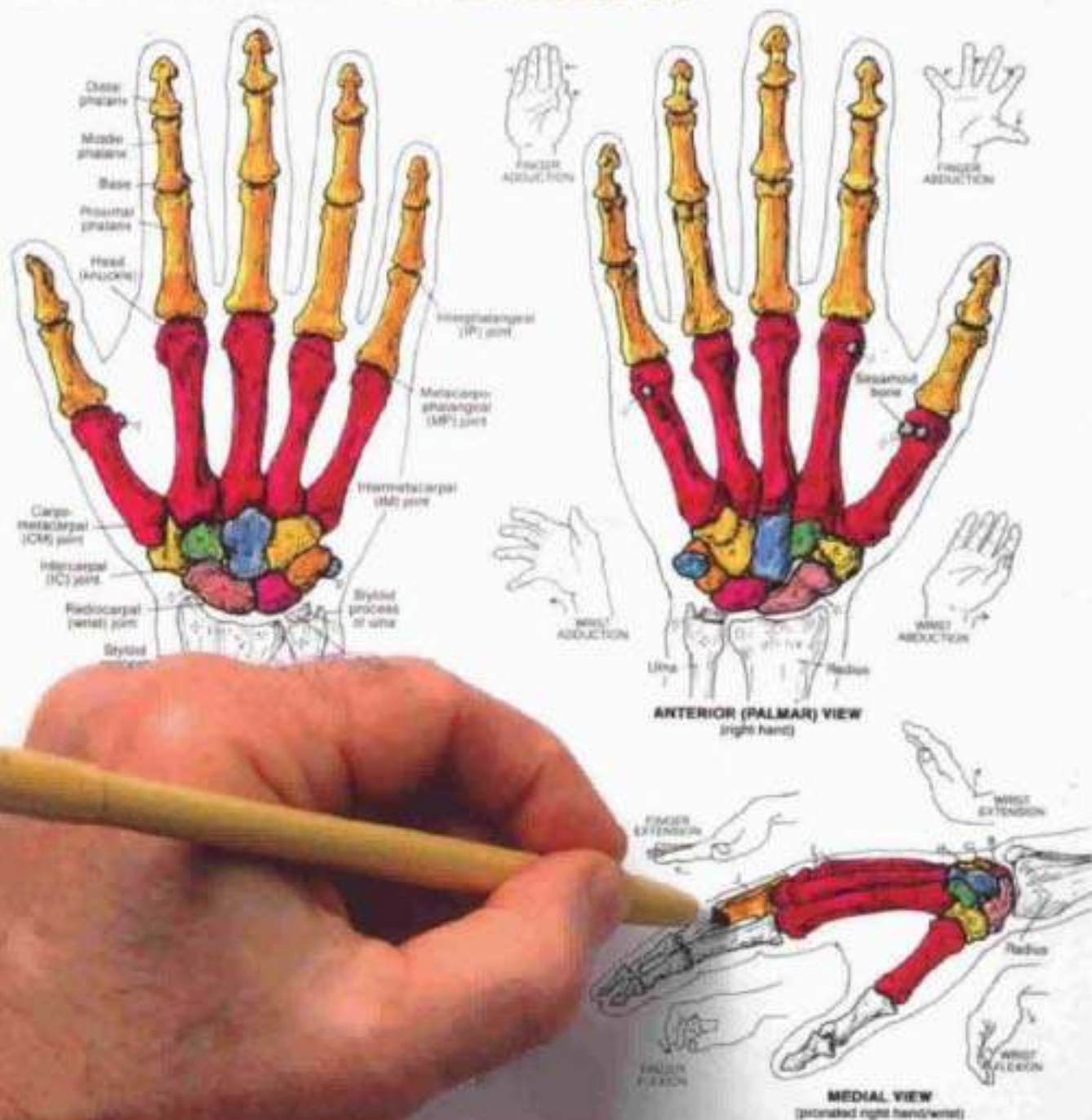
The "Classic"  
Over 25 million in print

# The ANATOMY COLORING BOOK

**CARPALS (8):**

**SCAPHOID, LUNATE, TRIQUETRUM, PISIFORM,  
TRAPEZIUM, TRAPEZOID, CAPITATE, HAMATE.**

**METACARPALS (5): PHALANGES (14).**



# TABLE OF CONTENTS

- VI PREFACE
- ACKNOWLEDGEMENTS
- VIII EXTREMELY IMPORTANT TIPS  
(On how to get the most out of this book)

## INTRODUCTION

- 1 Anatomic Planes and Sections
- 2 Terms of Position and Direction

## I ORGANIZATION OF THE BODY

- 3 The Generalized Cell
- 4 Cell Division/Mitosis
- 5 Tissues: Epithelium
- 6 Tissues: Fibrous Connective Tissues
- 7 Tissues: Supporting Connective Tissue
- 8 Tissues: Endochondral Ossification
- 9 Tissues: Muscle
- 10 Tissues: Skeletal Muscle Structure
- 11 Tissues: Nervous
- 12 Integration of Tissues

## II SYSTEMS AND REGIONS

- 13 Systems of the Body (1)
- 14 Systems of the Body (2)
- 15 Regions of the Body
- 16 Cavities and Linings

## III SKELETAL SYSTEM

- 17 Anatomy of a Long Bone
- 18 Axial/Appendicular Skeleton
- 19 Bones of the Skull (1)
- 20 Bones of the Skull (2)
- 21 Vertebral Column
- 22 Cervical and Thoracic Vertebrae
- 23 Lumbar, Sacral, and Coccygeal Vertebrae
- 24 Bony Thorax
- 25 Upper Limb: Pectoral Girdle/Arm Bone
- 26 Upper Limb: Forearm Bones
- 27 Upper Limb: Wrist and Hand Bones
- 28 Upper Limb: Bones in Review
- 29 Lower Limb: Coxal Bone, Pelvic Girdle, and Pelvis
- 30 Lower Limb: Thigh and Leg Bones
- 31 Lower Limb: Ankle and Foot Bones
- 32 Lower Limb: Bones in Review

**IV ARTICULAR SYSTEM**

- 33 Classification of Joints
- 34 Terms of Movement

**V MUSCULAR SYSTEM**

- 35 Introduction
- 36 Neuromuscular Junction/Motor Unit
- 37 Integration of Muscle Action
- 38 Head: Muscles of Facial Expression
- 39 Head: Muscles of Mastication
- 40 Neck: Anterior and Lateral Muscles
- 41 Torso: Deep Muscles of Back and Posterior Neck
- 42 Torso: Muscles of Thorax and Posterior Abdominal Wall
- 43 Torso: Muscles of Anterior Abdominal Wall and Inguinal Region
- 44 Torso: Muscles of the Pelvis
- 45 Torso: Muscles of the Perineum
- 46 Upper Limb: Muscles of Scapular Stabilization
- 47 Upper Limb: Muscles of Musculotendinous Cuff
- 48 Upper Limb: Movers of Shoulder Joint
- 49 Upper Limb: Movers of Elbow and Radioulnar Joints
- 50 Upper Limb: Movers of Wrist and Hand Joints
- 51 Upper Limb: Movers of Hand Joints (Intrinsics)
- 52 Upper Limb: Summary of Muscle Groups
- 53 Lower Limb: Muscles of Gluteal Region
- 54 Lower Limb: Muscles of Posterior Thigh
- 55 Lower Limb: Muscles of Medial Thigh
- 56 Lower Limb: Muscles of Anterior Thigh
- 57 Lower Limb: Muscles of Anterior and Lateral Leg
- 58 Lower Limb: Muscles of Posterior Leg
- 59 Lower Limb: Muscles of the Foot (Intrinsics)
- 60 Lower Limb: Summary of Muscle Groups
- 61 Skeletal Musculature: Functional Overview

**VI CARDIOVASCULAR SYSTEM**

- 62 Blood and Blood Elements
- 63 Scheme of Blood Circulation
- 64 Blood Vessels
- 65 Mediastinum, Walls, and Covering of the Heart
- 66 Chambers of the Heart  
Circulation Through the Heart
- 67 Cardiac Conduction System and the ECG
- 68 Coronary Arteries and Cardiac Veins
- 69 Arteries of the Head and Neck
- 70 Arteries of the Brain
- 71 Arteries and Veins of the Upper Limb
- 72 Arteries of the Lower Limb
- 73 The Aorta and Branches
- 74 Arteries to Gastrointestinal Tract and Related Organs
- 75 Arteries of the Pelvis and Perineum
- 76 Review of Principal Arteries
- 77 Veins of the Head and Neck
- 78 Caval and Azygos Systems
- 79 Veins of the Lower Limb
- 80 Hepatic Portal System
- 81 Review of the Principal Veins
- 82 Fetal Circulation

## **VII LYMPHATIC SYSTEM**

- 83 Lymphatic System
- Lymphocyte Circulation

## **VIII IMMUNE (LYMPHOID) SYSTEM**

- 84 Introduction
- 85 Natural and Acquired Immunity
- 86 Thymus and Red Marrow
- 87 Spleen
- 88 Lymph Node
- 89 Mucosal Associated Lymphoid Tissue (M.A.L.T.)
- 90 HIV-Induced Immunosuppression

## **IX RESPIRATORY SYSTEM**

- 91 Overview of the Respiratory System
- 92 External Nose, Nasal System, and Nasal Cavity
- 93 Paranasal Air Sinuses
- 94 Pharynx and Larynx
- 95 Lobes and Pleurae of the Lungs
- 96 Lower Respiratory Tract
- 97 Mechanism of Respiration

## **X DIGESTIVE SYSTEM**

- 98 Overview of the System
- 99 Oral Cavity and Tongue
- 100 Anatomy of a Tooth: Adult/Child Dentition
- 101 Pharynx and Esophagus
- 102 Peritoneum
- 103 Stomach
- 104 Small Intestine: Duodenum, Jejunum, Ileum
- 105 Large Intestine
- 106 Liver
- 107 Biliary System; Pancreas

## **XI URINARY SYSTEM**

- 108 Urinary Tract
- 109 Kidneys and Related Retroperitoneal Structures
- 110 Kidney Structure
- 111 Uriniferous Tubule
- 112 Renal Circulation

## **XII REPRODUCTIVE SYSTEM**

- 113 Male Reproductive System
- 114 Testis
- 115 Male Urogenital Structures
- 116 Female Reproductive System
- 117 Ovary
- 118 Uterus, Uterine Tubes, and Vagina
- 119 Menstrual Cycle
- 120 Breast (Mammary Gland)
- 121 Development of Embryo (1)
- 122 Development of Embryo (2)
- 123 Embryo/Fetus Coverings



## XIII ENDOCRINE SYSTEM

- 124 Introduction
- 125 Pituitary Gland and Hypothalamus
- 126 Pituitary Gland and Target Organs
- 127 Thyroid and Parathyroid Glands
- 128 Adrenal (Suprarenal) Glands
- 129 Pancreatic Islets

## XIV NERVOUS SYSTEM

- 130 Organization of the Nervous System
- 131 Functional Classification of Neurons
- 132 Synapses and Neurotransmitters
- 133 Development of Central Nervous System
- 134 Cerebral Hemispheres
- 135 Tracts and Nuclei of Cerebral Hemispheres
- 136 Diencephalon
- 137 Brain Stem/Cerebellum
- 138 Spinal Cord
- 139 Ascending Tracts
- 140 Descending Tracts
- 141 Ventricles of the Brain
- 142 Meninges
- 143 Circulation of Cerebrospinal Fluid (CSF)
- 144 Cranial Nerves
- 145 Spinal Nerves and Nerve Roots
- 146 Stretch Reflexes
- 147 Distribution of Spinal Nerves
- 148 Nerves of the Upper Limb
- 149 Nerves of the Lower Limb
- 150 Dermatomes
- 151 ANS: Sympathetic Division (1)
- 152 ANS: Sympathetic Division (2)
- 153 ANS: Parasympathetic Division
- 154 Somesthetic Sensation
- 155 Special Senses: Visual System (1)
- 156 Special Senses: Visual System (2)
- 157 Special Senses: Visual System (3)
- 158 Special Senses: Auditory and Vestibular Systems (1)
- 159 Special Senses: Auditory and Vestibular Systems (2)
- 160 Special Senses: Taste and Olfaction

## XV INTEGUMENTARY SYSTEM

- 161 The Integument

### BIBLIOGRAPHY AND REFERENCES

APPENDIX A: ANSWER KEYS (PLATES 28, 76, 81)

APPENDIX B: INNERVATION OF SKELETAL MUSCLES

GLOSSARY

INDEX

## EXTREMELY IMPORTANT TIPS

(On how to get the most out of this book)

1. Please review this section before coloring the book. The short time required to read through these tips will enable you to get the most benefit from the book. After learning the meaning of a few symbols used throughout, and reading some basic instructions on how to proceed, common sense will normally dictate the manner in which you color each plate. It is advisable to occasionally review these notes until such time that you feel completely at home with the coloring format.

2. Look over the table of contents. Note the arrangement of plates, organized into introductory, general body organization, systemic and regional organization, and specific system topics are organized according to body system (systemic anatomy). If you are unfamiliar with the study of anatomy, be sure to color the plates on terminology (1 and 2) and introduction to systems and regions (13-16) first.

3. Turn now to any plate of the book and note the following:

a. At the top of each plate are coloring notes (CN) which provides specific guidance in coloring that particular plate. Be sure to read these before coloring. The CN will usually recommend certain colors for specific subscripts, direct the order of coloring, and explain any ambiguities that might arise. Whether you color the plate first and then read the text, or read the text first and then color, is your decision . . . whichever works best for you.

b. A glance at the front or back cover will illustrate the basic principle of this coloring format: each "title" (a term in colorable outline letters) followed by a small, lettered subscript should receive a different color. After coloring the title, you should then search through the illustration(s) and color any structure identified with that subscript, using the same color as the title. Unless you run out of colors, you should not repeat that color for any other subscripted title or structure. Occasionally, title subscripts will appear with a numbered superscript, e.g., A<sup>1</sup>, A<sup>2</sup>, and so on. These titles and related structures get the same color because of the strong relationship between the structures.

c. Take care to color the titles first. In many instances the subscript identifying a structure is embedded within the structure. If you use a dark color for the structure, you may obscure the identifying subscript. This can be avoided by simply coloring the title first, and then the related structure.

d. Related plates (cross references) are noted under the plate number in the upper right corner ("see . . .").

4. The more colors you have at your disposal, the more effective, as well as enjoyable, your coloring will be. A minimum of twelve colors, including gray, is essential. Lighter colors are preferable because they are less likely to cover up surface detail or identifying subscripts. Gray is an important color for column headings and miscellaneous uses. Whether you use felt-tipped pens or colored pencils makes no difference, provided their points are sharp enough for detail work. Crayons won't do. Buying colors individually at art supply or stationery stores will enable you to choose from a lighter range, as well as provide the opportunity to replace individual colors when they are exhausted.

5. This book does not have to be colored in any specific order, but the individual chapters (indicated by Roman numerals, I, II, and so on) should be colored in numerical order. This is because there are times in which you will be asked to repeat colors used on previous plates, creating a color-coordinated set of interrelated plates on a region or structure. However, you may find that certain plates deal with material the technical nature of which exceeds your needs; in these cases, you may wish to skip the plate(s).

6. Generally, you will be able to choose colors as you wish. Occasionally, you will be asked to use specific colors recommended for structures that are universally colored one color in atlases: red for arteries, blue for veins, purple for capillaries, yellow for nerves, and green for lymph vessels and lymph nodes. It is usually preferable to employ lighter colors for the largest areas, and darker or brighter colors for the smallest areas.

7. Dark outlines provide the boundaries between areas receiving different colors (identified by different subscripts). In some illustrations, there are repeated identical structures; for example, numbers of cells, vessels, lobules, and so on. Not every one of those structures may be labeled. You should, however, color all of them unless otherwise indicated by the "don't color" symbol. In those plates with a lot of detail, the identification of different subscripted areas/structures and "no color" areas will have to be pursued diligently before coloring, to prevent mistakes.

8. Symbols used throughout are:

	= don't color		= color gray
NS	= not shown		= color black
	= outline of a structure seen below the surface of another		

9. In the text and titles, the following abbreviations may precede or follow the names of the structures identified, e.g. POST. AURICULAR M., BRACHIAL A., SCALENUS MED. M.

A	= Artery
Ant.	= Anterior
Br	= Branch
Inf.	= Inferior
Int.	= Internal
Lat.	= Lateral
Lig.	= Ligament
M., Mus.	= Muscle
Med. (preceding term)	= Medial
Med. (after term)	= Medus
N.	= Nerve
Post.	= Posterior
Sup.	= Superior, superficial
Sys.	= System
Tr.	= Tract
V.	= Vein

## EXTREMELY IMPORTANT TIPS

(On how to get the most out of this book)

1. Please review this section before coloring the book. The short time required to read through these tips will enable you to get the most benefit from the book. After learning the meaning of a few symbols used throughout, and reading some basic instructions on how to proceed, common sense will normally dictate the manner in which you color each plate. It is advisable to occasionally review these notes until such time that you feel completely at home with the coloring format.

2. Look over the table of contents. Note the arrangement of plates, organized into introductory, general body organization, systemic and regional organization, and specific system topics are organized according to body system (systemic anatomy). If you are unfamiliar with the study of anatomy, be sure to color the plates on terminology (1 and 2) and introduction to systems and regions (13-16) first.

3. Turn now to any plate of the book and note the following:

a. At the top of each plate are coloring notes (CN) which provides specific guidance in coloring that particular plate. Be sure to read these before coloring. The CN will usually recommend certain colors for specific subscripts, direct the order of coloring, and explain any ambiguities that might arise. Whether you color the plate first and then read the text, or read the text first and then color, is your decision . . . whichever works best for you.

b. A glance at the front or back cover will illustrate the basic principle of this coloring format: each "title" (a term in colorable outline letters) followed by a small, lettered subscript should receive a different color. After coloring the title, you should then search through the illustration(s) and color any structure identified with that subscript, using the same color as the title. Unless you run out of colors, you should not repeat that color for any other subscripted title or structure. Occasionally, title subscripts will appear with a numbered superscript, e.g., A<sup>1</sup>, A<sup>2</sup>, and so on. These titles and related structures get the same color because of the strong relationship between the structures.

c. Take care to color the titles first. In many instances the subscript identifying a structure is embedded within the structure. If you use a dark color for the structure, you may obscure the identifying subscript. This can be avoided by simply coloring the title first, and then the related structure.

d. Related plates (cross references) are noted under the plate number in the upper right corner ("see . . .").

4. The more colors you have at your disposal, the more effective, as well as enjoyable, your coloring will be. A minimum of twelve colors, including gray, is essential. Lighter colors are preferable because they are less likely to cover up surface detail or identifying subscripts. Gray is an important color for column headings and miscellaneous uses. Whether you use felt-tipped pens or colored pencils makes no difference, provided their points are sharp enough for detail work. Crayons won't do. Buying colors individually at art supply or stationery stores will enable you to choose from a lighter range, as well as provide the opportunity to replace individual colors when they are exhausted.



5. This book does not have to be colored in any specific order, but the individual chapters (indicated by Roman numerals, I, II, and so on) should be colored in numerical order. This is because there are times in which you will be asked to repeat colors used on previous plates, creating a color-coordinated set of interrelated plates on a region or structure. However, you may find that certain plates deal with material the technical nature of which exceeds your needs; in these cases, you may wish to skip the plate(s).

6. Generally, you will be able to choose colors as you wish. Occasionally, you will be asked to use specific colors recommended for structures that are universally colored one color in atlases: red for arteries, blue for veins, purple for capillaries, yellow for nerves, and green for lymph vessels and lymph nodes. It is usually preferable to employ lighter colors for the largest areas, and darker or brighter colors for the smallest areas.

7. Dark outlines provide the boundaries between areas receiving different colors (identified by different subscripts). In some illustrations, there are repeated identical structures; for example, numbers of cells, vessels, lobules, and so on. Not every one of those structures may be labeled. You should, however, color all of them unless otherwise indicated by the "don't color" symbol. In those plates with a lot of detail, the identification of different subscripted areas/structures and "no color" areas will have to be pursued diligently before coloring, to prevent mistakes.

8. Symbols used throughout are:

⊖	= don't color	★	= color gray
NS	= not shown	●	= color black
	= outline of a structure seen below the surface of another		

9. In the text and titles, the following abbreviations may precede or follow the names of the structures identified, e.g. POST. AURICULAR M., BRACHIAL A., SCALENUS MED. M.

A	= Artery
Ant.	= Anterior
Br	= Branch
Inf.	= Inferior
Int.	= Internal
Lat.	= Lateral
Lig.	= Ligament
M., Mus.	= Muscle
Med. (preceding term)	= Medial
Med. (after term)	= Medus
N.	= Nerve
Post.	= Posterior
Sup.	= Superior, superficial
Sys.	= System
Tr.	= Tract
V.	= Vein

# INTRODUCTION

## ANATOMIC PLANES & SECTIONS

CR: (1) Color the four body planes and related sections of the body in very light colors. (2) Take care not to color in areas marked by "do not color" (X) symbols.

Study of the human body (anatomy) requires visualization of internal regions or parts. Dissection (dis, apart, section) is the name given to preparing the body for internal inspection. One method of dissection permits consistent visual orientation by cutting the body into parts or sections along fixed lines of reference called planes. Two of these planes are oriented along the long axis of the body or body part, one perpendicular to the other (longitudinal sections). The third plane is oriented perpendicular to or across the long axis of the body or body part (cross section). Such planes have application in medical imaging studies, such as computerized tomography (CT) and magnetic resonance imaging (MRI). Here the body interior is imaged as computerized "slices" of the body in sagittal, coronal and transverse planes.

### MEDIAN

The midline, longitudinal plane dividing the head and torso into right/left halves. The presence of the vertebral column and spinal cord is characteristic of the median plane of the torso. The median plane is the middle sagittal plane.

### SAGITTAL

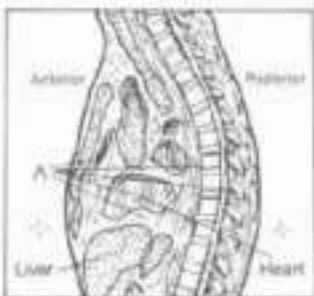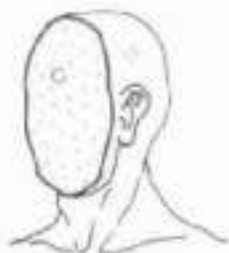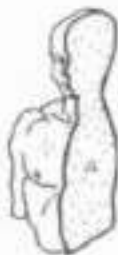The longitudinal plane dividing the body into left and right parts. It is parallel to the median plane and may be applied to the head, torso and limbs.

### CORONAL, FRONTAL

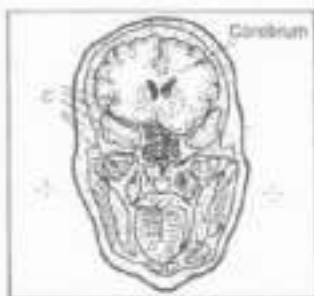
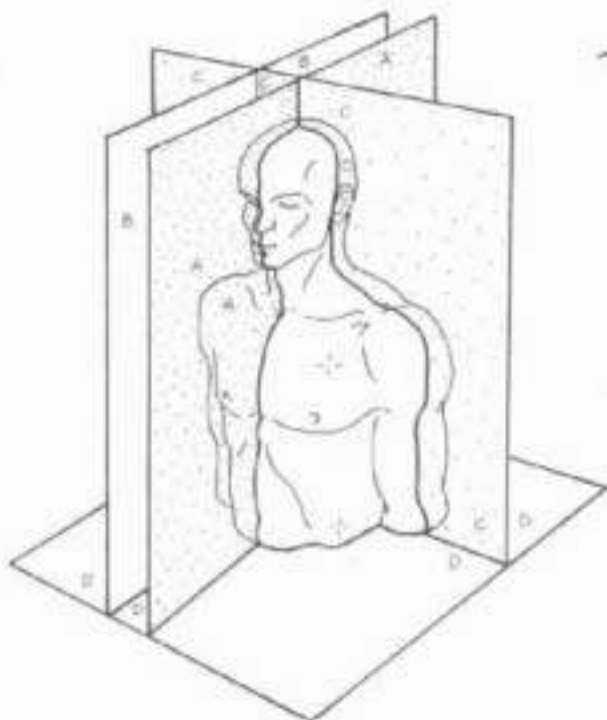
The longitudinal plane dividing the body into equal or unequal front and back parts. In CT and MRI, the term "coronal" is used by radiologists.

### CROSS, TRANSVERSE

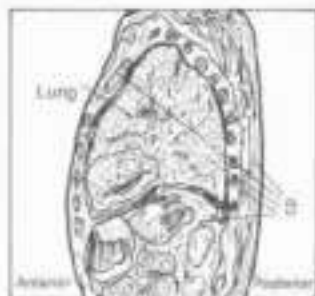
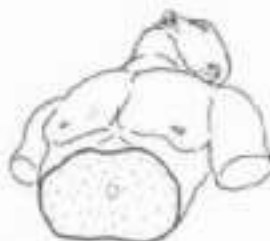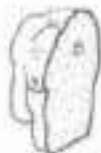The transverse plane dividing the body or body parts into upper and lower segments. This plane is a cross section perpendicular to the longitudinal planes. Transverse planes of the body, called axial or transaxial sections by radiologists, are commonly seen in CT and MRI studies of the body.



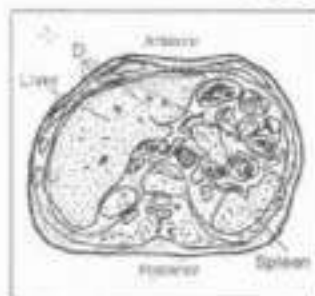
Median section through the thorax.



Coronal section through the head.



Sagittal section through the thorax.



Cross section through the abdomen.

## INTRODUCTION

### TERMS OF POSITION & DIRECTION

- ON: (1) Use light or dark colors for emphasis.  
(2) Color the arrows but not the illustrations.

Terms of position and direction describe the relationship of one organ to another, usually along one of the three body planes illustrated in the previous plate. To avoid confusion, these terms are related to the standard anatomical position: body standing erect, limbs extended, palms of the hands forward.

#### CRANIAL, SUPERIOR, ROSTRAL

These terms refer to a structure being closer to the head or higher than another structure of the body. See the quadruped in the right corner for a related application of the term "cranial."

#### ANTERIOR, VENTRAL

These terms refer to a structure being more in front than another structure in the body. The term "anterior" is preferred. See the quadruped for another application of the term "ventral."

#### POSTERIOR, DORSAL

These terms refer to a structure being more in back than another structure in the body. The term "posterior" is preferred. See the quadruped for another application of the term "dorsal."

#### MEDIAL

This term refers to a structure that is closer to the median plane than another structure in the body. "Medial" is not synonymous with "median."

#### LATERAL

This term refers to a structure that is further away from the median plane than another structure in the body.

#### PROXIMAL

Employed only with reference to the limbs, this term refers to a structure being closer to the median plane or root of the limb than another structure in the limb.

#### DISTAL

Employed only with reference to the limbs, this term refers to a structure being further away from the median plane or the root of the limb than another structure in the limb.

#### CAUDAL, INFERIOR

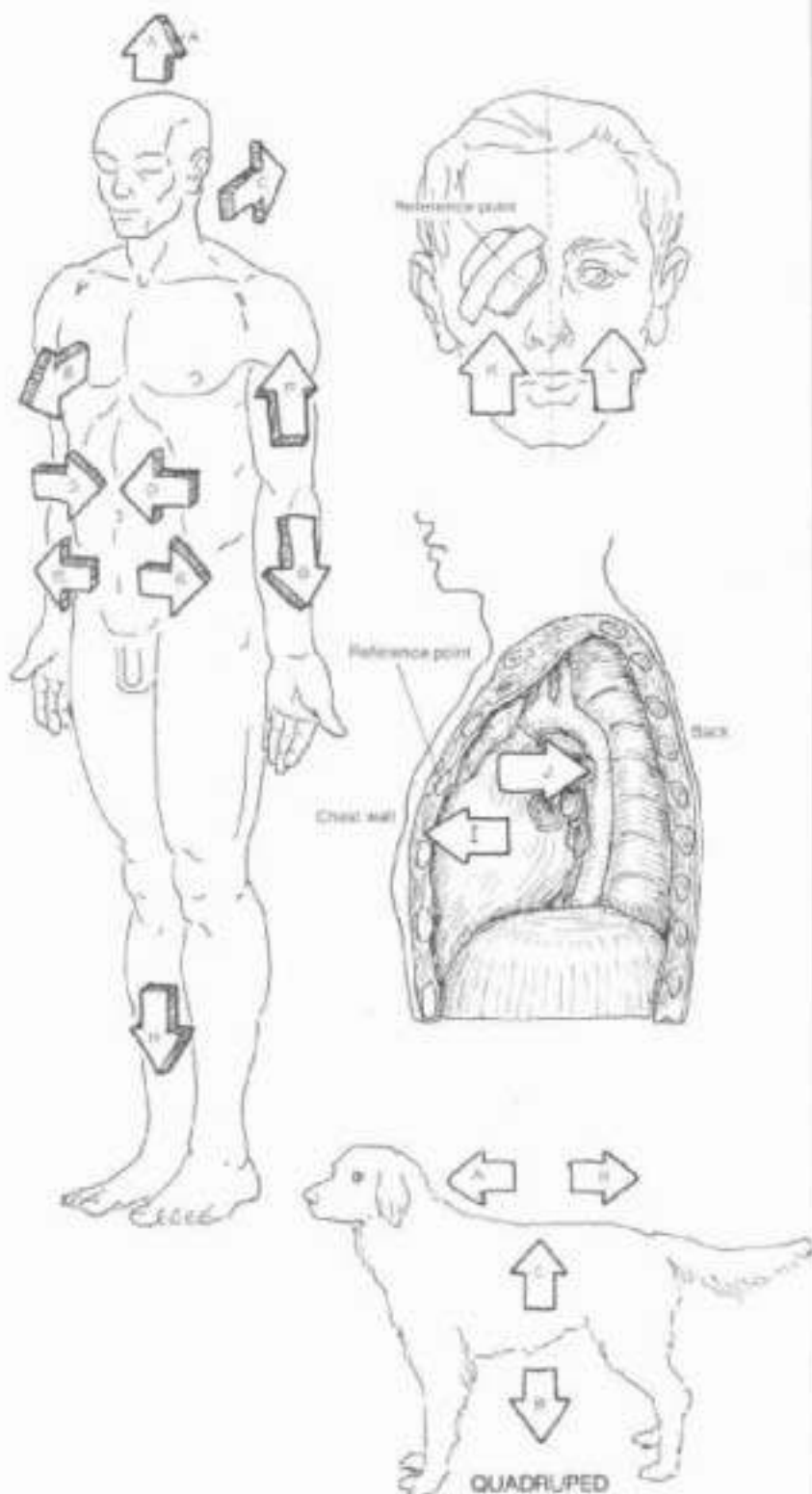
These terms refer to a structure being closer to the feet or the lower part of the body than another structure in the body. See the quadruped for a related application of the term "caudal."

#### SUPERFICIAL, DEEP

The term "superficial" is synonymous with external and the term "deep" with internal. Related to the reference point on the chest wall, structure closer to the surface of the body is superficial; structure further away from the surface is deep.

#### IPSILATERAL, CONTRALATERAL

The term "ipsilateral" means "on the same side" (in this case, as the reference point); "contralateral" means "on the opposite side" (of the reference point).



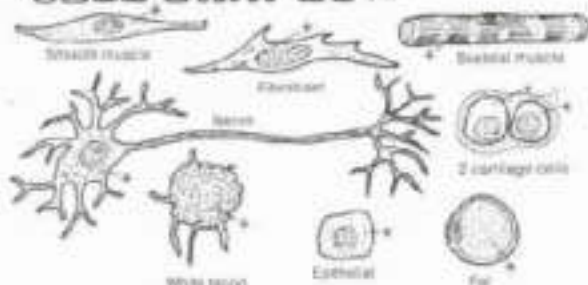
The quadruped presents four points of direction: head end (cranial), tail end (caudal), belly side (ventral), back side (dorsal). In the biped (e.g., human), the ventral side is also anterior, the dorsal side is also posterior, the cranial end is also superior, and the caudal end is inferior.

# I. ORGANIZATION OF THE BODY

## THE GENERALIZED CELL

CN. Color gray the variety of cell shapes at upper left. Use lightest colors for A, B, C, D, F and G. (1) Small circles representing ribosomes (R) are found throughout the cytoplasm (C) and on the rough endoplasmic reticulum (ER); color those larger areas, including the ribosomes, first, and then color over the ribosomes again with a darker color. Each organite shown is just one of many found in the living cell.

### CELL SHAPES:



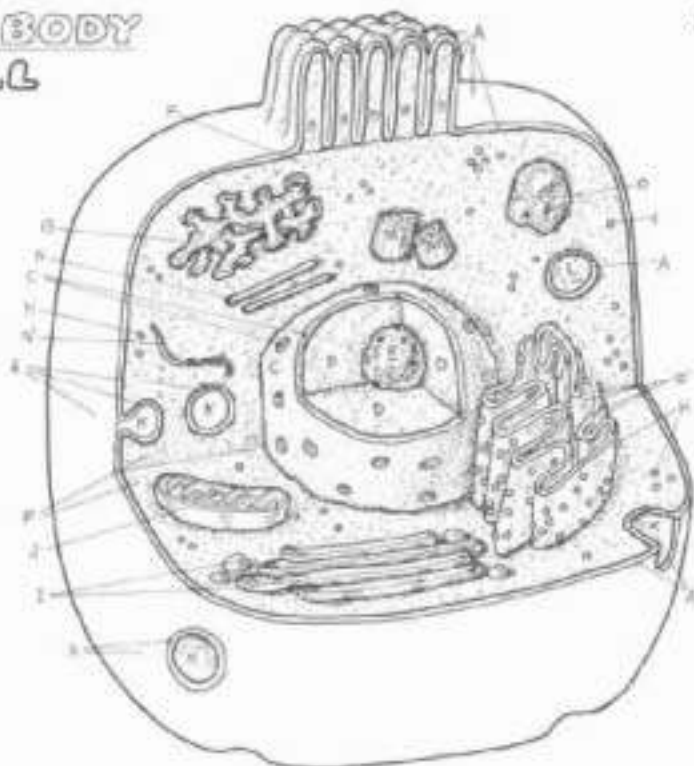
**ORGANELLES:**  
**CELL MEMBRANE,**  
**MICROVILLI,**  
**NUCLEAR MEMBRANE,**  
**NUCLEOPLASM,**  
**NUCLEOLUS,**  
**CYTOPLASM-**  
**ENDOPLASMIC RETICULUM**  
**SMOOTH, ROUGH,**  
**TRIBOSOME,**  
**GOLGI COMPLEX,**  
**MITOCHONDRION,**  
**VACUOLE / PINOCYTOTIC**  
**VESSICLE,**  
**LYSOSOME,**  
**CENTRIOLE,**  
**MICROTUBULE,**  
**MICROFILAMENT,**  
**CELL INCLUSION.**

The cell is the basic structural and functional unit of all living things. Living things are characterized by the ability to reproduce and grow, metabolize (transformation or production/consumption of energy), and adapt to limited changes in their internal and external environment. Body structure lacking these characteristics, such as connective tissue fibers, is not considered to be "alive." Body structure more complex than a cell consists of a collection of cells and their products.

The activities of cells constitute the life process, and include ingestion, assimilation, and digestion of nutrients, and excretion of the residue; respiration; synthesis and degradation of materials; movement; and excitability or response to stimuli. The impairment or cessation of these activities in normal cells, whether caused by trauma, infection, tumors, degeneration, or congenital defects, is the basis of a disordered or disease process.

The chemical composition of a cell is generally about 15% protein, 3% lipids, 1% carbohydrates, 1% nucleic acids and minerals, and 80% water (by volume). These compounds are integrated together into organelles, the working components of the cell. The basic function of cells is to produce protein, the structure of which is determined by DNA. The manifestation of this activity is the characteristic function of the cell (e.g., formation, repair, and breakdown of structure, secretion, absorption, contraction, conduction of electrochemical impulses, and so on).

**Cell membrane:** the limiting membrane of the cell, retains internal structure, permits excretion and importation of materials. Composed primarily of lipid and protein, and a smaller amount of carbohydrate.



**Microvilli:** finger-like extensions of the cell membrane covering the free surface of certain epithelial cells; they increase the surface area of the cell, enhancing secretion/absorption.

**Nuclear membrane:** porous membrane of similar construction to the cell membrane; the limiting membrane of the nucleus, separating it from the cytoplasm; regulates passage of molecules.

**Nucleoplasm:** the ground substance of the nucleus, containing the chromatin or thin threads of genetic material (DNA and related protein). During cell division, the chromatin transforms into chromosomes.

**Nucleolus:** a mass of largely RNA (and some DNA and protein) in the nucleus producing units of RNA which combine in the cytoplasm to form ribosomes.

**Cytoplasm:** the ground substance of the cell less the nucleus. Contains organelles and inclusions listed below.

**Smooth/rough endoplasmic reticulum (ER):** membrane-lined tubules to which ribosomes may be attached (rough ER, flattened tubules) or not (smooth ER, rounded tubules). Rough ER is concerned with transport of protein; synthesized at the ribosomes. Smooth ER synthesizes complex molecules called steroids in some cells; stores calcium ions in muscle; breaks down toxins in liver.

**Ribosome:** the site of protein synthesis where amino acids are strung in sequence as directed by messenger RNA from the nucleus.

**Golgi complex:** flattened membrane-lined sacs which bud off small vesicles from the edges; collect secretory products and package them for export or cell use.

**Mitochondrion:** membranous, oblong structure in which the inner membrane is convoluted like a maze. Energy for cell operations is generated here through a complex series of reactions between oxygen and products of digestion.

**Vacuoles/pinocytotic vesicles:** membrane-lined containers which can merge with one another or other membrane-lined structures, such as the cell membrane. They function as transport vehicles.

**Lysosome:** membrane-lined container of enzymes with great capacity to break down structure, especially ingested foreign substances.

**Centriole:** bundles of microtubules in the shape of a short barrel; usually seen paired, perpendicular to one another. They give rise to spindles used by migrating chromosomes during cell division.

**Microtubule:** microtubules are formed of protein and provide structural support for the cell.

**Microfilament:** microfilaments are support structures formed of protein different from that of microtubules. In skeletal muscle, the proteins actin and myosin are examples of thin and thick microfilaments.

**Cell inclusion:** aggregation of material within the cell that is not a functional part (organelle) of the cell, e.g., glycogen, fat, and so on.



# I. ORGANIZATION OF THE BODY

## CELL DIVISION / MITOSIS

Do: Use the colors you used on Plate 3 for cell membrane, nuclear membrane, nucleolus, and centriole for these sites on this plate, even though the previous letter labels may be different. Use contrasting colors for E-F and F-F, and gray for D-D to distinguish the sister from those with the contrasting colors. (1) Begin with the cell in interphase, reading the related text and completing each cell before

going on to the next. (2) Color gray the name of each stage and its appropriate arrow of progression. Note that in interphase, the chromatin material within the nuclear membrane is in a thread-like state; color over the entire area with the appropriate color. Note that the starting chromatin (D\* in interphase) is colored differently in the daughter cells (E, F); it is the same chromatin.

- CELL MEMBRANE
- NUCLEAR MEMBRANE
- NUCLEOLUS
- CHROMATIN-/CHROMOSOME
- CHROMATID-/CHROMOSOME
- CHROMATIN
- CHROMATID-/CHROMOSOME
- CHROMATIN
- CENTROMERE
- CENTRIOLE
- ASTER
- SPINDLE

The ability to reproduce its kind is a characteristic of living things. Cells reproduce in a process of duplication and division called mitosis. Epithelial and connective cells reproduce frequently, mature muscle cells not so frequently, mature nerve cells rarely if at all. Overactive mitoses may result in the formation of an encapsulated tumor, uncontrolled mitoses, associated with invasiveness and metastases, is called cancer.

As the main cellular changes during mitosis occur in the nucleus and surrounding area, only these parts of the cell are illustrated here. We are showing here how the nuclear chromatin (diffuse network of DNA and related protein), once duplicated, transforms into 46 chromosomes which divide into paired subunits (32 chromatids), and how those chromatids separate and move into opposite ends of the dividing cell, forming the 46 chromosomes of each of the newly formed daughter cells. For clarity, we show only 4 pairs of chromatids and chromosomes. The phases of the observed nuclear changes during mitosis are:

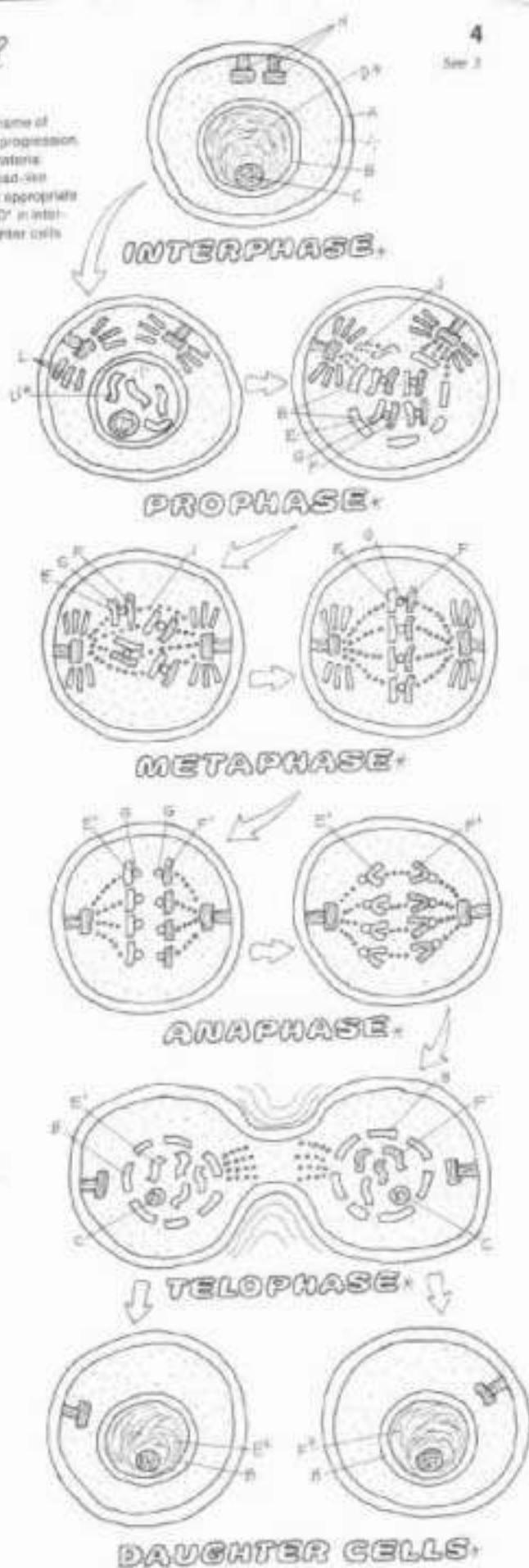
**Interphase:** the longest period of the reproductive cycle, the phase between successive divisions. Duplication of DNA (in chromatin) occurs during this phase. The dispersed chromatin (D\*) here is a network of fine fibrils, not visible as discrete entities in the nucleoplasm. The cell membrane, nucleus, and nucleolus are intact. The centrioles are paired and adjacent to one another at one pole of the cell.

**Prophase:** the dispersed chromatin (D\*) thickens, shortens, and coils to form condensed chromatin or chromosomes (D\*). Each chromosome consists of 2 chromatids (E and F) connected by a centromere (G). Each chromatid has the equivalent amount of DNA of a chromosome. In the latter part of this phase, the nuclear membrane breaks up and dissolves, as does the nucleolus. The centrioles, having duplicated during interphase, separate, each pair going to opposite poles of the cell. They project microtubules called asters.

**Metaphase:** strands of spindle fibers project across the cell center from paired centrioles. The chromatids attach to the spindle fibers at the centromere, and line up in the center, half (46) on one side, half (46) on the other.

**Anaphase:** the centromeres divide, each daughter centromere attached to one chromatid. Each centromere is drawn to the ipsilateral pole of the cell, along the track of the spindle fiber, and taking its chromatid with it. The separated chromatids now constitute chromosomes. Anaphase ends when the daughter chromosomes arrive at their respective poles (46 on each side).

**Telophase:** here the cell pinches off in the center, forming 2 daughter cells, each identical to the mother cell. The cytoplasm and organelles had duplicated earlier and are segregated each into their respective newly-forming cells. As the nucleus is reconstituted, and the nuclear membrane and nucleolus reappear in each new cell, the chromosomes fade into dispersed chromatin and the centromere disappears. Complete cleavage of the parent cell into daughter cells terminates the mitotic process. Each daughter cell enters interphase to start the process anew. The process of cell division serves to increase cell numbers, not change cellular content.



# I. ORGANIZATION OF THE BODY

## TISSUES: EPITHELIUM

CA: Use very light colors throughout. (1) Color the arrows pointing to the location of the epithelial tissues in the body organs.

There are four basic tissues of the body: epithelial, connective, muscle, and nervous. Epithelial tissues (epithelium) form the body's surface (skin), the surfaces of the body's cavities and their contained viscera, glands, and all tubular organs, e.g., ducts and vessels. Neuroepithelia convey sensations. Epithelia are arranged into single (simple) or several (stratified) layers; their cells are bound together by specialized fibers and substances (e.g., the basement membrane). Epithelial tissues are generally sensitive but avascular, and receive their nutrition by diffusion.

### SIMPLE EPITHELIUM

Surface tissue functioning in filtration, diffusion, secretion, and absorption.

#### SQUAMOUS

Simple squamous epithelia line the heart cavities and the internal surfaces of all blood and lymph vessels (endothelium), the air cells of the lung, filtration capsules and thin tubules in the kidney, and the major body cavities (mesothelium). Rapid diffusion of gases in solution are characteristic activities in these cells.

#### CUBOIDAL

Simple cuboidal epithelia are generally secretory cells, and make up glands throughout the body, tubules of the kidney, terminal bronchioles of the lungs, and ducts of the reproductive tracts.

#### COLUMNAR

Simple columnar epithelia line the gastrointestinal tract and are concerned with secretion and absorption. Their free (apical) surface may be covered with finger-like projections of cell membrane called microvilli, increasing the cell's surface area for secretion/absorption.

#### PSEUDOSTRATIFIED COLUMNAR

This tissue consists of simple columnar cells bunched together with irregularly placed nuclei giving the appearance of multiple cell layers. However, each of the cells is attached to the basement membrane. This tissue lines ducts of the reproductive tracts and air conduction pathways of the respiratory tract. They often exhibit cilia on their free surfaces and contain unicellular goblet-shaped (secretory) cells. The cilia collectively move surface material by virtue of undulating power strokes.

### STRATIFIED EPITHELIUM

Stratified epithelia are generally resistant to damage by wear and tear because of ready replacement of cells. Passive diffusion through these layers is slow but not impossible.

#### STRATIFIED SQUAMOUS

These layers of cells line the skin, oral cavity, pharynx, vocal folds, esophagus, vagina, and anus. The basal cells are columnar and germinal. The outermost layers of skin epithelia are fibrous-like, flat, desiccated, non-nucleated cells containing keratin (a scleroprotein).

#### TRANSITIONAL

Multiple layers of cells lining the urinary tract. In the empty (contracted) bladder, the fibromuscular layer is contracted due to resting tension of muscle cells, and the surface layer of rounded cells is closely concentrated, creating a bumpy surface. With distension of the bladder, all the cells stretch out to form a smooth, thin surface. The bladder can store volumes of urine up to 1000 milliliters or so.

### GLANDULAR EPITHELIUM

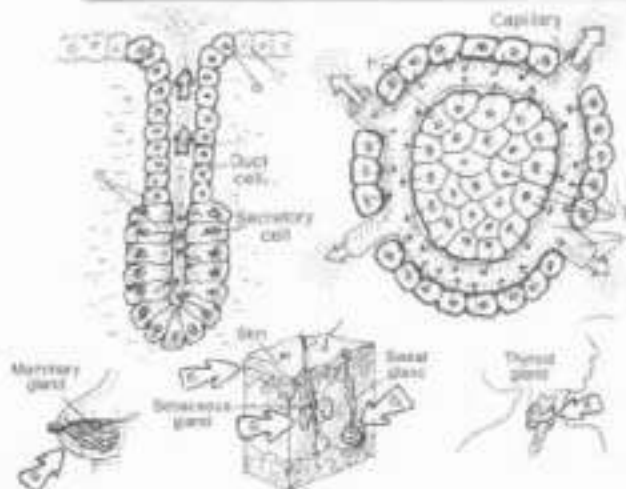
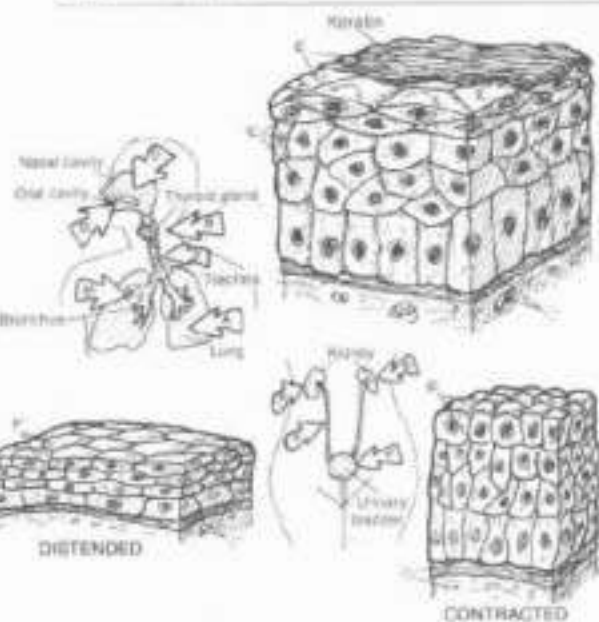
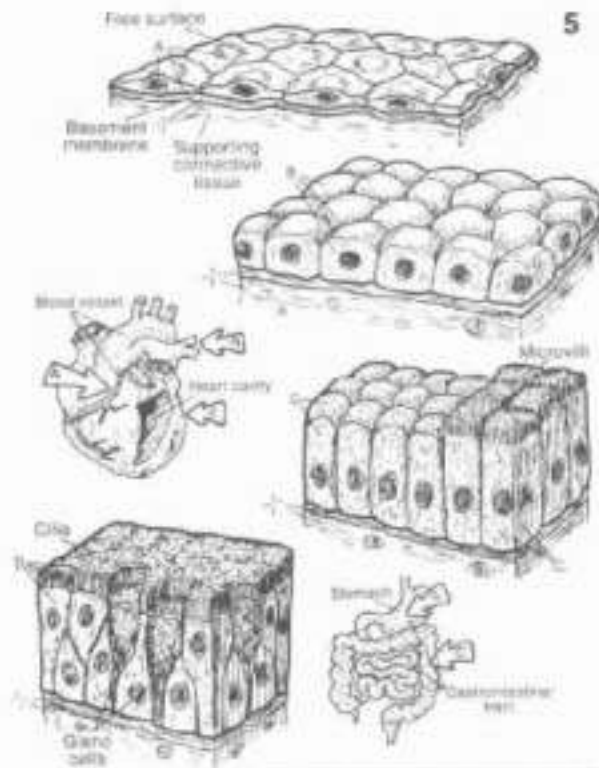
Glandular cells produce and secrete/excrete materials of varying composition, e.g., sweat, milk, sebum, cerumen, hormones, enzymes, and so on. Specialized contractile epithelial cells (myoepithelia) encourage discharge of the glandular material.

#### EXOCRINE

Exocrine glands (e.g., sweat, sebaceous, pancreatic, mammary, and so on) arise as outpocketings of epithelial lining tissue, retain a duct to the free surface of the cavity or skin, and excrete/secret some substance. Secretory portions may have one of several shapes (tubular, coiled, alveolar) connected to one or more ducts.

#### ENDOCRINE

Endocrine glands arise as epithelial outgrowths but lose their connections to the surface during development. They are intimately associated with a donor capillary network and secrete their products into them. See Plate 128 for examples of these glands.





# I. ORGANIZATION OF THE BODY

## TISSUES: FIBROUS CONNECTIVE TISSUES

CH. Use yellow for C and C', and red 1. (1) Begin with the illustration at middle left, and the related titles (A through K). The titles and borders of the microscopic sections of dense regular/irregular c.t. (P, P') receive the color of collagen (F) as that is the dominant structure in both tissues. (2) Do not color the matrix.

The connective tissues (c.t.) connect, bind, and support body structure. They consist of variable numbers of cells, fibers, and ground substance (fluid, viscous sol/gel, or mineralized). At the microscopic level (here illustrated at about 500 x magnification), connective tissues range from blood (cells/fluid), through the fibrous tissues (cells/fibers/variable matrix) to the more stiff supporting tissues (cells/fibers/dense matrix) of cartilage and mineralized bone. Connective tissue can be seen at visible levels of body organization as well, in fascial layers of the body wall, tendons, ligaments, bone, and so on. This plate introduces the fibrous connective tissues (c.t. proper).

### CELLS:

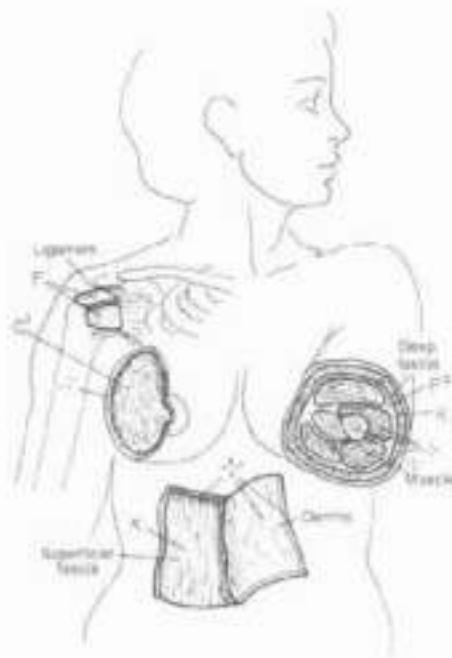
FIBROBLAST.  
MACROPHAGE.  
FAT CELL.  
PLASMA CELL.  
MAST CELL.

### FIBERS:

COLLAGEN.  
ELASTIC.  
RETICULAR.

MATRIX, GROUND  
SUBSTANCE.

CAPILLARY.



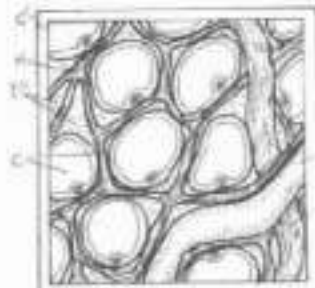
### LOOSE, AREOLAR C.T.



Loose, areolar connective tissue is characterized by many cells, a loose, irregular arrangement of fibers, and a moderately viscous fluid matrix. Fibroblasts secrete the fibers and ground substance of this tissue. Mobile macrophages engulf cell debris, foreign matter, and microorganisms. Fat cells, storing lipids, may be seen in small numbers or large (adipose tissue). Plasma cells secrete antibodies in response to infection. Mast cells contain heparin and other secretory products, some of which initiate allergic reactions when released. Numerous other cells may transit

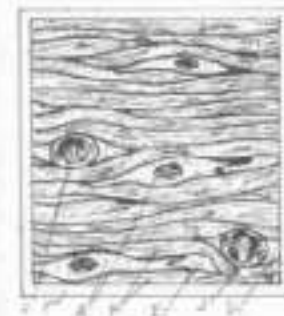
the loose fibrous tissues, including white blood cells (leukocytes). Collagen (linkage of protein exhibiting great tensile strength) and elastic fibers (trace of the protein elastin) are the fibrous support elements in this tissue. Reticular tissue is a smaller form of collagen, forming supporting networks around cell groups of the blood-forming tissues, the lymphoid tissues, and adipose tissue. The matrix (consisting largely of water with glycoproteins and glycosaminoglycans in solution) is the intercellular ground substance in which all of the above function; it is fluid-like in the fibrous tissue. Numerous capillaries roam throughout this tissue. Loose connective tissue found deep to the skin is called superficial fascia, subcutaneous tissue, or hypodermis. It is found deep to the epithelial tissues of mucous and serous membranes of hollow organs.

### ADIPOSE C.T.



Aggregations of fat cells, supported by reticular and collagenous fibers, and closely associated with both blood and lymph capillaries, constitute adipose tissue. The storage/release of fat in/from adipose tissue is regulated by hormones (including nutritional factors) and nervous stimuli. It is a source of fuel, an insulator, mechanical padding, and stores fat-soluble vitamins. Adipose tissue is located primarily in the superficial fasciae (largely breast, buttock, anterior abdominal wall, arm, and thigh), yellow marrow, and the surface of serous membranes.

### DENSE REGULAR C.T.



Dense, parallel arranged, masses of collagenous/elastic fibers form ligaments and tendons that are powerfully resistant to axially loaded tension forces, yet permitting some stretch. Tendons/ligaments contain few cells, largely fibroblasts. Elastic, dense regular ligaments are found in the posterior neck and between vertebrae; the tendocalcaneus is the largest elastic structure (tendon or ligament) in the body, storing energy used in gait.

Dense, irregularly arranged masses of interwoven collagenous (and some elastic) fibers in a viscous matrix form capsules of joints, envelop muscle tissue (deep fasciae), encapsulate certain visceral organs (liver, spleen, and others) and largely make up the dermis of the skin. It is impact resistant (bearing stress omnidirectionally), contains few cells, and is minimally vascularized.

### DENSE IRREGULAR C.T.



# 1. ORGANIZATION OF THE BODY TISSUES: SUPPORTING CONNECTIVE TISSUES

DN: Use the same colors as used on the previous page for collagen (C) and elastic (E) fibers. Use a light tan or yellow for F and red for L. Before coloring the bone section.

## CARTILAGE<sup>o</sup>

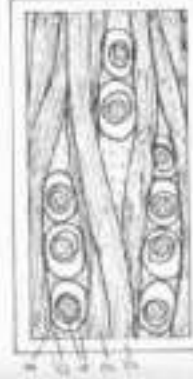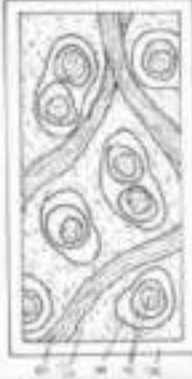### CHONDROCYTE<sup>A</sup>

### LACUNA<sup>A</sup>

### MATRIX<sup>o</sup>

### COLLAGEN FIBER<sup>B</sup>

### ELASTIC FIBER<sup>E</sup>



## BONE<sup>F</sup>

### PERIOSTEUM<sup>F</sup>

### COMPACT BONE<sup>o</sup>

### HAVERSIAN SYS.<sup>o</sup>

### HAV. CANAL<sup>H</sup>

### LAMELLAE<sup>C</sup>

### OSTEOCYTE<sup>o</sup>

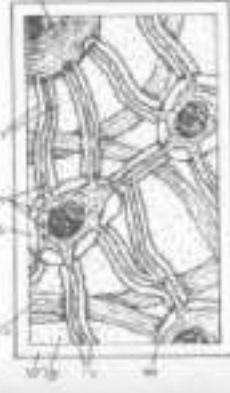### LACUNA<sup>o</sup>

### CANALICULI<sup>L</sup>

### VOLWMANN CANAL<sup>V</sup>

### BLOOD VESSEL<sup>B</sup>

### SPONGY BONE<sup>M</sup>



The supporting connective tissues consist of cartilage and/or bone. Microscopic sections of cartilage tissue reveal cells (chondrocytes), in small cavities (lacunae) surrounded by a specialized, hard but flexible matrix consisting of water electrochemically bound to proteoglycans and very fine collagen fibers. Cartilage is avascular; it receives its nutrition by diffusion. It generally does not repair well after injury but does replace itself with age, as on joint surfaces.

Bone is unique for its mineralized matrix (average bone is 65% inorganic, 35% organic tissue by weight). Bone forms the skeleton of the body; it is a reservoir of calcium; it acts as an anchor for muscles, tendons, and ligaments; it harbors many minute viscera, including the central nervous system; it assists in the mechanism of respiration, and is a center of blood-forming (hemopoietic) activity and fat storage.

## HYALINE CARTILAGE<sup>A</sup>

Hyaline cartilage is a flexible, avascular, insensitive, compressible cartilage, characterized by tiny pores. Its major significance is covering bone ends at synovial joints (articular cartilage). Joint movement enhances nutrition of the 1-3 mm thick articular cartilage, by pushing synovial fluid through the pores. Hyaline cartilage also supports the nose, contributes to the nasal septum, and is the main structural support of the larynx and lower respiratory tract. It forms the cartilage model for some bones in embryonic/ fetal development; it is then a part of the fibromedullary framework (cubiti) in the healing process of fractured bone. Non-articular cartilage is generally encased by perichondrium, a vascular fibrous tissue.

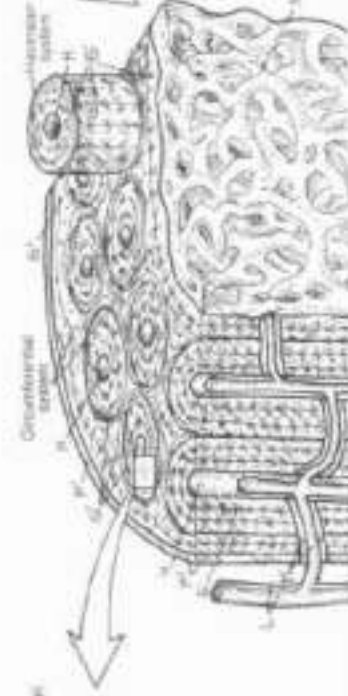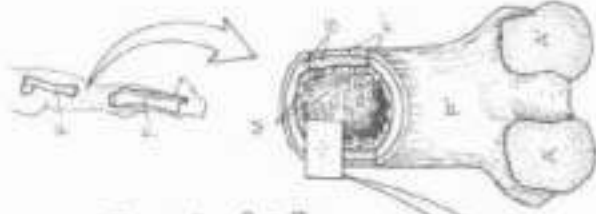
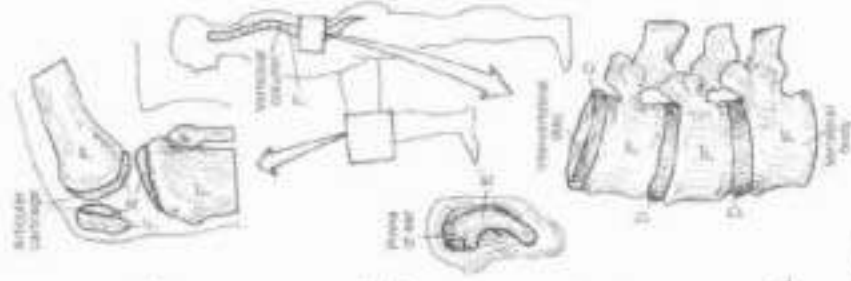
## ELASTIC CARTILAGE<sup>C</sup>

Elastic cartilage is essentially hyaline cartilage with elastic fibers and a slightly different type of collagen. It supports the external ear and contributes to the support of the larynx (epiglottis). It is remarkably flexible, lend it on your external ear.

## FIBROCARTILAGE<sup>D</sup>

Fibrocartilage is dense fibrous tissue interspersed with chondrocytes in a reduced amount of intercellular matrix. It is found in intervertebral discs, the sacrotailac joint, pubic symphysis, and in several sites of ligamentous attachment to bone. Fibrocartilage enhances resistance to tensile and impact forces.

Microscopic sections of bone consist of osteocytes in lacunae, supported by collagen fibers in a mineralized (calcium hydroxyapatite) matrix. Other bone cells (not shown) include bone forming cells (osteoprogenitor cells, osteoblasts and bone-destroying cells (osteoclasts). Compact bone is the outer impact resistant, weight-bearing shell of bone. It is surrounded on its outer surface by a fibrous, vascular, cellular periosteum. The matrix of compact bone occurs in two patterns: concentric layers (lamellae) with a central canal (Haversian system/canal) arranged in columns, and layers between and around Haversian systems (interstitial systems). The canals are interconnected by Volkmann canals, both conduct blood vessels. The bone internal to compact bone is trabecular, engendered by irregular and interlocking bony beams (spongy bone). These beams are constantly remodeling in response to the stress imposed on them. Unlike cartilage, bone is well-vascularized, bone cells reach for vascular nutrition by multiple long cellular processes threading through small canals (canaliculi), giving the cells an insect-like appearance.





# I. ORGANIZATION OF THE BODY

## TISSUES: ENDOCHONDRAL OSSIFICATION

Use the same colors as used on the previous plate for hyaline cartilage (A), periosteal bone (B) which was compact bone on Plate 7 and endochondral bone (C) which was spongy bone. Use red for D. Complete each stage before going on to the next. Do not color the perichondrium which appears adjacent to periosteal bone in step 3 and continues to the end. Color the small shapes (E) that appear in the epiphyses and, to a lesser extent, the diaphyseal rivets 5-6. They represent spongy (cancellous) bone of endochondral origin.

Bone development occurs by intramembranous and/or endochondral ossification. Here we show longitudinal sections of developing long bone, demonstrating both forms of ossification, but emphasizing endochondral bone growth.

The endochondral process begins at about 5 weeks of post-fertilization age with formation of cartilage models (bone prototypes) from embryonic connective tissue. Subsequently (over the next 18-25 years), the cartilage is largely replaced by bone. The rate and duration of this process largely determines a person's standing height. Intramembranous bone development begins in embryonic connective tissue (membrane) and does not involve replacement of cartilage. The flat cranial bones, the clavicle, and the bone collar surrounding the shaft of cartilage models develop in this fashion.

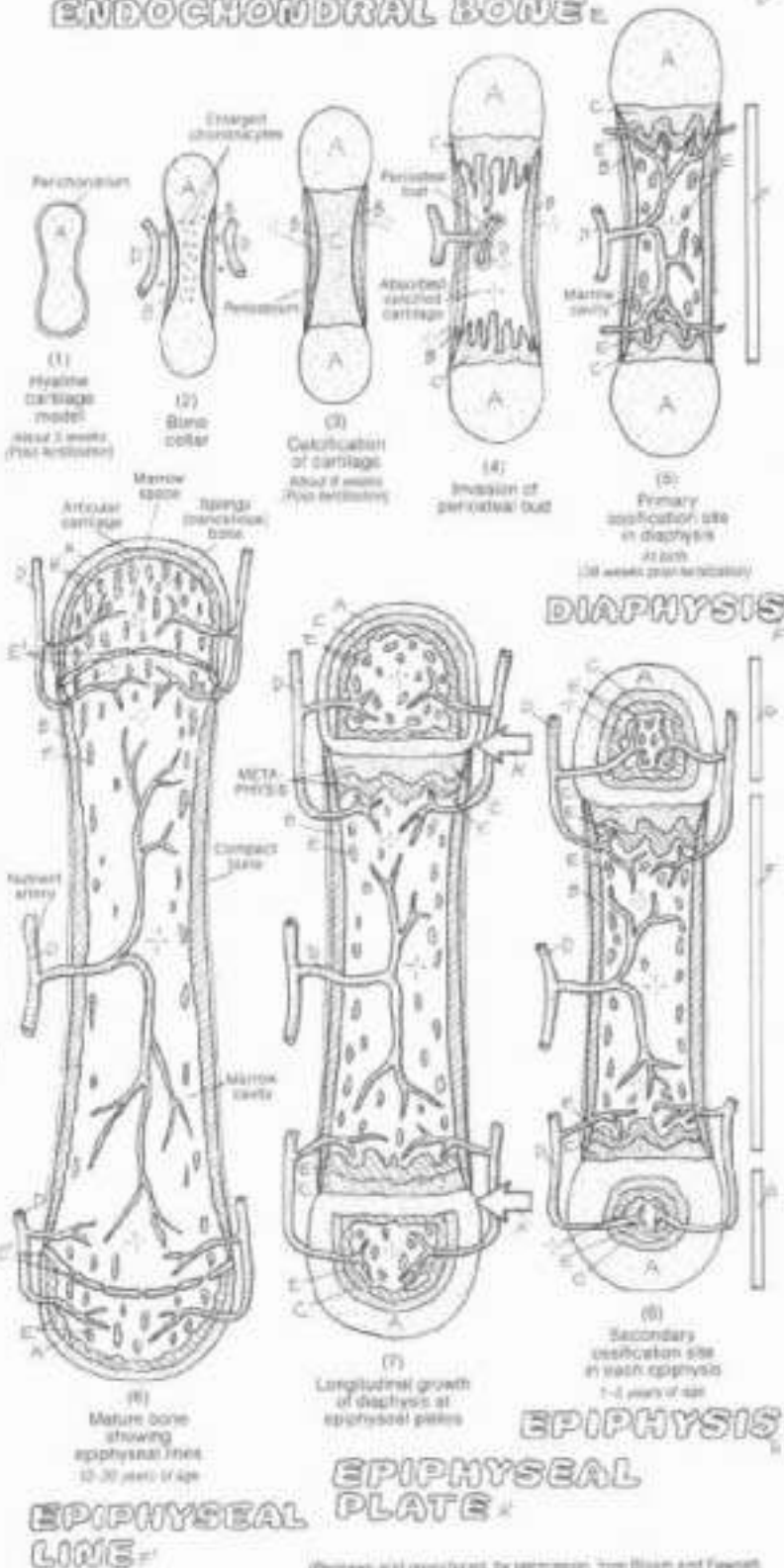
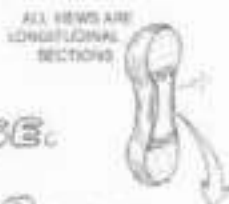Endochondral ossification begins with a hyaline cartilage model (1). As the cartilage structure grows, its central part dehydrates. The cartilage cells there begin to degenerate: enlarge, die and calcify (2). Concurrently, blood vessels bring bone-forming cells to the waist of the cartilage model and a collar of bone is formed around the cartilage shaft (2) within the membranous perichondrium (intramembranous ossification). This vascular, cellular, fibrous membrane around the bone collar is now called periosteum. The new bone collar (periosteal bone) becomes a supporting tubular shaft for the cartilage model, with a core of degenerating, calcifying cartilage (3).

Blood vessels from the fibrous periosteum penetrate the bone collar, enter the cartilage model (periosteal bud), and proliferate, conducting periosteal osteoblasts into the cartilage model (4). Starting at about 8 weeks post-fertilization, these bone-forming cells line up along penicillae of calcified cartilage at the extremities of the shaft (diaphysis) and secrete new bone (5). The calcified cartilage degenerates and is absorbed into the blood. Endochondral bone has now replaced the cartilage. The two sites of this activity are called primary centers of ossification (5). The direction of growth at these sites is toward the ends of the developing bone. The calcified cartilage and some endochondral bone of the diaphysis is subsequently absorbed, forming the medullary or marrow cavity (5). This cavity of the developing tubular bone shaft becomes filled with gelatinous red marrow in the fetus. Productive primary (diaphyseal) centers of ossification are well established at birth.

Beginning in the first few years after birth, secondary centers of ossification begin at the ends or epiphyses as blood vessels penetrate the cartilage there (6). The healthy cartilage between the epiphyseal and diaphyseal centers of ossification becomes the epiphyseal plate (7). It is the growth of this cartilage that is responsible for bone lengthening. It is the gradual replacement of this cartilage by bone cells in the metaphysis (7) that thins this plate and ultimately permits fusion of the epiphyseal and diaphyseal ossification centers (8), ending longitudinal bone growth (at 12-20 years of age). Dense areas of bone at the fusion site may remain into maturity (epiphyseal line). Epiphyseal bone is less structured (irregular beams) than that of the diaphysis (organized columns or osteons), and in maturity is called spongy or cancellous bone (recall Plate 7).

Intramembranous ossification of the diaphyseal shaft (bone collar to compact bone) is responsible for the widening of developing long bone. The ossification process is regulated by growth hormones (from the pituitary gland) and the sex hormones.

### HYALINE CARTILAGE, PERIOSTEAL BONE, CALCIFIED CARTILAGE, BLOOD VESSEL, ENDOCHONDRAL BONE.



Photos and reproductions, by permission, from Dixon and Fawcett, *J. Textbook of Histology*, 19th ed., W.B. Saunders Co., Phila., PA, 1973.

# I. ORGANIZATION OF THE BODY

## TISSUES: MUSCLE

Muscle tissue, one of the four basic tissue types of the body, consists of muscle cells ("fibers") and their fibrous connective tissue coverings. There are three kinds of muscle tissues: skeletal, cardiac, and smooth. Muscle tissue shortens (contracts) in response to nerve, nerve-like, or hormonal stimulation. Depending on their attachments, skeletal muscles move bones at joints, constrict cavities, and move the skin; cardiac muscle compresses a heart cavity or orchestrates the sequence of cardiac muscle contraction; and smooth muscle moves the contents of cavities by rhythmic contractions, constricts vessels they surround, and moves hairs/closets pores of the skin. The surrounding connective tissue transfers the force of contraction from cell to cell, and supports the muscle fibers and the many blood capillaries and nerves that supply them.

### SKELETAL/STRIATED MUSCLE, CELL: SARCOLEMMA

Skeletal muscle cells are long, striated, and multi-nucleated, formed of myofibrils, mitochondria, and other organelles within the cytoplasm (sarcolemma). Each cell is enveloped in cell membrane called sarcolemma. Collections of muscle cells make up the belly of a muscle. The highly vascularized skeletal muscles contribute greatly to the size and shape of the body. Skeletal muscles attach to bones or other muscles at their tendinous ends. Between bony attachments, muscles cross one or more joints, moving them. Muscles always pull... they never push. Skeletal muscle contractions consist of rapid, brief shortenings, often generating considerable force. Each contracting cell shortens maximally. Three kinds of skeletal muscle fibers are recognized: red (small, dark, long acting, slow contracting, postural muscle fibers with oxygen-rich myoglobin and many mitochondria), white (relatively large, pale, anaerobic, short acting, fast contracting muscle fibers with few mitochondria), and intermediate fibers. With exercise, fast fibers can convert to slow; slow fibers can convert to fast. Contraction of skeletal muscle requires nerves (innervation). Without a nerve supply (denervation), skeletal muscle cells cease to shorten; without reinnervation, the cells will die. A denervated portion of muscle loses its tone and becomes flaccid. In time, the entire muscle will become smaller (atrophy). Muscle contraction is generally under voluntary control, but the brain involuntarily maintains a degree of contraction among the body's skeletal muscles (muscle tone). After injury, skeletal muscle cells can regenerate from myoblasts with moderate functional significance; such regeneration may also occur in association with muscle cell hypertrophy in response to training/exercise.

### CARDIAC/STRIATED MUSCLE, CELL: INTERCALATED DISC

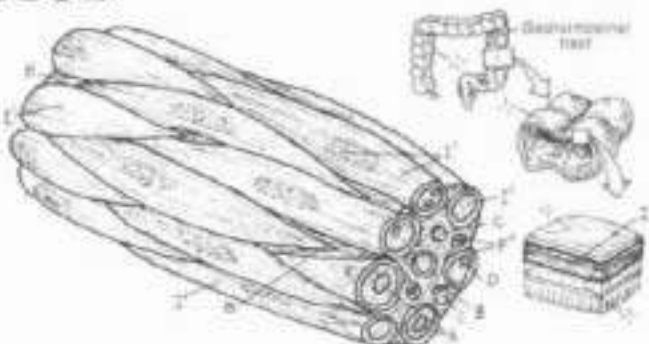
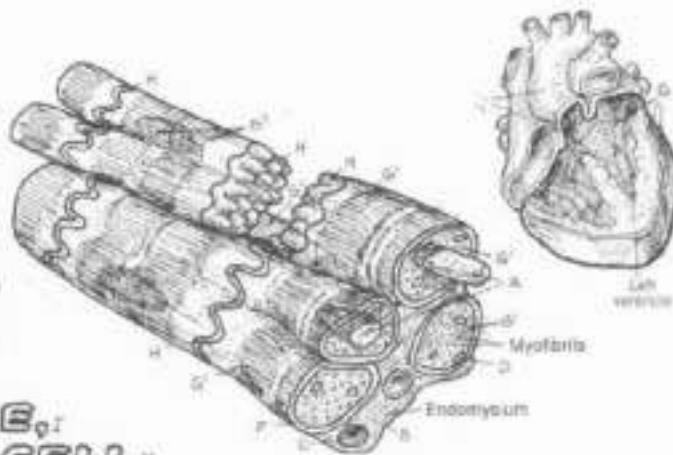
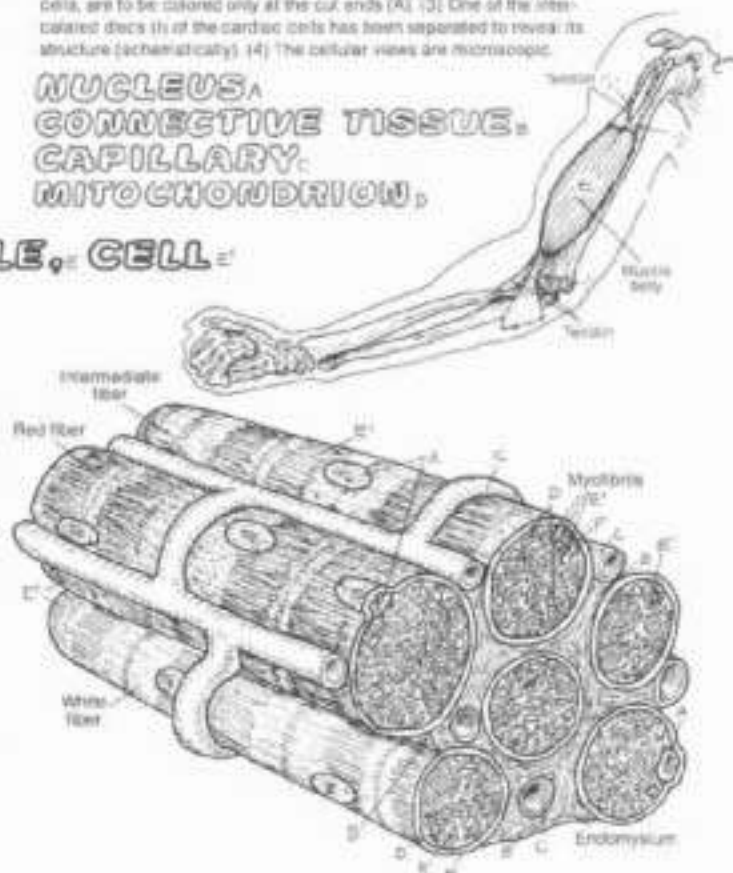
Cardiac muscle cells make up the heart muscle. They are branched, striated cells with one or two centrally located nuclei and a sarcolemma surrounding the sarcolemma. They are connected to one another by junctional complexes called intercalated discs. Their structure is similar to skeletal muscle, but less organized. Cardiac muscle is highly vascularized, its contractions are rhythmic, strong, and well regulated by a special set of impulse-conducting muscle cells, not nerves. Rates of contraction of cardiac muscle are mediated by the autonomic (visceral) nervous system, the nerves of which increase/decrease heart rate. Cardiac muscle is probably not capable of regeneration.

### VISCERAL/SMOOTH MUSCLE, CELL: PLASMALEMMA

Smooth muscle cells are long, tapered cells with centrally placed nuclei. Each cell is surrounded by a plasmalemma (cell membrane). These cells are smooth (non-striated). Myofibrils are not seen; the myofibrils intersect with one another in a pattern less organized than that seen in skeletal muscle. Smooth muscle cells occupy the walls of organs with cavities (viscera) and serve to propel the contents along the length of those cavities by slow, sustained, often powerful rhythmic contractions (consider menstrual or intestinal cramps). Smooth muscle cells, oriented perpendicular to the flow of tubular contents, act as gates (sphincters) in specific sites, regulating the flow, as in delaying the flow of urine. Well-vascularized, smooth muscle fibers contract in response to both autonomic nerves and hormones. They are also capable of spontaneous contraction. Regeneration of smooth muscle, to some extent, is possible after injury.

ON: Use red for C and your lighter colors for B, E, G, and I. (1) The sarcolemma (F), which covers each skeletal and cardiac muscle cell, is colored only at the cut ends. The plasmalemma (F'), which covers each smooth muscle cell, is colored only at the cut ends. (2) The nuclei of cardiac and smooth muscle cells, located deep within the cells, are to be colored only at the cut ends (A). (3) One of the intercalated discs (H) of the cardiac cells has been separated to reveal its structure (schematically). (4) The cellular views are microscopic.

NUCLEUS,  
CONNECTIVE TISSUE,  
CAPILLARY,  
MITOCHONDRION,



# I. ORGANIZATION OF THE BODY

## TISSUES: SKELETAL MUSCLE STRUCTURE

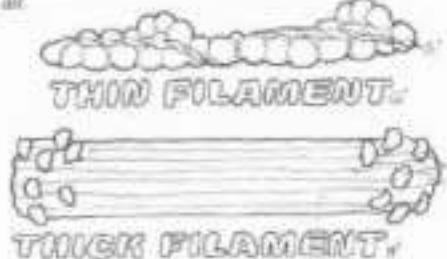
DN. Use the same colors used on Plate 3 for sarcolemma (A) and mitochondrion (D). Use the same color used on the skeletal muscle cell for the myofibril (E) here. Use light colors for G and J a dark color for H, and very dark colors for F and K. The cell nucleus is not shown here. (1) Begin with the drawing of the sarcolemma. (2) Color the parts of the muscle cell in the center illustration; note the presence of mitochondria (D) between the myofibrils. (3) Color the parts of the exposed (lowest) myofibril and the color-coded labels, bands, zones, note that the out end of this myofibril receives the color E, for identification purposes, and is part of the A band of the sarcomere adjacent to the one to be colored. (4) Color the relaxed and contracted sarcomere, the filaments, and the mechanism for contraction, noting the color relationship with the myofibril and its parts.

A part of a skeletal muscle cell is shown with the sarcolemma opened to reveal some cellular contents. The most visible of the contents are the myofibrils, the contractile units of the cell. They are enveloped by a flat tubular sarcoplasmic reticulum (SR) that, in part, regulates the distribution of calcium ions ( $Ca^{++}$ ) into the myofibrils. Inward tubular extensions of the sarcolemma, called the transverse tubule system (TTS), run transversely across the SR at the level of the Z lines of the myofibrils. The TTS, containing stores of sodium ions ( $Na^+$ ) and calcium ions ( $Ca^{++}$ ), conducts electrochemical reactions to the myofibrils from the sarcolemma. Mitochondria provide energy for the cell work.

The myofibrils consist of myofilaments: thick filaments (largely myosin) with heads that project outward as cross bridges, and thin filaments (largely actin) composed of two interwoven strands. These two filament types are arranged into contractile units each of which is called a sarcomere. Each myofibril consists of several, serially arranged sarcomeres. At the end of each sarcomere, the thin filaments are permanently attached to the Z line, which separates one sarcomere from the next. The relative arrangement of the thick and thin filaments in the sarcomere creates light (I, H) and dark (A) bands/zones and the M line, all of which contribute to the appearance of cross striations in skeletal (and cardiac) muscles.

Shortening of a myofibril occurs when the thin filaments slide toward the center (H zone), bringing the Z lines closer together in each sarcomere. The filaments do not shorten; the myosin filaments do not move. The close relationship of the TTS to the Z lines suggests that this site is the "trigger area" for induction of the sliding mechanism. This sliding motion is induced by cross bridges (heads of the immovable thick filaments) that are connected to the thin filaments. Activated by high energy bonds from ATP, the paddle-like cross bridges swing in concert toward the H zone, drawing the thin filaments with them. The sarcomere shortens as the opposing thin filaments meet or even overlap at the M line.

Occurring simultaneously in all or most of the myofibrils of a muscle cell, shortening of sarcomeres translates to a variable shortening of the resting length of the muscle cell. Repeated in hundreds of thousands of conditioned muscle cells of a professional athlete, the resultant contractile force can pull a baseball bat through an arc sufficient to send a hardball a hundred meters or more through the air.

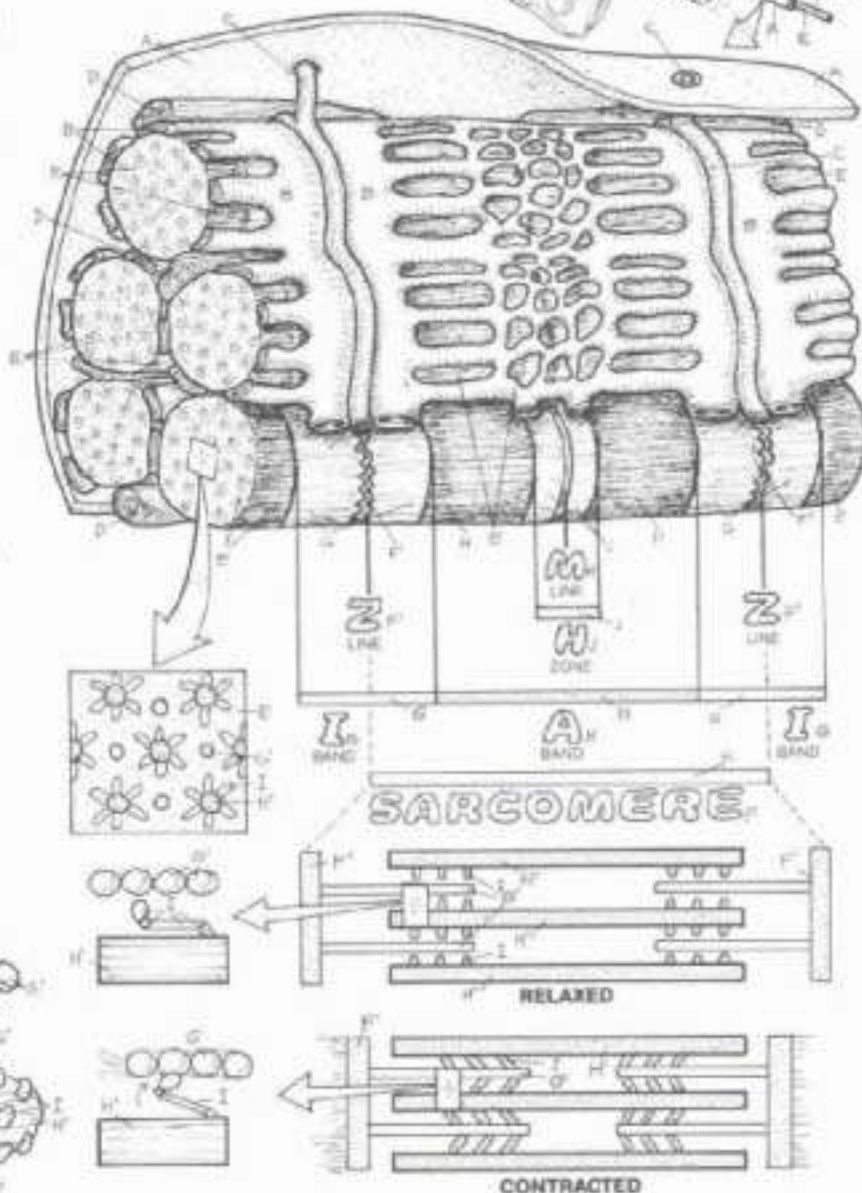


### SKELETAL MUSCLE CELL:

- SARCOLEMMMA
- SARCOPLASMIC RETICULUM
- TRANSVERSE TUBULE SYS.
- MITOCHONDRION

### MYOFIBRIL:

- SARCOMERE
- I BAND
- THIN FILAMENT (ACTIN)
- Z LINE
- A BAND
- THICK FILAMENT (MYOSIN)
- CROSS BRIDGE
- H ZONE
- M LINE



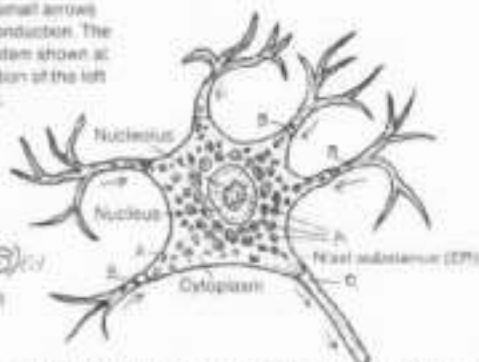


# I. ORGANIZATION OF THE BODY

## TISSUES: NERVOUS

OK Use a light color for A. Note the small arrows which indicate direction of impulse conduction. The neurons of the peripheral nervous system shown at lower left are illustrated in the orientation of the left upper limb, although highly magnified.

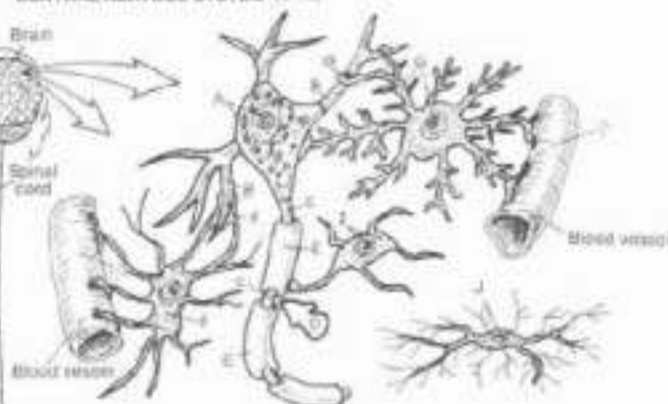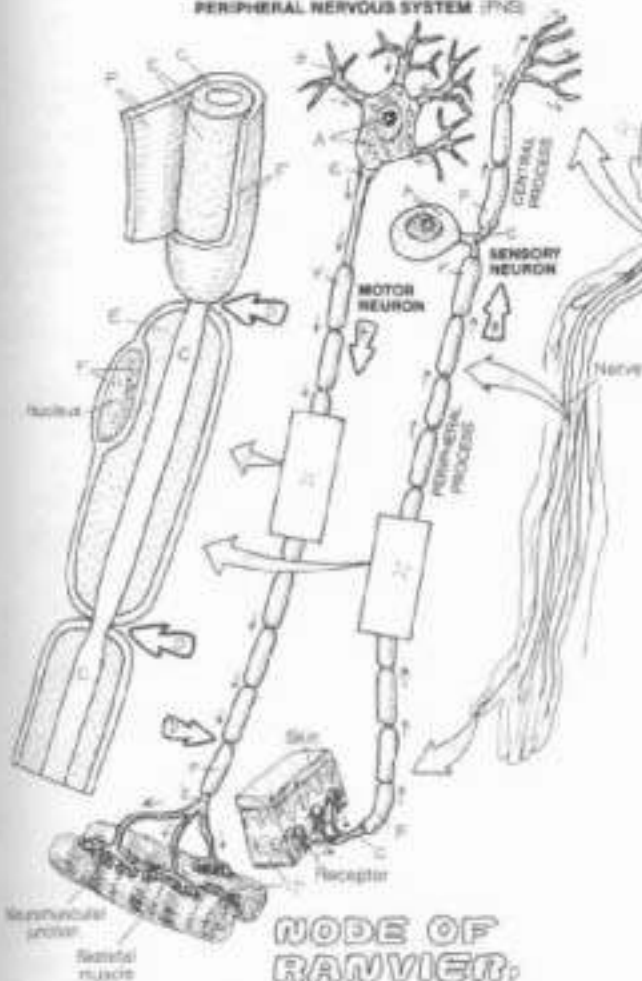
### NEURON- CELL BODY, PROCESSES, DENDRITE, AXON.



Nervous tissue consists of neurons (nerve cells) and neuroglia. Neurons generate and conduct electrochemical impulses by way of neuronal (cellular) processes. Neuroglia are the supporting, non-impulse-generating/conducting cells of the nervous system. The main, nucleus-bearing part of the neuron is the cell body. Its cytoplasm contains the usual cell organelles. Uniquely, the endoplasmic reticulum occurs in clusters called Nissl substance. Neurons do not undergo mitosis after birth, compromising their ability to regenerate after injury. Neuronal growth consists of migration and arborization of processes. Neurons are the impulse-conducting cells of the brain and spinal cord (central nervous system or CNS) and the spinal and cranial nerves (peripheral nervous system or PNS).

### PERIPHERAL NERVOUS SYSTEM (PNS)

### CENTRAL NERVOUS SYSTEM (CNS)



### NEUROGLIA.

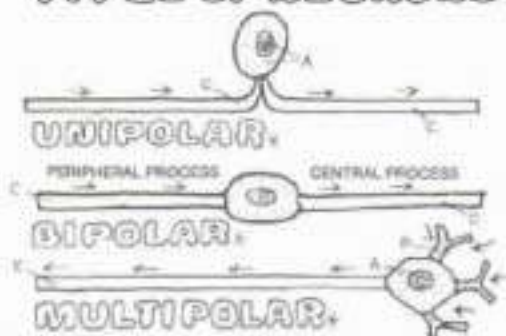
### PROTOPLASMIC ASTROCYTE, FIBROUS ASTROCYTE, OLIGODENDROCYTE, MICROGLIA.

Most axons are enveloped in one or more (up to 200) layers of an insulating phospholipid (myelin) that enhances impulse conduction rates. In the CNS (lower right), myelin is produced by oligodendrocytes; in the PNS (lower left), by Schwann cells. All axons of the PNS are ensheathed by the cell membranes of Schwann cells (neurilemma) but not necessarily myelin. The gaps between Schwann cells are nodes of Ranvier, making possible rapid node-to-node impulse conduction. Schwann cells make possible axonal regeneration in the PNS. Significant axonal regeneration in the CNS has not been observed.

Neuroglia exist in both the CNS and PNS (Schwann cells). Protoplasmic astrocytes occur primarily in gray matter (dendrites, cell bodies) of the CNS, fibrous astrocytes in the white matter (myelinated axons). Their processes attach to both neurons and blood vessels and may offer metabolic, nutritional and physical support. They may play a role in the blood brain barrier. Oligodendrocytes are smaller than astrocytes, have fewer processes, and are seen near neurons. Microglia are the small scavenger cells of the brain and spinal cord.

### AXON COVERINGS- MYELIN- SCHWANN CELL-

### TYPES OF NEURONS.





# 1. ORGANIZATION OF THE BODY

## INTEGRATION OF TISSUES

This page has one goal: to aid you in visually integrating the four basic issues into somatic (body wall) and visceral (cavity-containing organs) tissues. Concentrate on how the four tissues are arranged in each sample of body structure. Consider the general function of each issue in the overall function of the part/organ. There are an infinite number of functionally related variations in the way these four tissues form a discrete construction of the soma and viscera of the body.

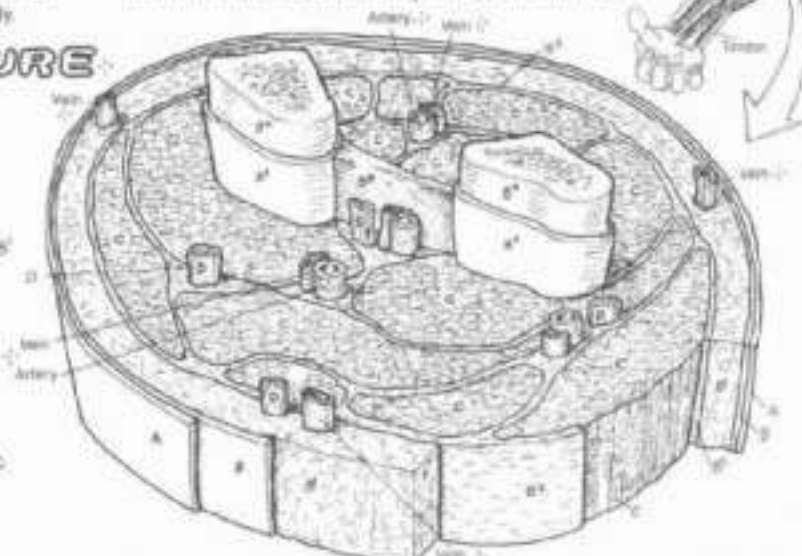
ON Use yellow for D and light, contrasting colors for A and B and a medium brown for C. The various vessels that are shown in these tissues—arteries and veins above, and arterioles, venules, capillaries, and lymph vessels below—are not to be colored, as they are made up of more than one basic tissue. Note that within deep fascia, arteries are generally paired with veins.

### SOMATIC STRUCTURE

- EPITHELIAL TISSUE.
- SKIN (OUTER LAYER).
- CONNECTIVE TISSUE.
- SKIN (DEEP LAYER).
- SUPERFICIAL FASCIA.
- DEEP FASCIA.
- LIGAMENT.
- BONE.
- PERIOSTEUM.
- MUSCLE TISSUE.
- SKELETAL MUSCLE.
- NERVOUS TISSUE.
- NERVE.

Somatic structure, making up the skin-covered musculoskeletal frame of the body, is concerned with stability, movement, and protection. Its construction reflects these functions. The outermost covering of the body wall everywhere is a protective keratinized stratified squamous epithelial tissue, constituting the outer layer of skin (epidermis). Other epithelial tissues in somatic structure are the inner layers of blood vessels, and the glands (not shown). Connective tissue layers of the body wall include the deep layer of skin (dermis), consisting of dense, irregular fibrous connective tissue, and the sub-adjacent, variously mobile, subcutaneous super-

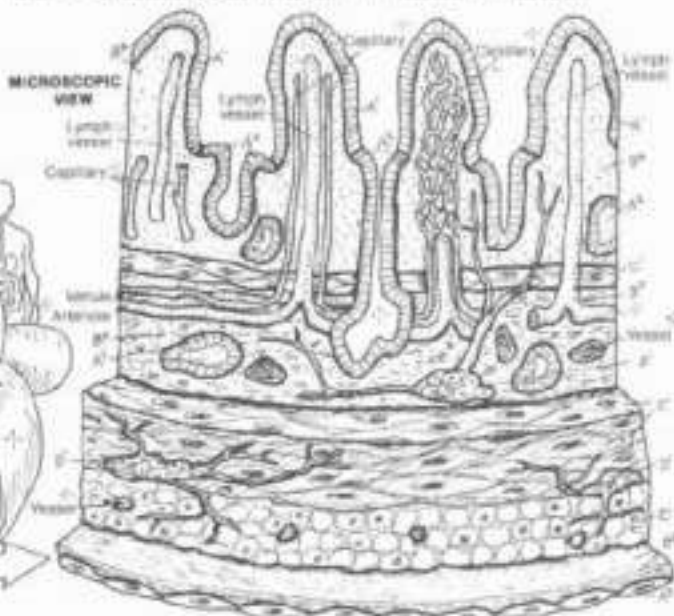
ficial fascia (loose connective and adipose tissues), containing cutaneous nerves, small vessels, and occasional large veins. Deep fascia, a more vascular, sensitive, dense, irregular fibrous tissue, ensheathes skeletal muscle (myofascial tissue) as well as the supporting nerves and vessels. Ligaments (dense regular connective tissue) bind bone to bone by way of periosteum (vascular, cellular, dense, irregular fibrous tissue). Skeletal muscles and their nerves are packaged in groups, separated by slippery septa of deep fascia securing neurovascular structure. The fibrous investments of skeletal muscle converge to form tendons of the muscle.



### VISCERAL STRUCTURE

- EPITHELIAL TISSUE.
- MUCOSAL LINING.
- GLAND.
- SEROSA (OUTER LAYER).
- CONNECTIVE TISSUE.
- LAMINA PROPRIA.
- SUBMUCOSA.
- SEROSA (INNER LAYER).
- MUSCLE TISSUE.
- SMOOTH MUSCLE.
- NERVE TISSUE.
- NERVE CELLS.

Visceral structure is generally concerned with absorbing, secreting, trapping and/or moving food, air, secretions, and/or waste in its cavities. Epithelial tissue is the innermost layer (mucosal lining) of the thin and plate visceral wall; it faces the lumen (cavity of the viscus); it is often a single layer of cells (esophagus, urinary tract, and reproductive tract excepted) and deals with the contents of the visceral cavity. Glands, unicellular or larger in the mucosa or submucosa, are epithelial, as are the inner layers of blood and lymph vessels. The mucosa includes a sub-epithelial layer of loose fibrous tissue (lamina propria), supporting mobile cells, glands, vessels and nerves. The deepest layer of the mucosa (when



present) is a thin smooth muscle layer moving finger-like projections (villi) of the mucosal surface. Deep to the mucosa is a dense fibrous tissue (submucosa), replete with large vessels and small nerves/nerve cells (intramural ganglia) supplying the mucosa. Deeper yet, two or three layers of smooth muscle (lunica muscularis), innervated by local nerve cells, move the visceral wall in peristaltic contractions. The outermost layer of the gastrointestinal tract is the slippery serosa: an outer secretory simple squamous epithelial layer and an inner supporting layer of light fibrous tissue.

# 11. SYSTEMS AND REGIONS

## SYSTEMS OF THE BODY 1

CA Use light colors on this and the next plate.

Color the entire skeleton (A); only the knee joint and shoulder joint show joint capsules (A'). Color the entire musculature (B) brown. Color all the vessels and heart (C); arteries and heart not veins blue. Color all lymphatic vessels (D); green. Color all the nerves, as well as the brain and spinal cord (E), yellow. Do not color the background of the rectangular insets representing the endocrine system (F). Choose a skin color for the integument system (G).

Collections of similar cells constitute tissues. The four basic tissues are integrated into body wall and visceral structures/organs. A system is a collection of organs and structures sharing a common function. Organs and structures of a single system occupy diverse regions within the body and are not necessarily grouped together.

### SKELETAL SYS.<sub>A</sub> ARTICULAR SYS.<sub>A'</sub>

The skeletal system consists of the skeleton of bones and their periosteum, and the ligaments which secure the bones at joints. By extension, this system could include the varied fasciae which ensheath the body wall/skeletal muscles and contribute to the body's structural stability. The articular system comprises the joints, both movable and fixed, and the related structures, including joint capsules, synovial membranes, and discs/menisci.

### MUSCULAR SYS.<sub>B</sub>

The muscular system includes the skeletal muscles which move the skeleton, the face, and other structures, and give form to the body; the cardiac muscle of the heart walls; and the smooth muscle of the walls of viscera and vessels, and in the skin.

### CARDIOVASCULAR SYS.<sub>C</sub>

The cardiovascular system consists of the 4-chambered heart, arteries conducting blood to the tissues, capillaries through which nutrients, gases, and molecular material pass to and from the tissue, and veins returning blood from the tissues to the heart. Broadly interpreted, the cardiovascular system includes the lymphatic system.

### LYMPHATIC SYS.<sub>D</sub>

The lymphatic system is a system of vessels assisting the veins in recovering the body's tissue fluids and returning them to the heart. The body is about 60% water and the veins alone are generally incapable of meeting the demands of tissue drainage. Lymph nodes filter lymph and are located throughout the body.

### NERVOUS SYS.<sub>E</sub>

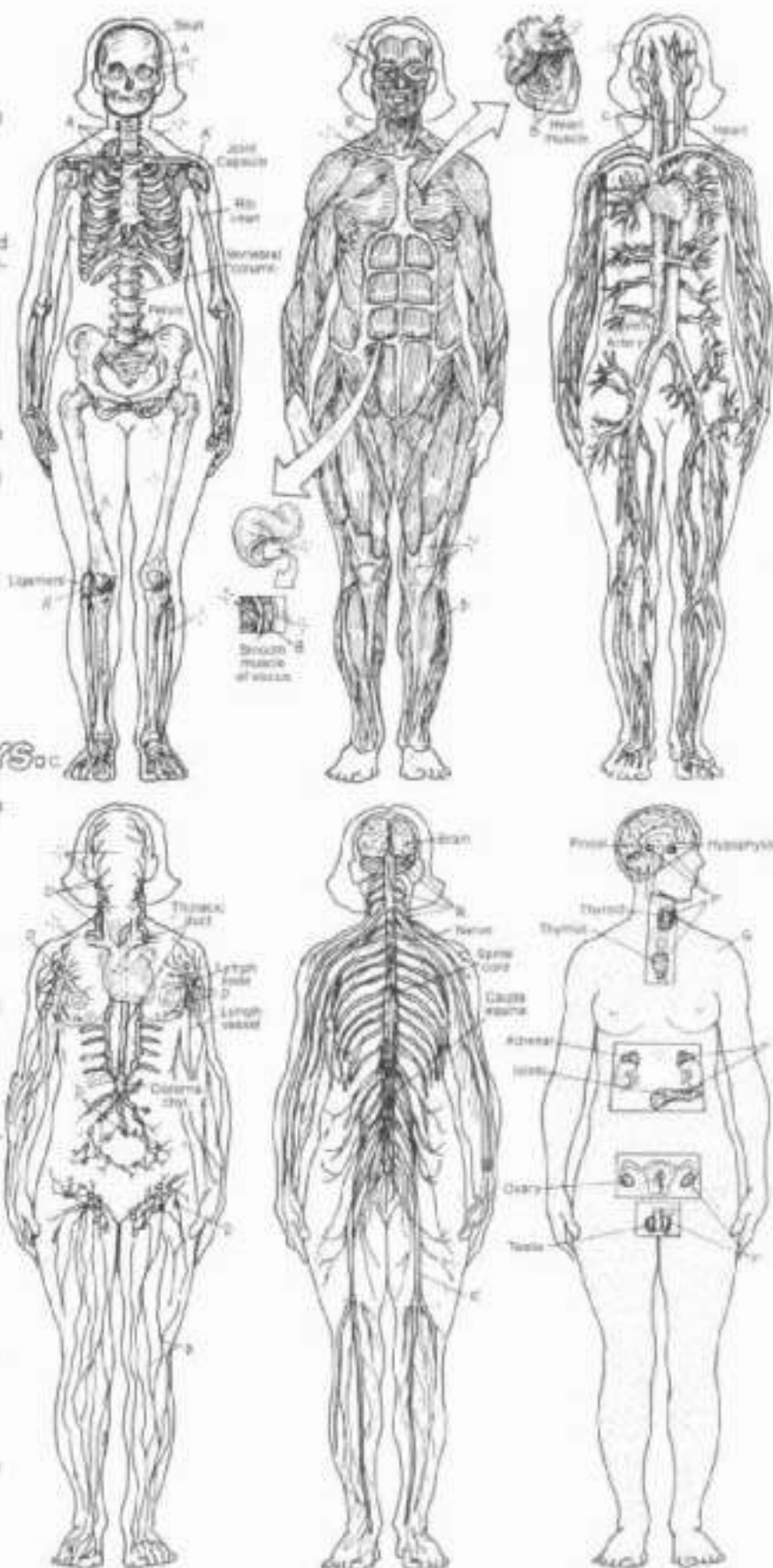
The nervous system consists of impulse-generating/conducting tissue organized into a central nervous system (brain and spinal cord), and a peripheral nervous system (nerves) that includes the visceral (autonomic) nervous system involved in involuntary "fight or flight" and vegetative responses.

### ENDOCRINE SYS.<sub>F</sub>

The endocrine system consists of glands which secrete chemical agents (hormones) into the tissue fluids and blood, affecting the function of multiple areas of the body. Many of these glands are under some control by the brain (hypothalamus). Hormones help maintain balanced metabolic functions in many of the body's systems.

### INTEGUMENT. SYS.<sub>G</sub>

The integumentary system is the skin, replete with glands, sensory receptors, vessels, immune cells and antibodies, and layers of cells and keratin resisting environmental factors harmful to the body.



## II. SYSTEMS AND REGIONS SYSTEMS OF THE BODY (2)

OK. Use different light colors from those used on the preceding plate.

### RESPIRATORY SYS.<sub>OH</sub>

The respiratory system consists of the upper (nose through larynx) and lower respiratory tract (trachea through the air spaces of the lungs). Most of the tract is airway; only the air spaces (alveoli) and very small bronchioles exchange gases between air and the capillaries.

### DIGESTIVE SYS.<sub>OH</sub>

The digestive system is concerned with the breakdown, digestion and assimilation of food and excretion of the residua. Its tract begins with the mouth, continues down to the abdomen where it takes a convoluted course to open again at the anus. Associated glands include the liver and pancreas, including the biliary system (gall bladder and related ducts).

### URINARY SYS.<sub>OH</sub>

The urinary system is concerned with the conservation of water and maintenance of a neutral acid-base balance in the body fluids. The kidneys are the main functioning organs of this system; residual fluid (urine) is excreted through ureters to the urinary bladder for retention, and discharged to the outside through the urethra.

### IMMUNE / LYMPHOID SYS.<sub>OH</sub>

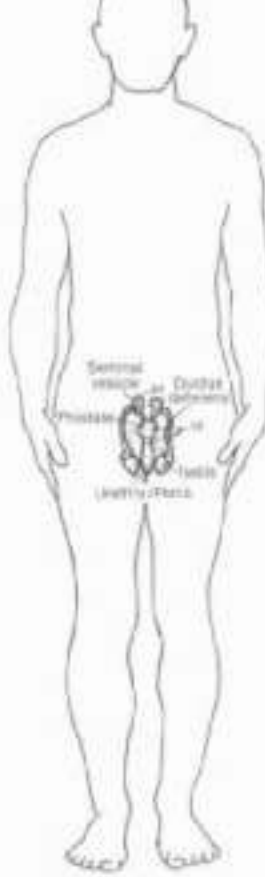
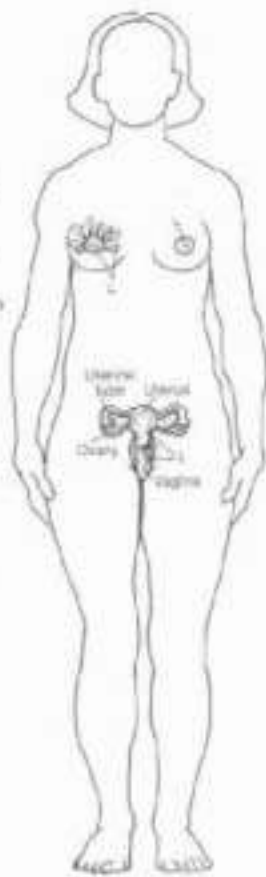
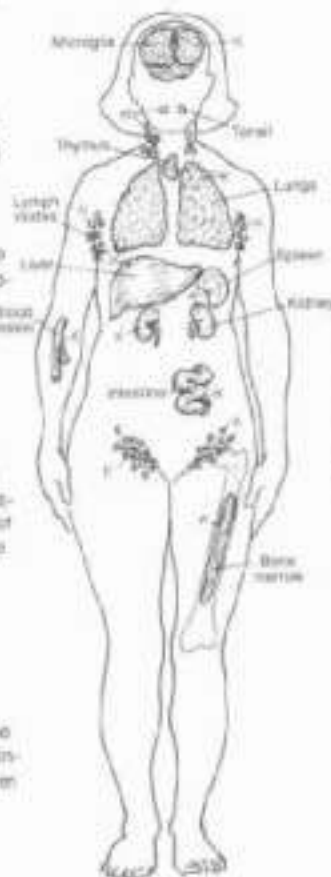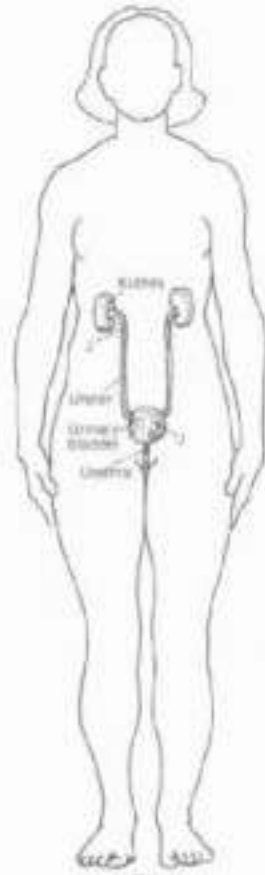
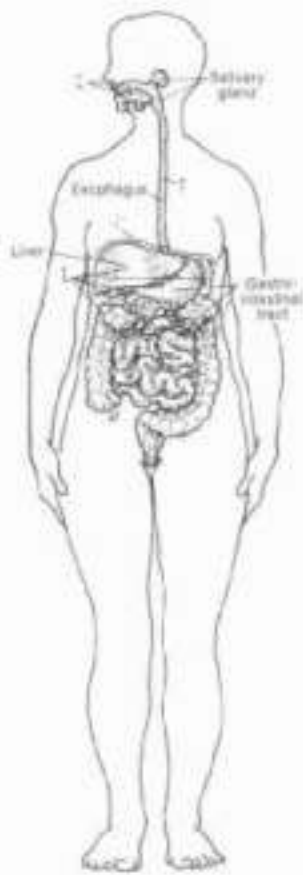
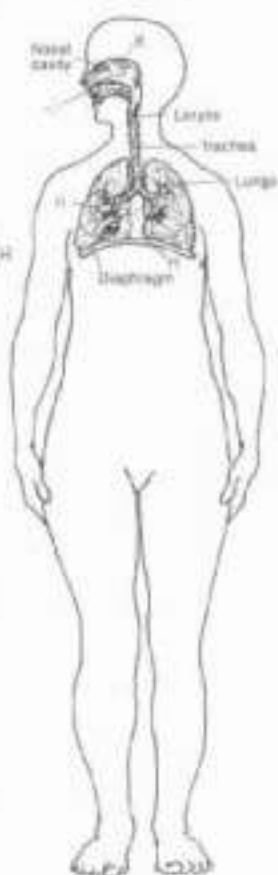
The lymphoid system consists of organs concerned with body defense: thymus, bone marrow, spleen, lymph nodes, tonsils, and smaller aggregates of lymphoid tissue. This system, including a diffuse arrangement of immune-related cells throughout the body is concerned with resistance to invasive microorganisms, and the removal of damaged and/or otherwise abnormal cells.

### REPRODUCTIVE SYS. / FEMALE

The female reproductive system is concerned with the secretion of sex hormones, production and transportation of germ cells (ova), receipt and transport of male germ cells to the fertilization site, maintenance of the developing embryo/fetus, and initial sustenance of the newborn.

### REPRODUCTIVE SYS. / MALE

The male reproductive system is concerned with the secretion of male sex hormones, formation and maintenance of germ cells (sperm), and transport of germ cells to the female genital tract.



## II. SYSTEMS AND REGIONS

### REGIONS OF THE BODY

ON: You will most likely have to repeat colors among the arrows shown here. Consider a coloring pattern based on major regions (shades of red for head and neck, blues for upper limb, brown for lower limb, and so on).

#### HEAD/NECK:

CRANIAL<sub>A</sub>

ORBITAL<sub>B</sub>

FACIAL<sub>C</sub>

MANDIBULAR<sub>D</sub>

CERVICAL<sub>E</sub>

SUPRACLAVICULAR<sub>F</sub>

#### UPPER LIMB:

DELTOID<sub>G</sub>

AXILLARY<sub>H</sub>

BRACHIAL<sub>I</sub>

CUBITAL<sub>J</sub>

ANTECUBITAL<sub>K</sub>

ANTEBRACHIAL<sub>L</sub>

CARPAL<sub>M</sub>

#### THORAX:

PECTORAL<sub>N</sub>

SCAPULAR<sub>O</sub>

#### ABDOMINOPELVIC:

ABDOMINAL<sub>P</sub>

PELVIC<sub>Q</sub>

INGUINAL<sub>R</sub>

PUDENDAL<sub>S</sub>

#### BACK:

THORACIC<sub>T</sub>

LUMBAR<sub>U</sub>

SACROILIAC<sub>V</sub>

#### LOWER LIMB:

GLUTEAL<sub>W</sub>

FEMORAL<sub>X</sub>

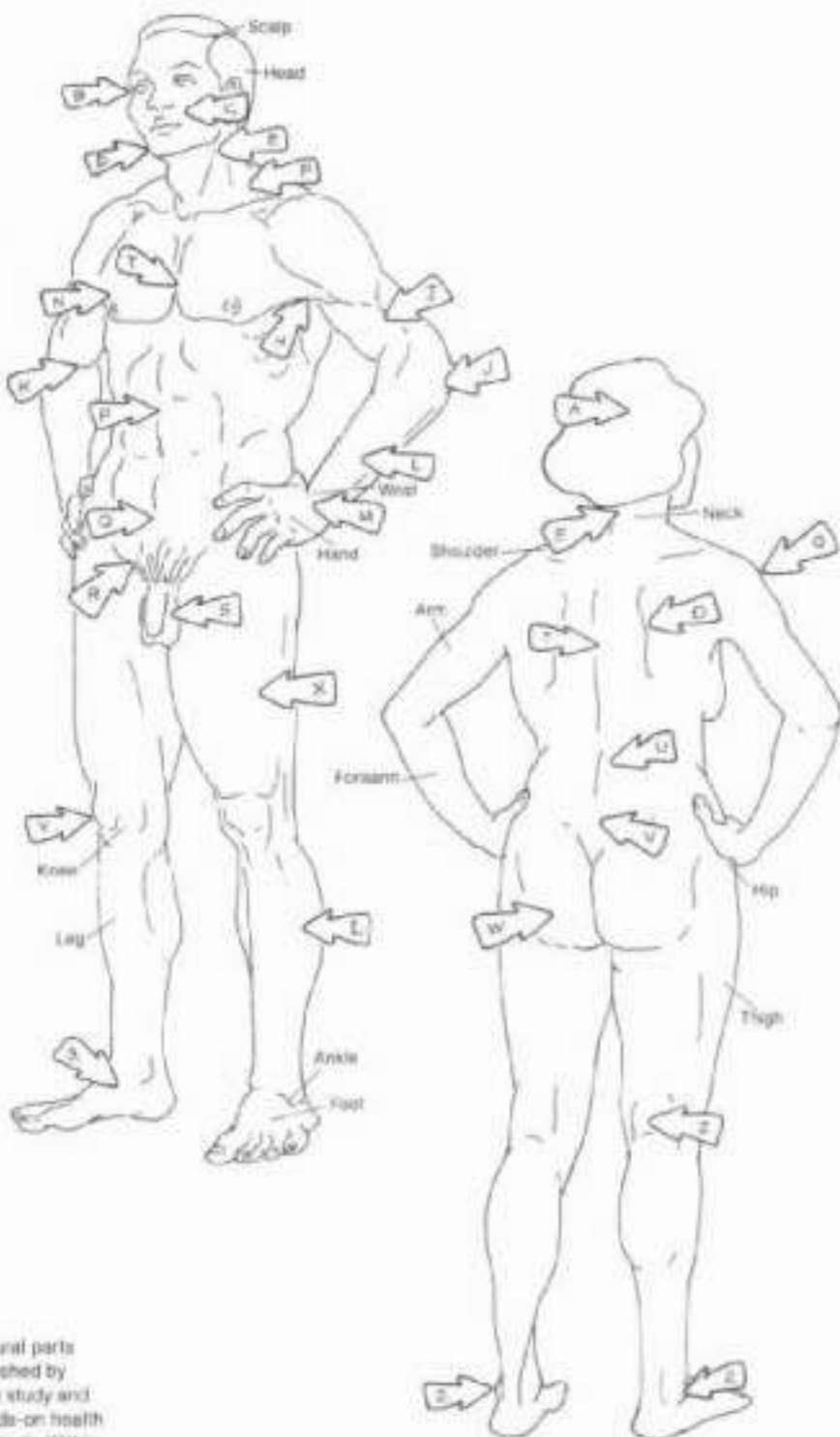
PATELLAR<sub>Y</sub>

POPLITEAL<sub>Z</sub>

CRURAL<sub>AA</sub>

MALLEOLAR<sub>AB</sub>

TARSAL<sub>AC</sub>



Regional anatomy is the organization of human structural parts by regions. The study of regional anatomy is accomplished by dissection of body parts in an embalmed cadaver. The study and awareness of regional anatomy is fundamental to hands-on health care providers who examine and evaluate the human body. Within each region, there are usually sub-divisions or sub-regions, e.g. within the cranial region, there are frontal, parietal, temporal, and occipital sub-regions. Characteristically, each region is composed of structures representing several systems.



## II. SYSTEMS AND REGIONS CAVITIES & LININGS

DI. Except for H, use light colors throughout. (1) Note that the linings for closed body cavities are all colored gray. (2) In the open visceral cavities shown below, the linings receive a darker color (H), and the closed cavities have their linings omitted.

### CLOSED BODY CAVITIES: $\vdash$

- CRANIAL<sub>A</sub> / DURA MATER<sub>A\*</sub>
- VERTEBRAL<sub>B</sub> / DURA MATER<sub>B\*</sub>
- THORACIC<sub>C</sub> / PLEURA<sub>C\*</sub>
- ABDOMINOPELVIC<sub>D</sub> / PERITONEUM<sub>D\*</sub>

Closed body cavities are not open to the outside of the body. The cranial cavity is located in the upper part of the skull and houses the brain and related structures. It is continuous with the vertebral cavity (canal) within the vertebral column. The vertebral cavity contains the spinal cord and related vessels and nerve roots. The tough, fibrous layer lining the cranial and vertebral cavities is called the dura mater. Portions of the dura envelop the brain and spinal cord; other parts are folded to form dividers (dural septa, not shown) separating parts of the brain.

The thoracic cavity is located in the thorax, surrounded by the rib cage and related muscles; its posterior wall is the vertebral column, its floor is the muscular thoracic diaphragm. The thoracic cavity is divided by a central set of structures (mediastinum) into left and right cavities for the lungs. These cavities are lined with a thin layer of simple squamous, serous epithelium supported by fibrous tissue. Such a lining secretes a watery (serous) fluid and is called a serous membrane or serosa. The serosa lining the thoracic cavities for the lungs is called pleura, a subject to be developed in Plate 95.

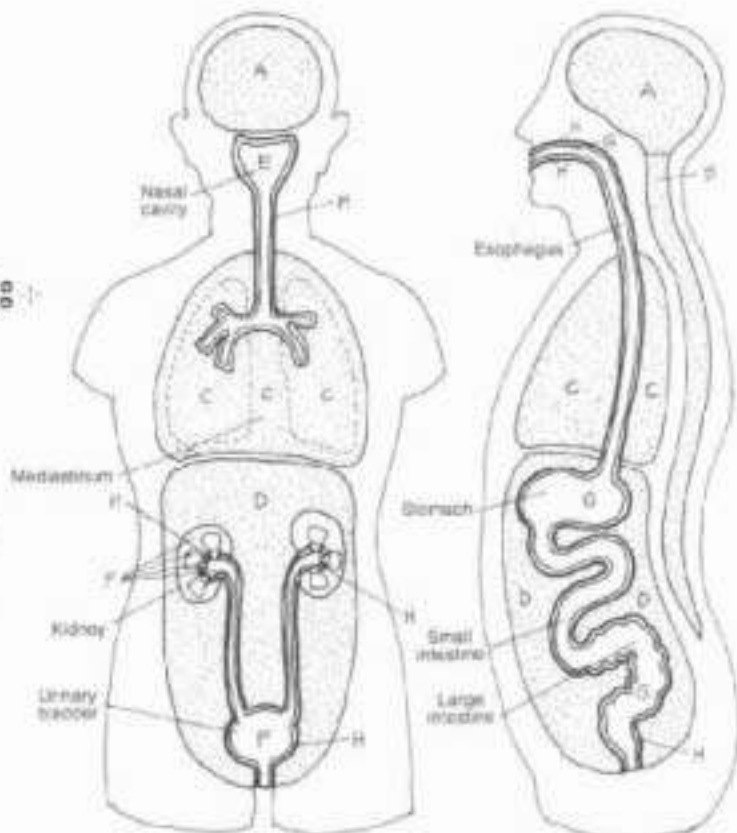
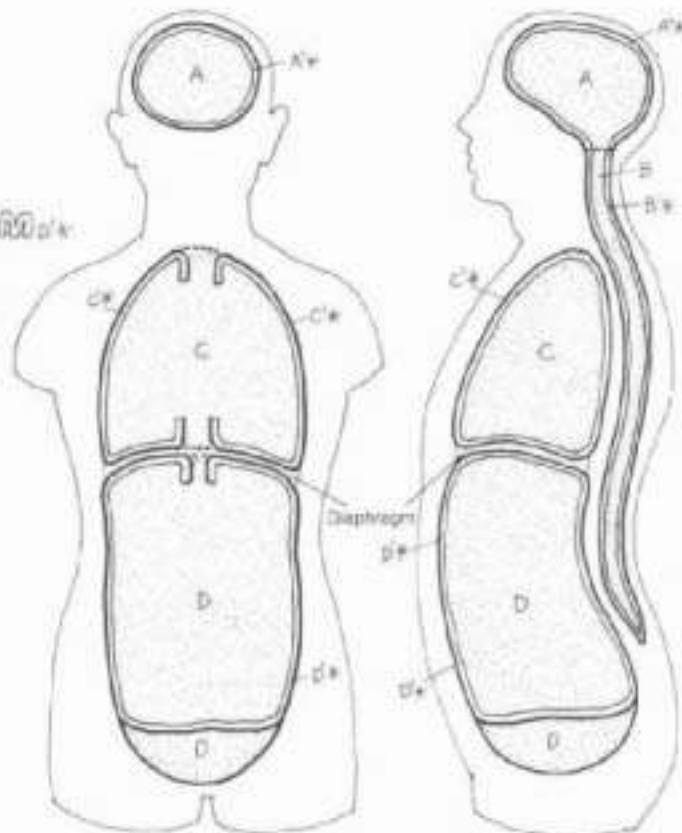
The abdominopelvic cavity is located anterior to the posterior abdominal wall. It is surrounded anteriorly and laterally by muscle layers, the lower ribs and related muscles, and the bones of the pelvis. Its upper and lower boundaries are muscular (respiratory and pelvic) diaphragms. The abdominopelvic cavity contains the abdominal and pelvic viscera. The abdominal cavity is largely lined with a serous membrane called peritoneum, a subject to be developed in Plate 102.

There are a number of other cavities within the body that are closed, including the joint cavities, heart, vessels, ventricles of the brain, cavities/ducts of the eye and internal ear, and the potential cavities created by the foldings of serosa membranes (Plates 65, 95, and 102).

### OPEN VISCERAL CAVITIES: $\vdash$

- RESPIRATORY TRACT<sub>E</sub>
- URINARY TRACT<sub>F</sub>
- DIGESTIVE TRACT<sub>G</sub>
- MUCOSA<sub>H</sub>

Open cavities, located within closed cavities, are open to the outside of the body. They are generally tubular cavities of viscera: the digestive, respiratory, reproductive, and urinary tracts. The digestive tract opens at the mouth superiorly and at the anus inferiorly. The respiratory tract opens at the mouth and nose. The reproductive ducts (not shown) open at the perineum; the urinary tract opens at the perineum as well. Not included in this category are glands of the skin and viscera whose ducts open on to the surface of the skin. A variety-thick membrane covered with mucus (mucous membrane or mucosa) lines open cavities. It is continuous with skin at orifices. The mucosa is the working membrane of open cavities (secretion, absorption, protection), dealing with molecules placed before it (food, air, fluid, and so on).



## III. SKELETAL SYSTEM

### ANATOMY OF A LONG BONE

On Use light blue for C, a "bone" color for D, very light colors for E and F, yellow for L and red for J. The title red marrow (H) is not to be colored as the red marrow in this bone is not shown, having been replaced by yellow marrow during maturity. Only part of the yellow marrow in the medullary canal is shown.

Bone is a living, vascular structure, composed of organic tissue (cells, fibers, extra-cellular matrix, vessels, nerves—about 35% of a bone's weight), and mineral (calcium hydroxyapatite—about 65% of a bone's weight). Bone functions as a support structure, a site of attachment for skeletal muscle, ligaments, tendons, and joint capsules, a source of calcium, and a significant site of blood cell development (hematopoiesis) for the whole body. Here we show a long bone, specifically the femur, the bone of the thigh.

#### EPIPHYSIS<sub>A</sub>

The epiphysis is the end of a long bone or any part of a bone separated from the main body of an immature bone by cartilage. It is formed from a secondary site of ossification. It is largely cancellous bone, and its articulating surface is lined with 3-5 mm of tissue articular cartilage. The epiphysis is supplied by vessels from the joint capsule.

#### DIAPHYSIS<sub>B</sub>

The diaphysis is the shaft or central part of a long bone. It has a marrow-filled cavity (medullary cavity) surrounded by compact bone which is lined externally by periosteum and internally by endosteum (not shown). The diaphysis is formed from one or more primary sites of ossification, and is supplied by one or more nutrient arteries.

#### ARTICULAR CARTILAGE<sub>C</sub>

The only remaining evidence of an adult bone's cartilaginous past, articular cartilage is smooth, slippery, porous, malleable, insensitive, and bloodless. It is massaged by movement, permitting absorption of synovial fluid, oxygen and nutrition. Articular (hyaline) cartilage is also nourished by vessels from the subchondral bone. Bones of a synovial joint make physical contact at their cartilaginous ends. The degenerative process of arthritis involves the breakdown and fibrillation of articular cartilage.

#### PERIOSTEUM<sub>D</sub>

Periosteum is a fibrous, cellular, vascular and highly sensitive life support sheath for bone, providing nutrient blood for bone cells and a source of osteoprogenitor cells throughout life. It does not cover articular cartilage.

#### CANCELLOUS (SPONGY) BONE<sub>E</sub>

Cancellous (spongy) bone consists of interwoven beams (trabeculae) of bone in the epiphyses of long bones, the bodies of the vertebrae, and other bones without cavities. The spaces among the trabeculae are filled with red or yellow marrow and blood vessels. Cancellous bone forms a dynamic latticed truss capable of mechanical alteration (remodelling, construction, destruction) in response to the stresses of weight, postural change, and muscle tension.

#### COMPACT BONE<sub>F</sub>

Compact bone is dense bone characterized in long bones by microscopic hollow cylinders of bone (Haversian systems) interwoven with non-cylindrical lamellae of bone. It forms the stout walls of the diaphysis of long bones and the thinner outer surface of other bones where there is no articular cartilage, e.g., the flat bones of the skull. Blood vessels reach the bone cells by a system of integrated canals.

#### MEDULLARY CAVITY<sub>G</sub>

The medullary cavity is the cavity of the diaphysis. It contains marrow, red in the young turning to yellow in many long bones in maturity. It is lined by endosteal tissue (thin connective tissue with many osteoprogenitor cells).

#### RED MARROW<sub>H</sub>

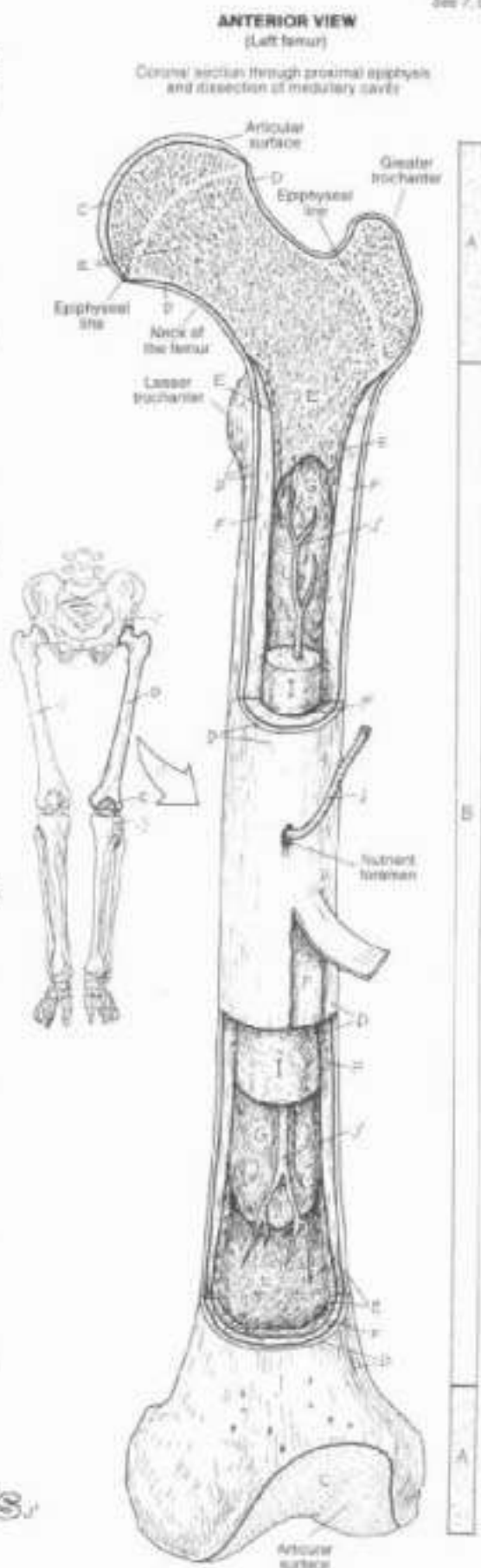
Red marrow is a red, gelatinous substance composed of a red and white blood cells in a variety of developmental forms (hematopoietic tissue) and specialized capillaries (sinusoids) enmeshed in reticular tissue. In adults, red marrow is generally limited to the sternum, vertebrae, ribs, hip bones, clavicles, and cranial bones.

#### YELLOW MARROW<sub>I</sub>

Yellow marrow is fatty connective tissue and no longer productive of blood cells. It replaces red marrow in the epiphyses and medullary cavities of long bones, and cancellous bone of other bones.

#### NUTRIENT ARTERY / BRANCHES<sub>J</sub>

The nutrient artery is the principal artery and major supplier of oxygen and nutrients to the shaft or body of a bone; its branches snake through the labyrinthine canals of the Haversian systems and other tubular cavities of bones.



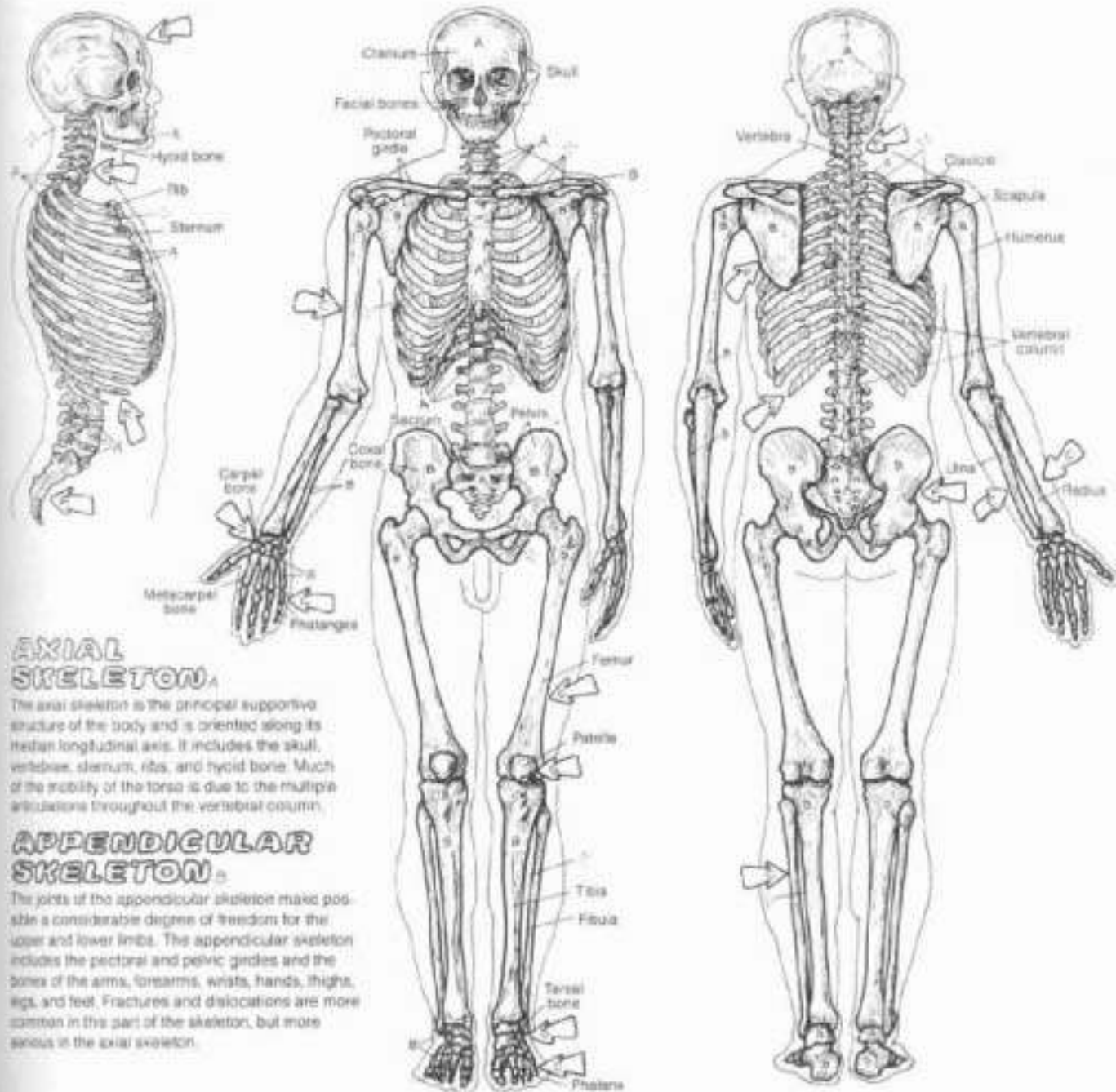
# III. SKELETAL SYSTEM

## AXIAL/APPENDICULAR SKELETON

- On size light but contrasting colors for A and B.  
 (1) First color the axial skeleton A in all three views.  
 (2) Use color the appendicular skeletons.  
 (3) Color the appendicular skeleton B.  
 Note that the bones labeled A are drawn in a lighter line than B.  
 (4) Color the arrows identifying bone shape/classification.

**CLASSIFICATION OF BONES:**  
 LONG,  
 SHORT,  
 FLAT,  
 IRREGULAR,  
 SESAMOID.

Bones have a variety of shapes and defy classification by shape; yet such a classification generally exists. Long bones are clearly longer in one axis than in another, they are characterized by a medullary cavity, a hollow diaphysis of compact bone, and at least two epiphyses; e.g., femur, phalanx. Short bones are roughly cube-shaped, they are predominantly cancellous bone with a thin cortex of compact bone, no cavity, e.g., carpal and tarsal bones. Flat bones (cranial bones, ribs) are generally more flat than round, and irregular bones (scapula, vertebrae) have two or more different shapes; e.g., the scapula, with a flat surface, and irregular-shaped spine. Bones not specifically long or short fit this latter category. Sesamoid bones are developed in tendons (e.g., patellar tendon); they are mostly bone, often mixed with fibrous tissue and cartilage. They have a cartilaginous articular surface facing an articular surface of an adjacent bone; they may be part of a synovial joint ensheathed within the fibrous joint capsule. They are generally pea-sized, and are almost always found in certain tendons/joint capsules in hands and feet, and occasionally in other articular sites of the upper and lower limbs. The largest is the patella, in the tendon of quadriceps femoris. Sesamoid bones resist friction and compression, enhance joint movement, and may assist local circulation.



### AXIAL SKELETON

The axial skeleton is the principal supportive structure of the body and is oriented along its median longitudinal axis. It includes the skull, vertebrae, sternum, ribs, and hyoid bone. Much of the mobility of the torso is due to the multiple articulations throughout the vertebral column.

### APPENDICULAR SKELETON

The joints of the appendicular skeleton make possible a considerable degree of freedom for the upper and lower limbs. The appendicular skeleton includes the pectoral and pelvic girdles and the bones of the arms, forearms, wrists, hands, thighs, legs, and feet. Fractures and dislocations are more common in this part of the skeleton, but more serious in the axial skeleton.



## III. SKELETAL SYSTEM

### BONES OF THE SKULL (1)

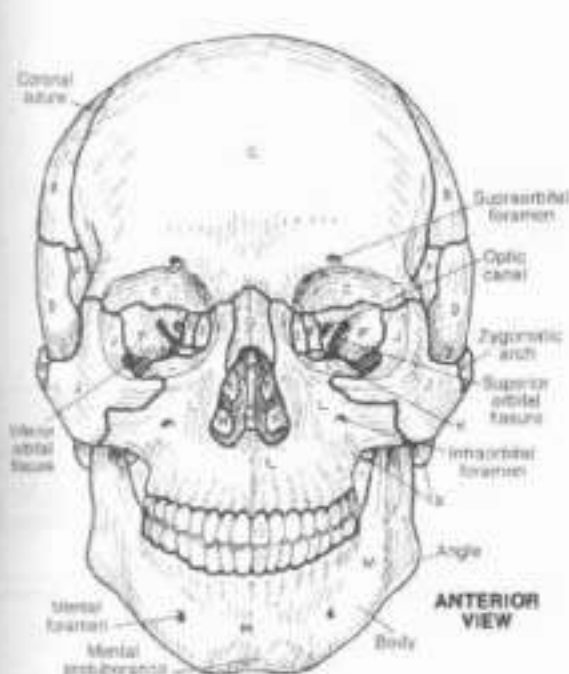
#### CRANIAL (8):

OCCIPITAL (1), PARIETAL (2), FRONTAL (1),  
TEMPORAL (2), ETHMOID (1), SPHENOID (1),

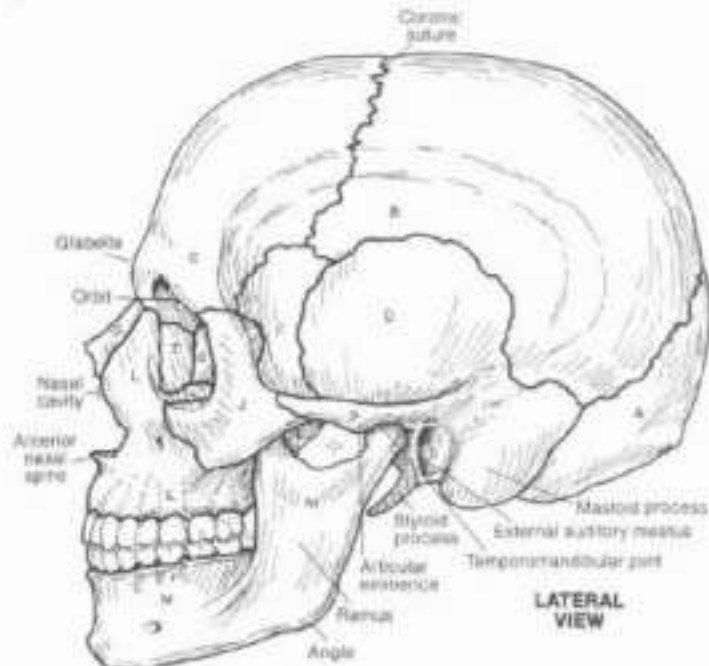
#### FACIAL (14):

NASAL (2), VOMER (1), LACRIMAL (2),  
ZYGOMATIC (2), PALATINE (2), MAXILLA (2),  
MANDIBLE (1), INFERIOR NASAL CONCHA (2)

Or: Work with this plate and the next one at the same time. Save the brightest colors for the smallest bones; use light colors on bones with surface detail. Work one bone at a time, coloring it where it appears in any of the 7 views shown on this and the next plate. (In the anterior view, do not color the darkened areas in the orbits and nasal cavity.)



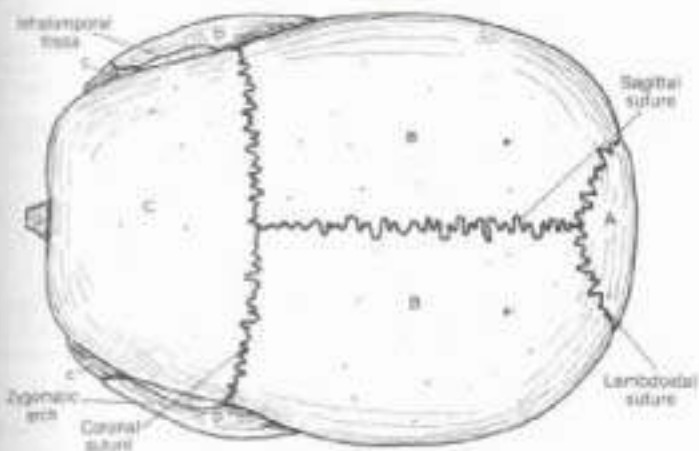
ANTERIOR VIEW



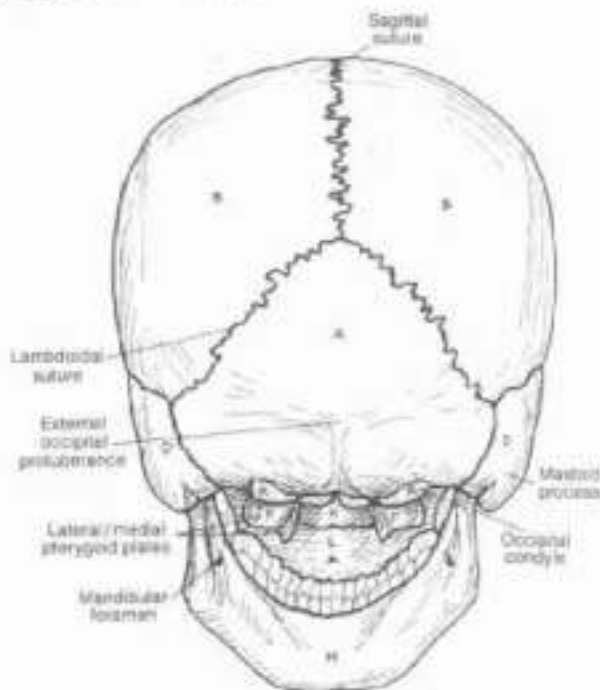
LATERAL VIEW

The skull is composed of cranial bones (forming a vault for the brain) and facial bones (giving origin to the muscles of facial expression and providing bulges protecting the brain). Except for the temporomandibular joint (a synovial joint), all bones are connected by generally immovable fibrous sutures.

The orbit is composed of 7 bones, has 3 significant fissures/canals, and is home to the eye and related muscles, nerves, and vessels. The most delicate of the skull bones is at the medial orbital wall (1). The external nose is largely cartilaginous and is, therefore, not part of the bony skull.



SUPERIOR VIEW



POSTERIOR VIEW

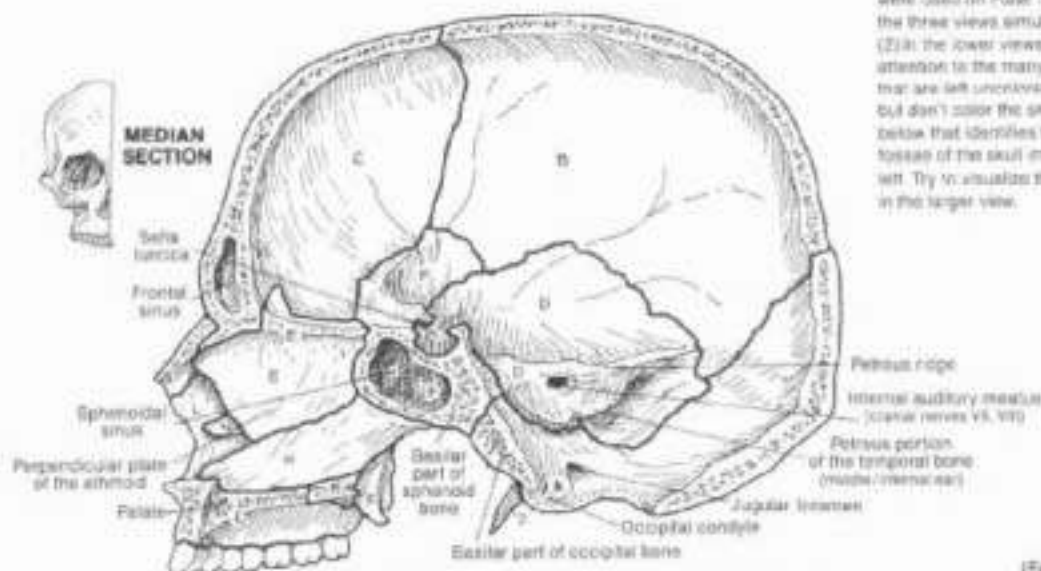


# II. SKELETAL SYSTEM

## BONES OF THE SKULL (2)

**CRANIAL:** OCCIPITAL, PARIETAL, FRONTAL, TEMPORAL, ETHMOID, SPHENOID.  
**FACIAL:** NASAL, VOMER, ZYGOMATIC, PALATINE, MAXILLA, INFERIOR NASAL CONCHA.

CA Use the same colors as were used on Page 18. (1) Color the three views simultaneously. (2) In the lower views, pay close attention to the many foramina that are left uncolored. (3) Notice but don't color the small drawing below that identifies the large foramen of the skull interior to its left. Try to visualize these foramina in the larger view.

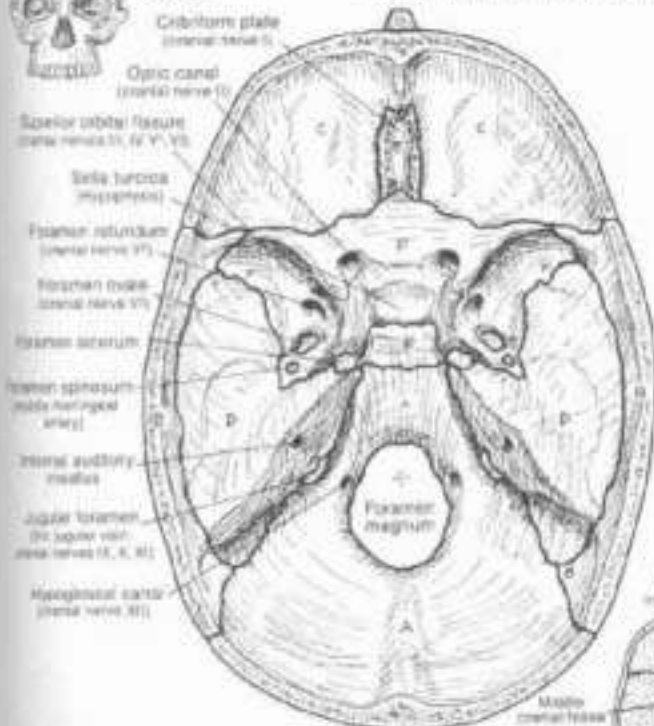


You are looking into the interior of the right side of the skull. The vomer and perpendicular plate of the ethmoid contribute significantly to the nasal septum, and hide from view the cochlea on the lateral wall of the nasal cavity.

(Interior view)



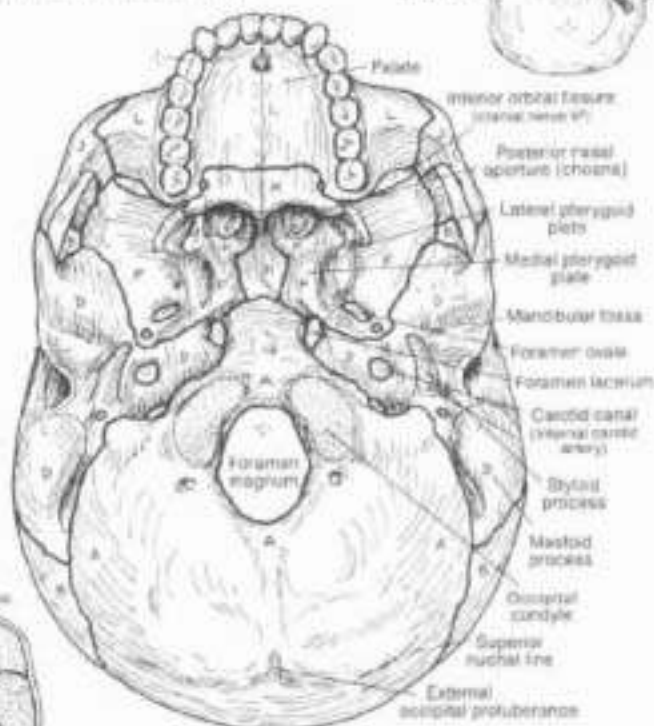
### BASE OF SKULL



You are looking into the cranial cavity from above. The anterior cranial fossa contains the frontal lobes of the cerebrum (brain); the olfactory tracts lie over the cribriform plates and receive the olfactory nerves. The middle cranial fossa embraces the temporal lobes of the cerebrum; note the numerous foramina/canals for cranial nerves and vessels which enter/exit the cavity. The posterior cranial fossa retains the cerebellum and the brain stem, along with related cranial nerves and vessels which enter/exit the cavity.

(Exterior view)

### BASE OF SKULL



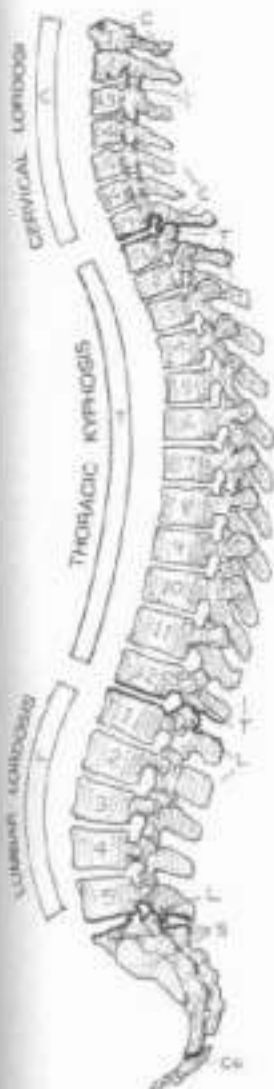
The occipital condyles articulate with the facets of the atlas or first cervical vertebra. The muscular pharyngeal wall attaches around the posterior nasal apertures. The lateral pterygoid plate offers attachment for certain muscles of mastication. The foramen magnum transmits the lower brain stem/spinal cord and the vertebral arteries. Much of the occipital bone posterior to the foramen magnum is a site of attachment for large muscle bundles making up the posterior cervical (paraspinal) musculature.

# III. SKELETAL SYSTEM

## VERTEBRAL COLUMN

CH. Use gray for D, yellow for H, and light colors for the rest, especially C, T, L, S, and Co. (1) Begin with reports of the column and the three examples of vertebral disorders at lower left. (2) Color the motion segment and its role in flexion and extension. (3) Color the vertebral foramina and canal. (4) Color the example of a protruding intervertebral disc pressing on a spinal nerve.

**REGIONS:**  
**CERVICAL:**  
**THORACIC:**  
**LUMBAR:**  
**SACRAL:**  
**COCCYGEAL:**



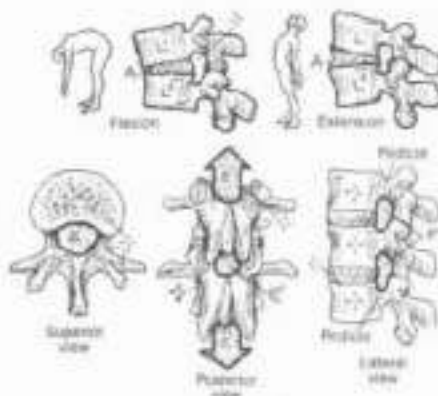
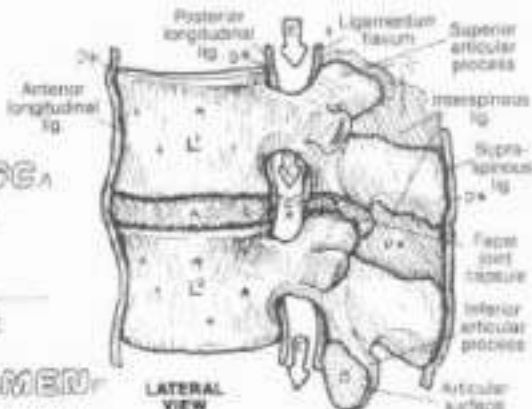
The vertebral column has 24 individual vertebrae arranged in cervical, thoracic, and lumbar regions; the sacral and coccygeal vertebrae are fused (sacrum/coccyx). Numbers of vertebrae in each region are remarkably constant; rarely S1 may be free or L5 may be fused to the sacrum (transitional vertebrae). The seven mobile cervical vertebrae support the neck and the 3-4 kg (8-8 lb) head. The cervical spine is normally curved (cervical lordosis) secondary to the development of postural reflexes about three months after birth. The 12 thoracic vertebrae support the thorax, head, and neck. They articulate with 12 ribs bilaterally. The thoracic spine is congenitally curved (kyphosis) as shown. The five lumbar vertebrae support the upper body,

torso, and low back. The column of these vertebrae is curved (lumbar lordosis) due to the onset of walking at 1-2 years of age. The sacrum is the keystone of a weightbearing arch involving the hip bones. The sacral/coccygeal curve is congenital. The variably numbered 1-5 coccygeal vertebrae are usually fused, although the first vertebra may be movable.

Vertebral curvatures may be affected (usually exaggerated) by posture, activity, obesity, pregnancy, trauma, and/or disease; these conditions are named the same as the normal curves. There may normally be a slight lateral curvature to the spine often due to dominant handedness; a significant, possibly disabling, lateral curve (scoliosis) may occur for many reasons.

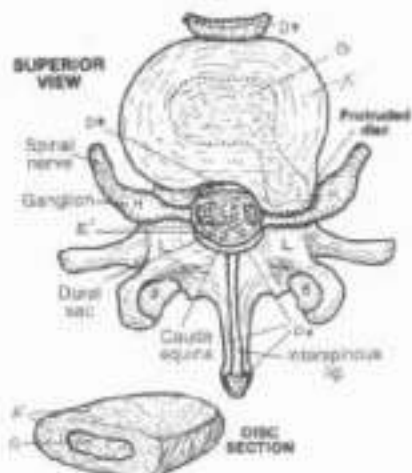
**MOTION SEGMENT:**  
**VERTEBRAE:**  
**JOINTS:**  
**INTERVERTEBRAL DISC,**  
**POSTERIOR (FACET),**  
**LIGAMENT,**  
**VERTEBRAE:**  
**VERTEBRAL FORAMEN:**  
**VERTEBRAL CANAL:**  
**INTERVERTEBRAL FORAMEN:**

Each pair of individual, unfused vertebrae constitutes a motion segment, the basic movable unit of the back. Combined movements of motion segments underlie movement of the neck, middle and low back. Each pair of vertebrae in a motion segment, except C1-C2, is attached by three joints: a partly movable, intervertebral disc anteriorly, and a pair of gliding synovial (facet) (zygapophysial) joints posteriorly. Ligaments secure the bones together and encapsulate the facet joints (joint capsules). The vertebral or neural canal, a series of vertebral foramina, transmits the spinal cord and related coverings, vessels, and nerve roots. Located bilaterally between each pair of vertebral pedicles are passageways, each called an intervertebral foramen, transmitting spinal nerves, their coverings/vessels, and some vessels to the spinal cord.

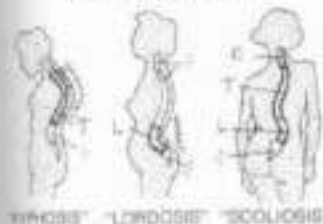


**INTERVERTEBRAL DISC:**  
**ANNULUS FIBROSUS:**  
**NUCLEUS PULPOSUS:**  
**SPINAL NERVE:**

The intervertebral disc consists of the annulus fibrosus (concentric, interwoven collagenous fibers impregnated with cartilage cells) attached to the vertebral bodies above and below, and the more central nucleus pulposus (a mass of degenerated collagen, proteoglycans, and water). The discs make possible movement between vertebral bodies. With aging, the discs dehydrate and thin, resulting in a loss of height. The cervical and lumbar discs, particularly, are subject to early degeneration from one or more of a number of causes. Weakening and/or tearing of the annulus can result in a broad-based bulge or a localized (focal) protrusion of the nucleus and adjacent annulus; such an event can compress a spinal nerve root as shown.



**VERTEBRAL DISORDERS**



KYPHOSIS    LORDOSIS    SCOLIOSIS

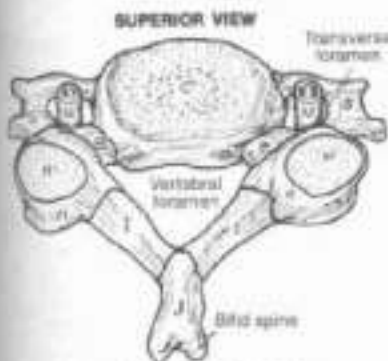
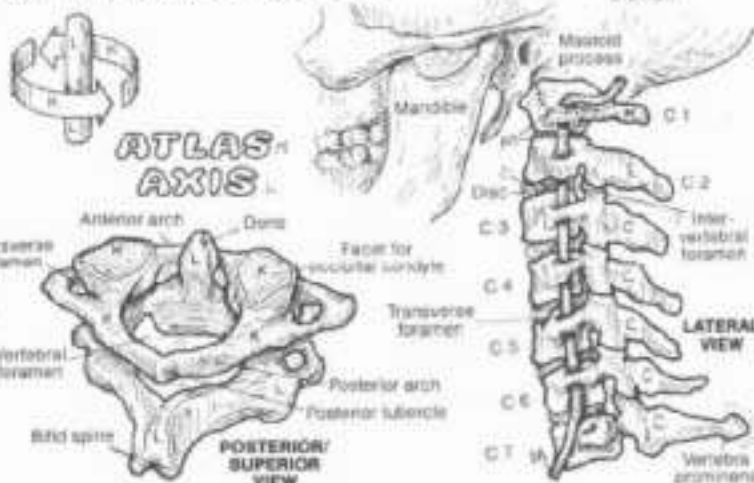
# III. SKELETAL SYSTEM

## CERVICAL AND THORACIC VERTEBRAE

Use red for M and use the same colors as were used on Plate 21 for C and T. Use dark colors for N, D, and P. (1) Begin with the parts of cervical vertebra. Color the atlas and axis and note they have been given separate colors to distinguish them from other cervical vertebrae. (2) Color the parts of a thoracic vertebra and then the thoracic portion of the vertebral column. Note the three different facet/demifacet colors.

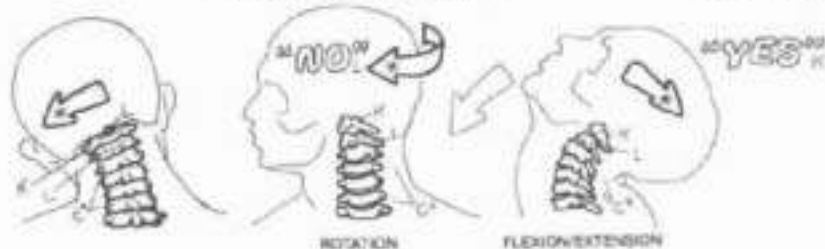
### CERVICAL VERTEBRA:

- BODY.
- PEDICLE.
- TRANSVERSE PROCESS.
- ARTICULAR PROCESS.
- FACET.
- LAMINA.
- SPINOUS PROCESS.

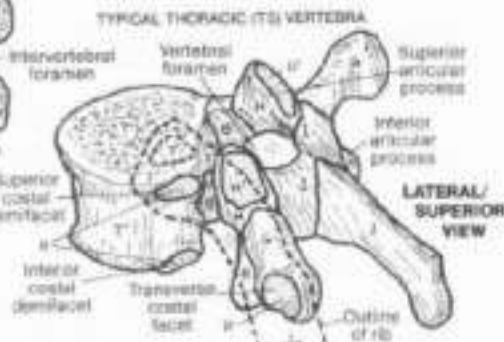
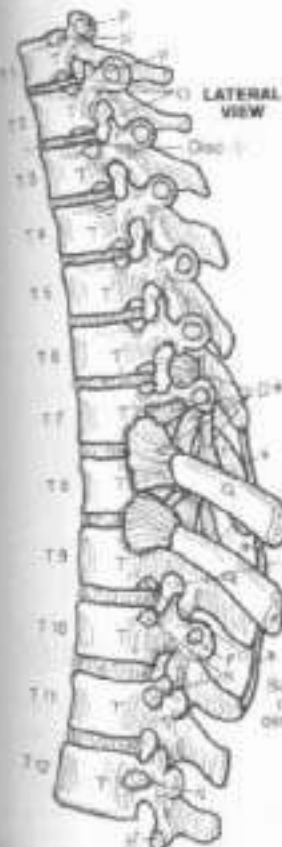

TYPICAL CERVICAL (C4) VERTEBRA

### MOVEMENT.



### VERTEBRAL ARTERY.



### THORACIC VERTEBRA:

- BODY.
- FACET.
- DEMIFACET.
- TRANSVERSE FACET.
- RIB.
- LIGAMENT.

The small seven cervical vertebrae support and move the head and neck, supported by ligaments and strap-like paracervical (paraspinal) muscles. The ring-shaped atlas (C1) has no body, thus there are no weight-bearing discs between the occiput and C1, and between C1 and C2 (the axis). Head weight is transferred to C3 by the large articular processes and facets of C1 and C2. The atlantooccipital joints, in conjunction with the C3-C7 facet joints, permit a remarkable degree of flexion/extension ("yes" movements). The dens of C2 projects into the anterior part of the C1 ring, forming a pivot joint, enabling the head and C1 to rotate almost 50° ("no" movements). Such rotational capacity is permitted by the relatively horizontal orientation of the cervical facets. The C3-C6 vertebrae are similar; C7 is remarkable for its prominent spinous process, easily palpated. The anteriorly directed cervical curve and the extensive paracervical musculature preclude palpation of the other cervical spinous processes. The vertebral arteries, enroute to the brain stem, pass through foramina of the transverse processes of the upper six cervical vertebrae. These vessels are subject to stretching injuries with extreme cervical rotation of the hyperextended neck. The cervical vertebral canal conducts the cervical spinal cord and its coverings (not shown). The C4-5 and C5-6 motion segments are the most mobile of the cervical region and are particularly prone to disc/facet degeneration.

The twelve thoracic vertebrae—characterized by long, slender spinous processes, heart-shaped bodies, and nearly vertically oriented facets—articulate with ribs bilaterally. In general, each rib forms a synovial joint with two demifacets on the bodies of adjacent vertebrae and a single facet on the transverse process of the lower vertebra. Variations of these costovertebral joints are seen with T1, T11, and T12.



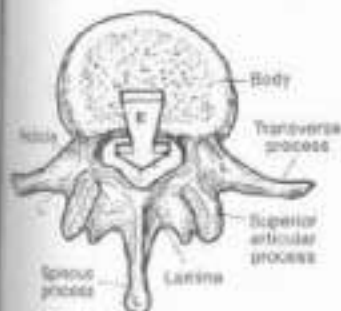
### III. SKELETAL SYSTEM

## LUMBAR, SACRAL, & COCCYGEAL VERTEBRAE

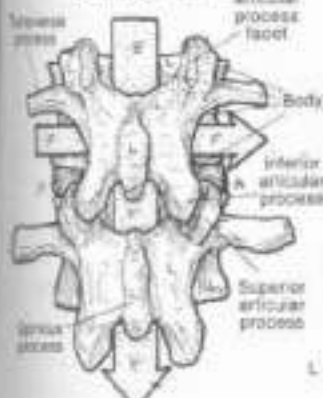
Use the same colors as were used on the previous two plates for C1-C7, L1-L5, S, and Co. (1) Begin with the three large views of lumbar vertebrae. (2) Color the different planes of articular facets. (3) Color the four views of the sacrum and coccyx. Note that the central portion of the median section receives the vertebral canal color. (4)

### LUMBAR VERTEBRA. VERTEBRAL FORAMEN. VERTEBRAL CANAL. INTERVERTEBRAL FORAMEN. INTERVERTEBRAL DISC.

The five lumbar vertebrae are the most massive of all the individual vertebrae, their thick processes securing the attachments of numerous ligaments and muscles/tendons. Significant flexion and extension of the lumbar and lumbosacral motion segments, particularly at L4-L5 and L5-S1, are possible. At about L1, the spinal cord terminates and the cauda equina (bundle of lumbar, sacral, and coccygeal nerve roots; see Plate 21) begins. The lumbar intervertebral foramina are large. Traversing nerve roots/sheaths take up only about 50% of the volume of these foramina. Disc and facet degeneration is common in the L4-5 and L5-S1 segments; reduction of space for the nerve roots increases the risk of nerve root irritation/compression (radiculitis/radiculopathy). Occasionally, the L5 vertebra is partially or completely fused to the sacrum (sacroized L5). The S1 vertebra may be partially or wholly non-fused (lumbalized S1), resulting in essentially six lumbar vertebrae.

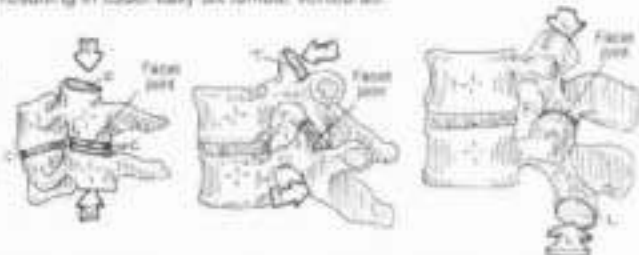

SUPERIOR VIEW

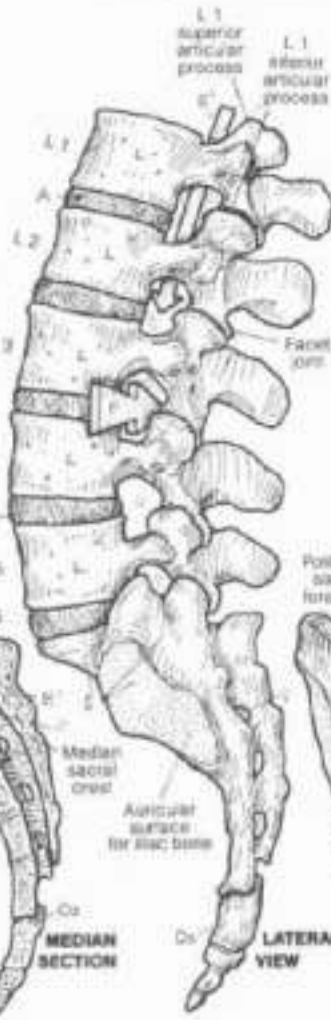

POSTERIOR VIEW

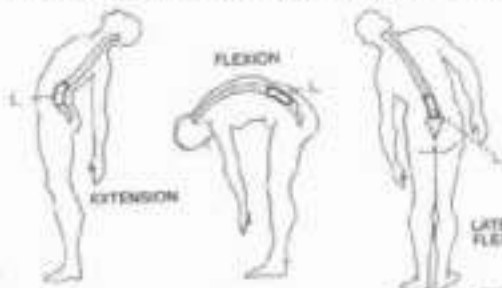
### PLANES OF ARTICULAR FACETS: CERVICAL THORACIC LUMBAR.



The planes (orientation) of the articular facets determine the direction and influence the degree of motion segment movement. The plane of the cervical facets is angled coronally off the horizontal plane about 30°. Considerable freedom of movement of the cervical spine is permitted in all planes (sagittal, coronal, horizontal). The thoracic facets lie more vertically in the coronal plane, and are virtually non-weightbearing. The range of motion here is significantly limited in all planes, less so in rotation. The plane of the lumbar facets is largely sagittal, restricting rotation of the lumbar spine, transitioning to a more coronal orientation at L5-S1. The L4-L5 facet joints permit the greatest degree of lumbar motion in all planes.



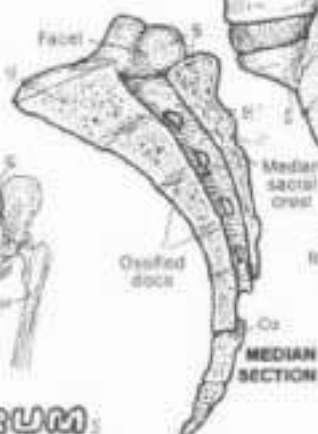LATERAL VIEW



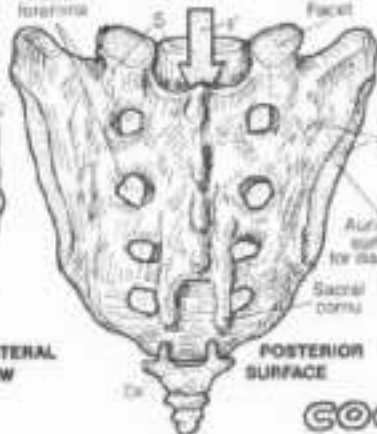
EXTENSION

FLEXION

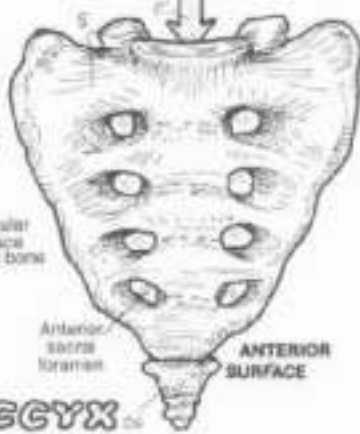
LATERAL FLEXION



MEDIAN SECTION



POSTERIOR SURFACE



ANTERIOR SURFACE

### COCCYX

### SACRUM:

The sacrum consists of five fused vertebrae; the intervertebral discs are largely replaced by bone. The sacral (vertebral) canal contains the terminal sac of the dura mater (dural sac, thecal sac) to S2 and the sacral nerve roots, which transit the sacral foramina. The sacrum joins with the ilium of the hip bone at the auricular surface, forming the sacrospinous joint.

The sacrum and the ilia of the hip bones form an arch for the transmission and distribution of weightbearing forces to the heads of the femora. It is a strong arch, and the sacrum is its keystone. The coccyx consists of 2-4 tiny individual or partly fused, rudimentary vertebrae. The first coccygeal vertebra is the most completely developed.



## II. SKELETAL SYSTEM

### BONY THORAX

On the same colors as were used on Plate 22 for true ribs, thoracic vertebrae, demifacets, and transverse process facets. Use bright colors for A-C. (1) Color the anterior view of the bony thorax. Color each rib completely before going on to the next (2). Color the posterior

view in the same manner (3). Color the lateral view of the bony thorax. (4) When coloring the drawings of a rib and the sites of articulation, note that the rib heads (drawn with dotted lines) are to be colored even though they are on the underside of the rib.

#### STERNUM:

MANUBRIUM.

BODY.

XIPHOID PROCESS.

#### 12 RIBS:

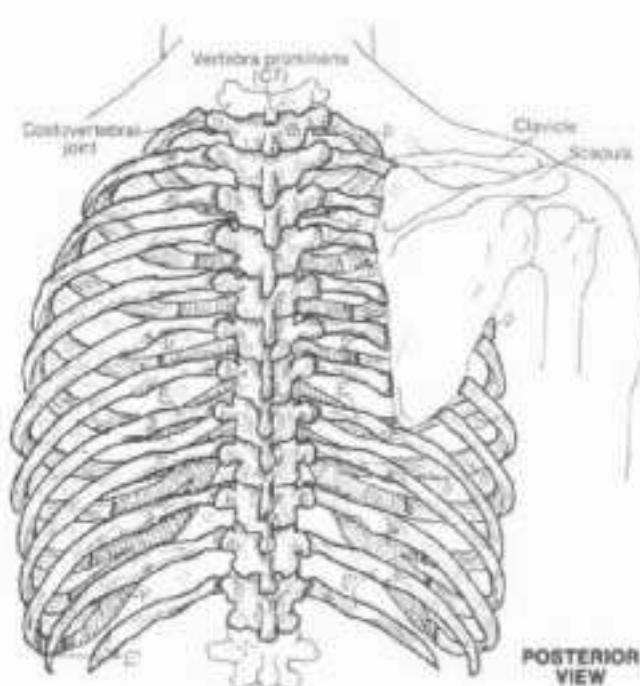
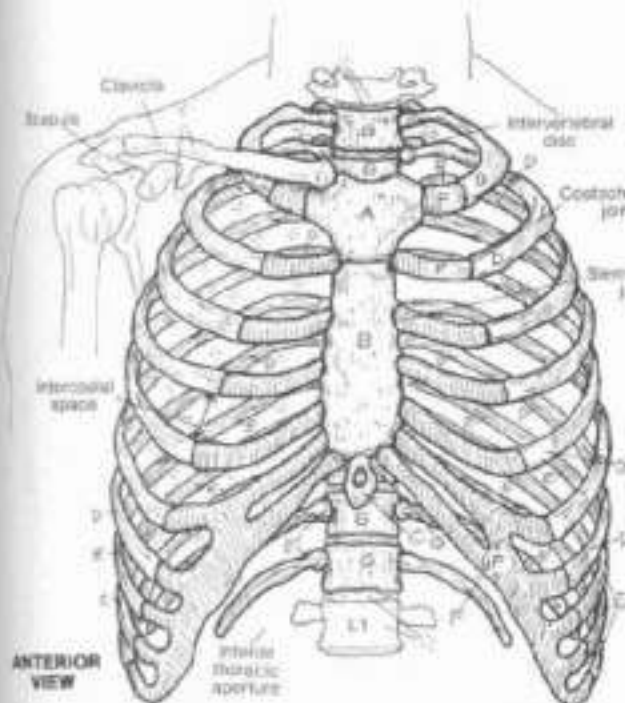
7 TRUE.

5 FALSE.

(2 FLOATING).

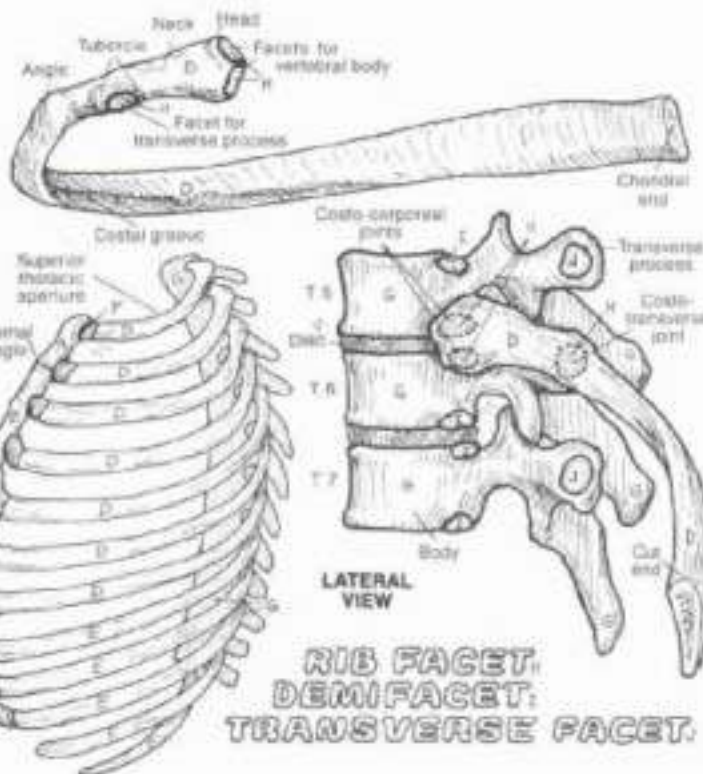
#### COSTAL CARTILAGE (10).

THORACIC VERTEBRAE (12).



The bony thorax is the skeleton of the chest, representing a fairly mobile set of structures important to respiration and harboring the heart, lungs, and other significant organs. The superior thoracic aperture (thoracic inlet; often incorrectly termed thoracic outlet in a clinical context) transmits the esophagus, trachea, nerves, and important ducts and vessels. The inferior thoracic aperture is virtually sealed by the thoracic diaphragm. The space between ribs is the intercostal space, and contains three layers of muscle and fat, and intercostal vessels and nerves. Collective rib movement is responsible for about 25% of the respiratory effort.

The fibrocartilaginous joint between the manubrium and the body of the sternum (sternal angle, sternomanubrial joint) makes subtle hinge-like movements during respiration. The xiphoid makes a fibrocartilaginous (scleroarticular) joint with the body of the sternum. The sternum is largely cancellous bone containing red marrow. The costal cartilages, representing unossified cartilage models of the anterior ribs, articulate with the sternum by gliding-type synovial joints (sternocostal joints; except for the first joint, which is not synovial). All ribs form synovial joints with the thoracic vertebrae (costovertebral joints). Within each of these joints, the rib (2 through 10) forms a synovial joint with a demifacet of the upper vertebral body and with a demifacet of the lower body (costo-vertebral joint). In addition, the tubercle of the rib articulates with a cartilaginous facet at the tip of the transverse process of the lower vertebra (costovertebral joint). Ribs 1, 10, 11, 12 each join with one vertebra instead of two; ribs 11 and 12 have no costovertebral joints. The ribs (1-7) articulate directly with the sternum. Ribs 8-12 are called false ribs; ribs 8-10 articulate indirectly with the sternum via cartilages connecting to the 7th costal cartilage; ribs 11 and 12 (also called floating ribs) end in the muscular abdominal wall.



RIB FACET.  
DEMI-FACET.  
TRANSVERSE FACET.





# III. SKELETAL SYSTEM / UPPER LIMB

## FOREARM BONES

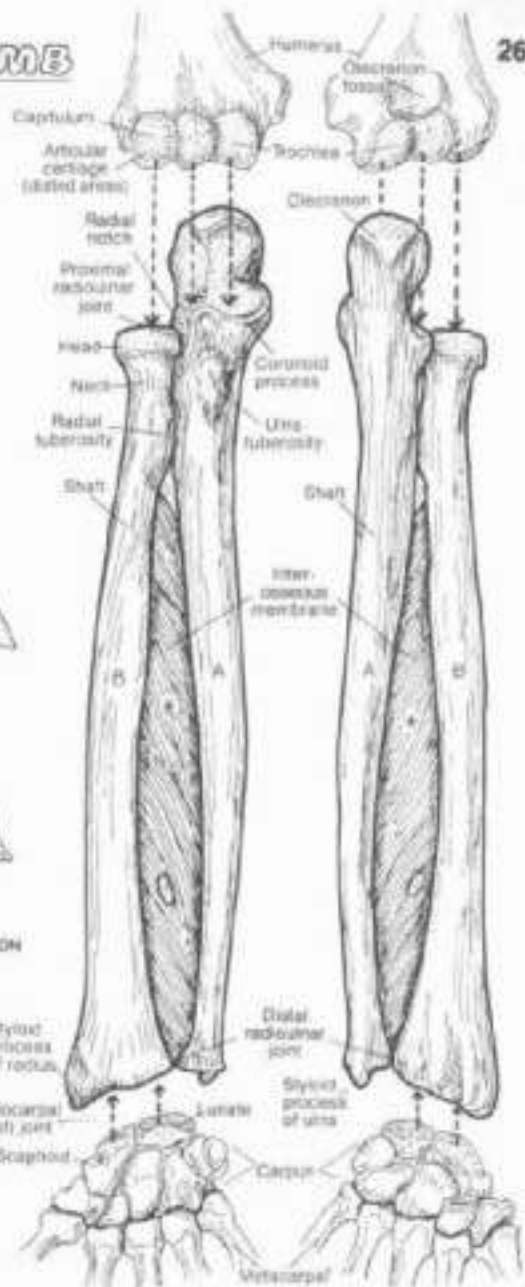
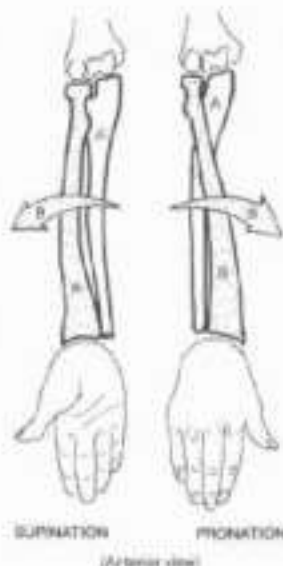
### ULNA. RADIUS.

ON Though the humerus is not colored, the tiles and arrows (C) do reflect its participation in the elbow joint should be colored with the same color the bone received on Plate 25. (1) Color the two ligaments, including the interosseous membrane (gray). (2) Color the four views of the elbow joint. (3) Color the ligaments of the region.

The presence of two bones in the forearm make possible the three movements seen at the elbow and reflected in hand motion. The ulna, the major stabilizing forearm bone at the elbow, narrows distally to form an inconsequential joint with the radius (distal radioulnar joint; synovial, pivot-type). The ulna, smaller above, widens and thickens distally to form the major joint at the wrist (radiocarpal joint, synovial, biaxial, ellipsoid-type). At the elbow, the ulna forms a hinge type synovial humeroulnar joint with the trochlea of the humerus, and the radius forms a pivot-type synovial radioulnar joint with the capitulum of the humerus. These joints share the same joint capsule with the proximal radioulnar joint (synovial, pivot type) between the radial notch of the ulna and the radial head. The three joints constitute the elbow (cubital) joint.

Fixation of the radius at the elbow (involving two of the three joints at the elbow) stabilizes the forearm, wrist, and hand without moving the ulna. Movement of the hand to a palm-forward (up) position is supination; movement of the hand to a palm-back (down) position is pronation.

For coloring and studying the supination/pronation and elbow movement diagrams, try this: place the fingers of your right hand on your right olecranon (bump at posterior elbow), elbow flexed so that the palm of your right hand is up (supine). Now rotate (pronate) your right hand so your palm turns away from you, facing down. Move your right hand back and forth in this manner, feeling that the olecranon does not move during these motions. Further, stare at the styloid process of the radius at the base of the right thumb and note that it rotates back and forth with the thumb. You have just demonstrated that the radius moves around the ulna during pronation/supination, and that joint movement occurs at the radioulnar and proximal radioulnar joints.

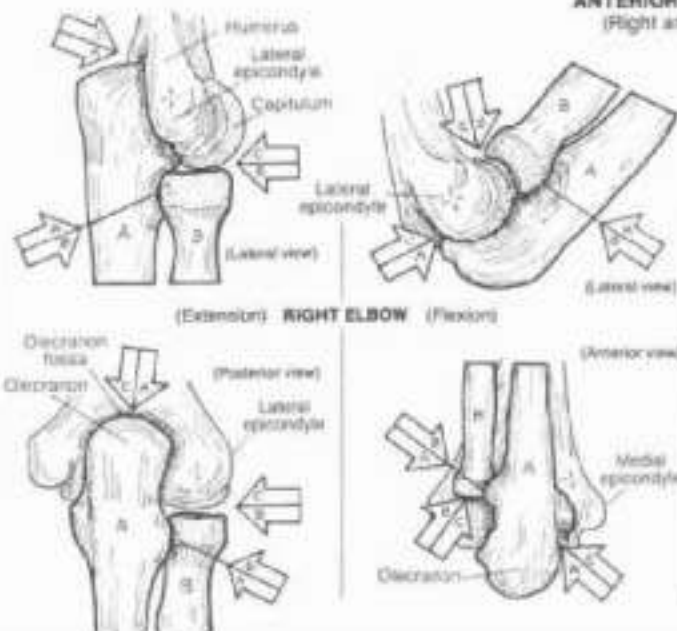


ANTERIOR VIEW (Right arm)

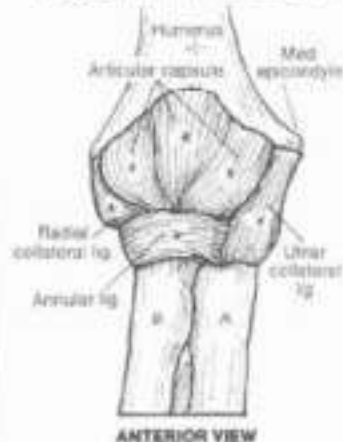
POSTERIOR VIEW (Right arm)

### 3 JOINTS AT THE RIGHT ELBOW:

- HUMERO-ULNAR.
- RADIO-UMERAL.
- RADIO-ULNAR.



### LIGAMENTS.



ANTERIOR VIEW

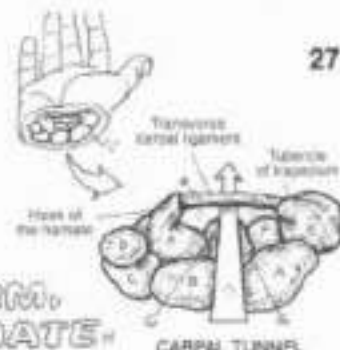


## II. SKELETAL SYSTEM / UPPER LIMB

### WRIST AND HAND BONES

CM Use two light colors other than those used on Plates 25 and 26 for I and J. (T) Color each bone, or bone group, in a five major views simultaneously. Note the hand drawings which demonstrate movements at the joints. (2) Color the bones and ligament of the carpal tunnel. You may wish to color those bones in their location in the hand to the left.

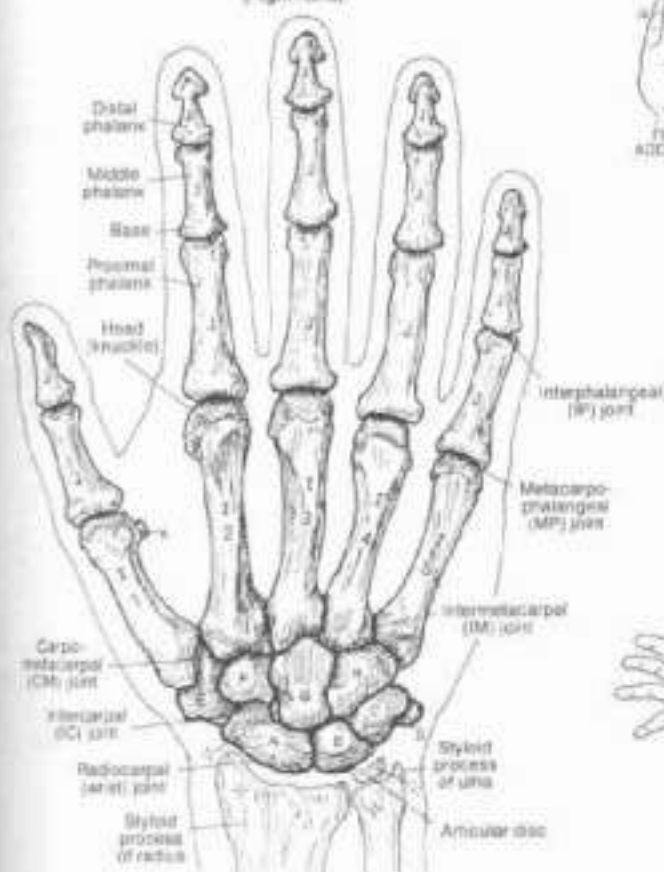which demonstrate movements at the joints. (2) Color the bones and ligament of the carpal tunnel. You may wish to color those bones in their location in the hand to the left.



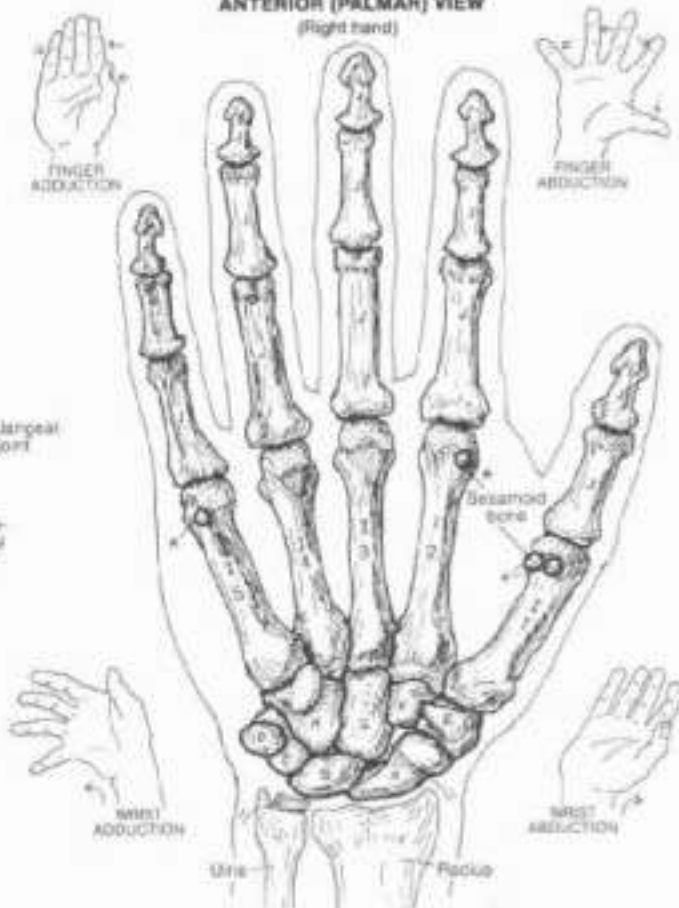### CARPALS (8):

SCAPHOID, LUNATE, TRIQUETRUM, PISIFORM, TRAPEZIUM, TRAPEZOID, CAPITATE, HAMATE  
 METACARPALS (5), PHALANGES (14)

POSTERIOR (DORSAL) VIEW  
 (Right hand)



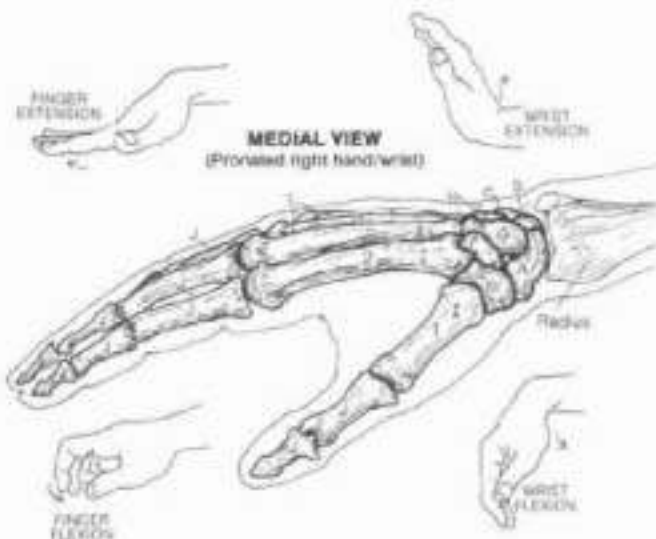
ANTERIOR (PALMAR) VIEW  
 (Right hand)



The hand is a most remarkable, highly evolved, mechanical device. Movement of the hand and wrist is made possible by the architecture of the joints among the bones. The wrist joint is formed by the distal articular surface of the radius and the distal surface of the articular disc (just distal to the ulna) with the proximal articular surface of the scaphoid, lunate, and triquetrum bones. Forces transmitted from a fall on the hand to the wrist pass largely through the scaphoid, lunate, and radius; this fractures of the scaphoid and distal radius are common.

Crossing the wrist bones between the hook of the hamate/pisiform and the tubercle of the trapezium/scaphoid bones, the thin, broad transverse carpal ligament (flexor retinaculum) creates a carpal tunnel through which pass the long flexor tendons to the fingers and thumb as well as the median nerve. Compression of the nerve there can cause numbness in the radial three fingers (thumb, index, middle) and some weakness in the thumb (carpal tunnel syndrome).

Using your own hand, note that the interphalangeal (IP) joints are limited to movements of flexion/extension. The metacarpophalangeal (MP) joints permit the added movements of finger adduction/abduction. Of the carpometacarpal (CM) joints, the 1st (thumb) has exceptional movement (saddle type, synovial), when moving the thumb toward the little finger in an arcing motion, note that the thumb rotates 30°, reflecting medial rotation of the first metacarpal on the trapezium.

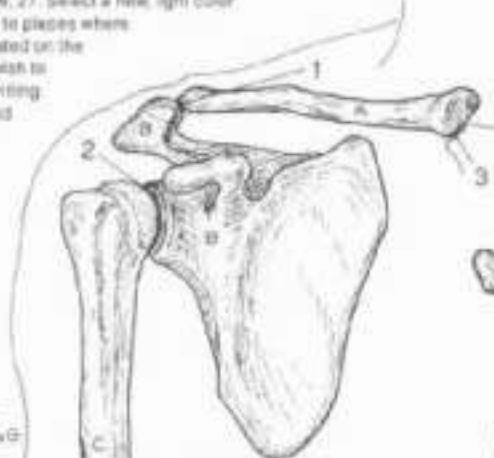

## II. SKELETAL SYSTEM / UPPER LIMB

### BONES IN REVIEW

On for all of these bones, except the carpus (F), use the same colors as used for them on Plates 25, 26, 27. Select a new, light color for (1) Color the arrows pointing to places where these bones can be seen or palpated on the surface of the body. (2) You may wish to use your knowledge of joints by writing for names in the spaces provided below. The answers are listed in the Appendix.

**CLAVICLE,**  
**SCAPULA,**  
**HUMERUS,**  
**ULNA,**  
**RADIUS,**  
**CARPALS,**  
**METACARPAL,**  
**PHALANX.**



**ANTERIOR VIEW**  
(Right upper limb)

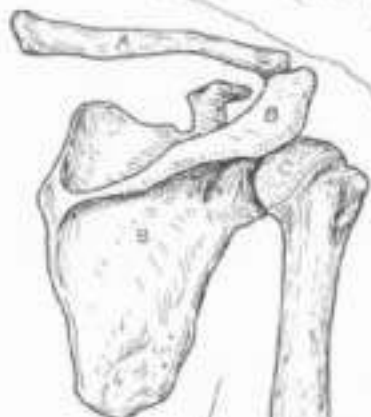**REVIEW OF JOINTS.**

- 1 \_\_\_\_\_
- 2 \_\_\_\_\_
- 3 \_\_\_\_\_
- 4 \_\_\_\_\_
- 5 \_\_\_\_\_

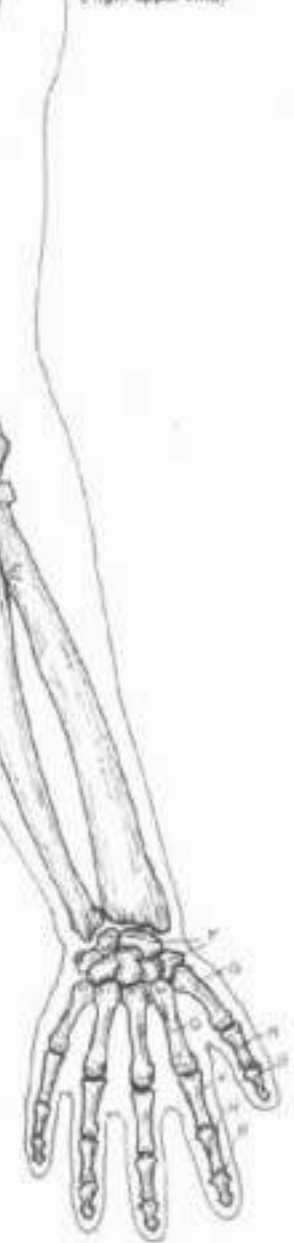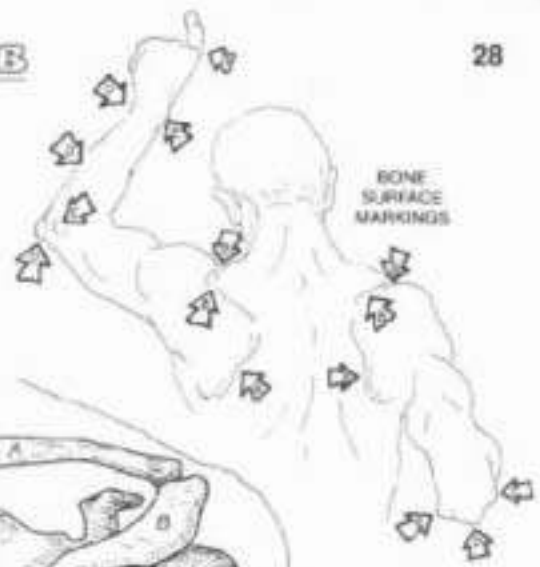
The upper limb is remarkable for its mobility. The mechanism for this begins with the scapula which is dynamically tethered by muscle to the posterior thoracic wall. On yourself, reach over your shoulder to palpate the scapular spine and acromion (recall Plate 25). Looking into a mirror over your shoulder, move your shoulders up and down, wrap your arms around yourself and stretch them out, reach upward then downward to see the scapula move.

The humerus can be palpated easily just distal to the shoulder or down to the elbow. There the medial and lateral epicondyles, as well as the olecranon, can be felt. Can you feel the ulnar nerve under the medial epicondyle? Feel hard enough and it might "speak" to you, all the way down to your little finger! Starting with that little finger and working to the thumb and up, move each joint of the upper limb that you can, identify it, and test its range of motion.

- 6 \_\_\_\_\_
- 7 \_\_\_\_\_
- 8 \_\_\_\_\_
- 9 \_\_\_\_\_
- 10 \_\_\_\_\_
- 11 \_\_\_\_\_
- 12 \_\_\_\_\_
- 13 \_\_\_\_\_



**POSTERIOR VIEW**  
(Right upper limb)



(See appendix for answers)

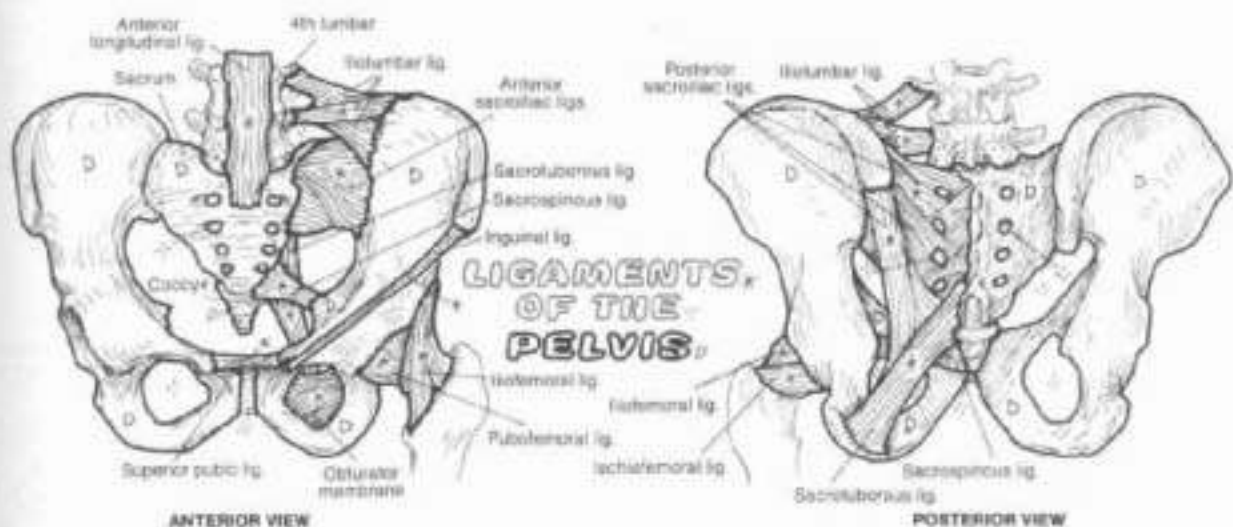
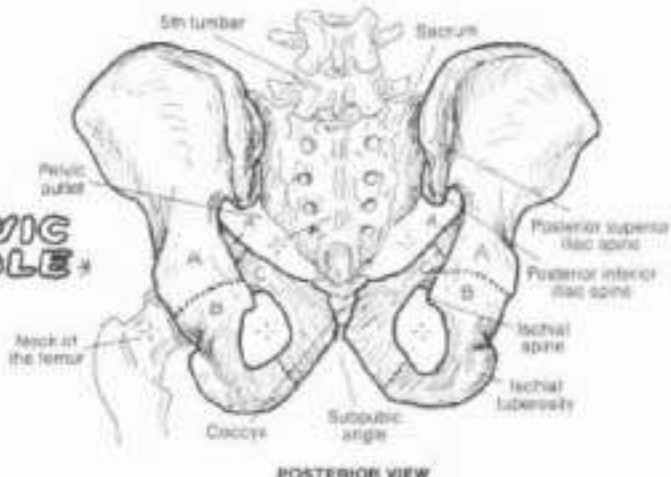
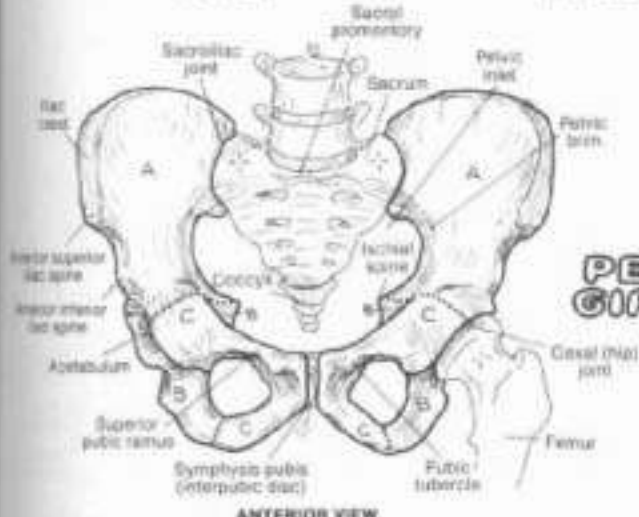
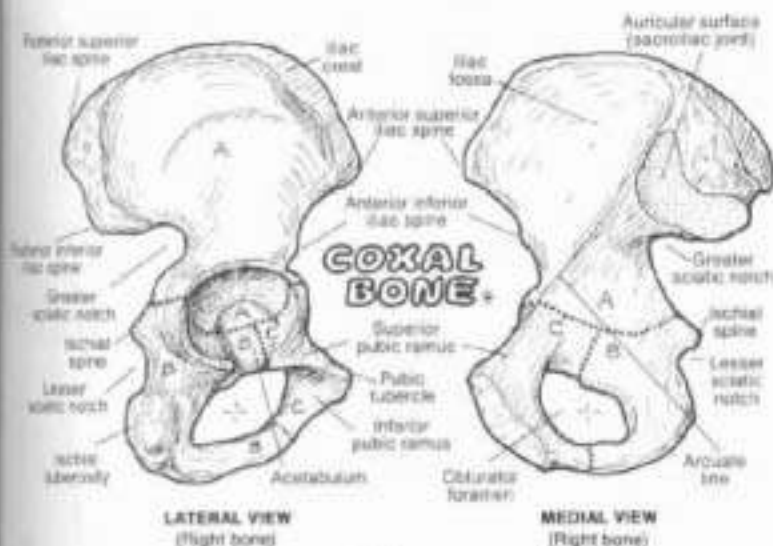
COXAL BONE, PELVIC GIRDLE, & PELVIS

**ILIUM**  
**ISCHIUM**  
**PUBIS:**

CA: (1) Color the two views of the coxal bone with light colors. Then color the views of the pelvic girdle. (2) Use a new color for bones of the pelvis (D) which includes the sacrum and coccyx. Then color the site ligaments, and all the ligaments a light gray color.

The coxal bone (hip bone, innominate bone, or coxa) consists of three fused bones in the adult: the ilium, the ischium, and pubis. The paired coxal bones constitute the pelvic girdle. The two somewhat-twisted coxal bones form a weightbearing arch with the sacrum and the femora (thigh) bones, accommodating the body weight and forces imposed vertically up from the feet. The two hip bones and the sacrum constitute the pelvis. The pelvic inlet (superior pelvic aperture, from sacral promontory around the arcuate line at the pelvic brim) separates the true (lesser) pelvis below from the false (greater) pelvis above. The pelvic outlet (inferior pelvic aperture) is bound by the same structures as the perineum (see next plate).

The sacroiliac joint is a movable, partly synovial, partly fibrocartilaginous joint. The articular surfaces are flat but roughened. Note the larger posterior sacroiliac ligaments (compared to the anterior ligaments); they resist downward displacement of the sacrum. The sacrotuberous and sacrotuberous ligaments secure the apex of the sacrum to the pelvic girdle, resisting the effects of weightbearing and gravity on the sacroiliac joint. Still, sacroiliac dysfunction is common. The lumbosacral ligaments are often involved in postural low back pain. The symphysis pubis (pubic symphysis, interpubic joint) is a partly movable, cartilaginous joint composed of a fibrocartilaginous disc interposed between cartilaginous articular surfaces.

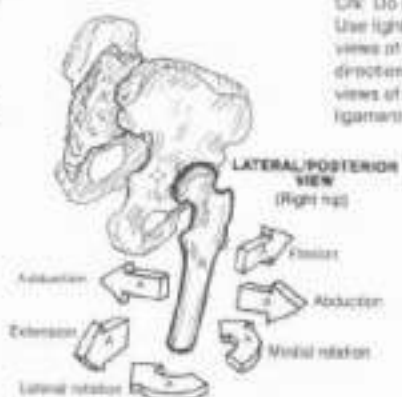
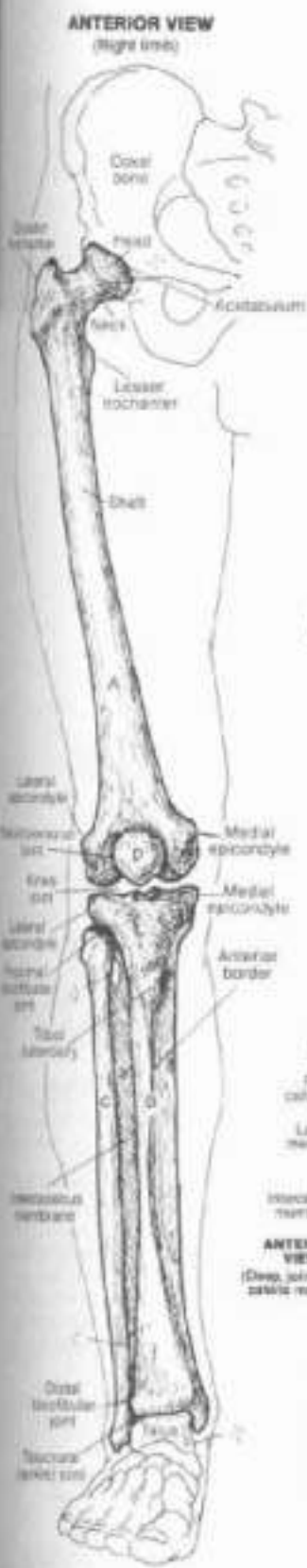



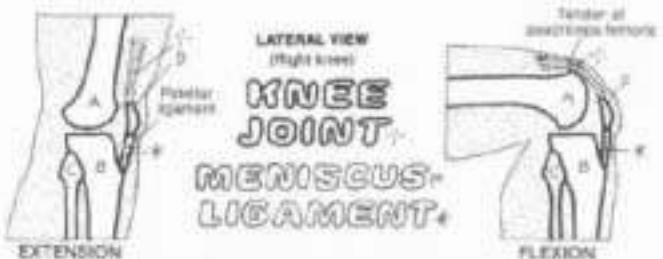
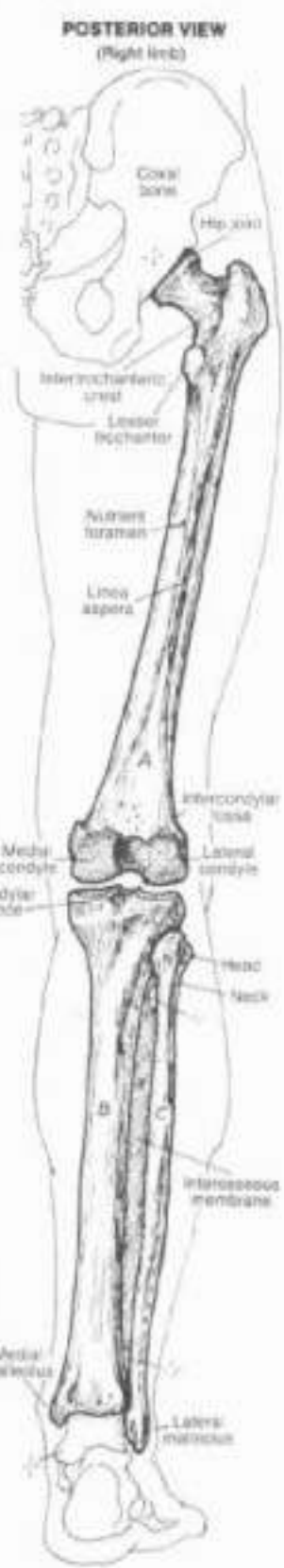**THIGH & LEG BONES**

**FEMUR. TIBIA.**  
**FIBULA.**  
**PATELLA.**

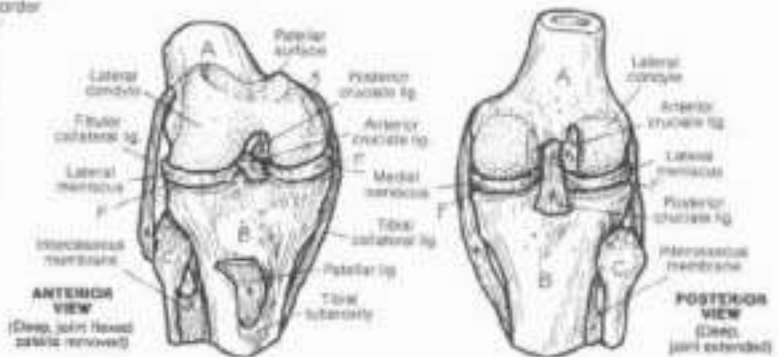
OK! Do not use the color used for the item on Page 29. Use light colors and a bright color for F. (1) Color the two large views of the lower limb. (2) Next color the femur and the six directional arrows for the hip joint. (3) Color the extension/flexion views of the knee joint. (4) Color the two views of the major ligaments and the menisci of the knee joint.



The hip (coxal) joint (multiaxial, ball and socket synovial joint) is concerned with the transmission of considerable weightbearing forces; the head of the femur is particularly subject to pathologic changes with any significant alteration of blood supply (avascular necrosis). The greater trochanter is the site of attachment for several important muscles crossing the hip joint.



The knee (genual) joint consists of two condylar-type, synovial (tibiofemoral) joints between the condyles of the femur and the flat, plateau-like articular surfaces on the condyles of the tibia. The principal movements at those joints are flexion and extension. The knee joint includes the saddle-type synovial (patellofemoral) joint between the patella and femur. The deep surface of the patella is cartilaginous and exhibits medial and lateral facets (note patellar surface of the femur). Premature wear of the patellar cartilage is common (chondromalacia patellae). The patella is a sesamoid bone which develops in the tendon of the quadriceps femoris muscle; as such, it relieves the stress imposed on that tendon during knee movements.



The stability of the knee joint comes from ligaments and the muscles crossing the joint. The collateral ligaments resist sideward displacement and rotation. The cruciate (crossing) ligaments resist hyperextension (anterior cruciate) and hyperflexion (posterior cruciate) of the joint. The C-shaped menisci (the medial larger than the lateral) resist the articulating surfaces of the tibial condyles. Often torn by misuse of the knee joints (rotation and adduction/abduction with weightbearing), the menisci can often be repaired by arthroscopy.

# II. SKELETAL SYSTEM / LOWER LIMB

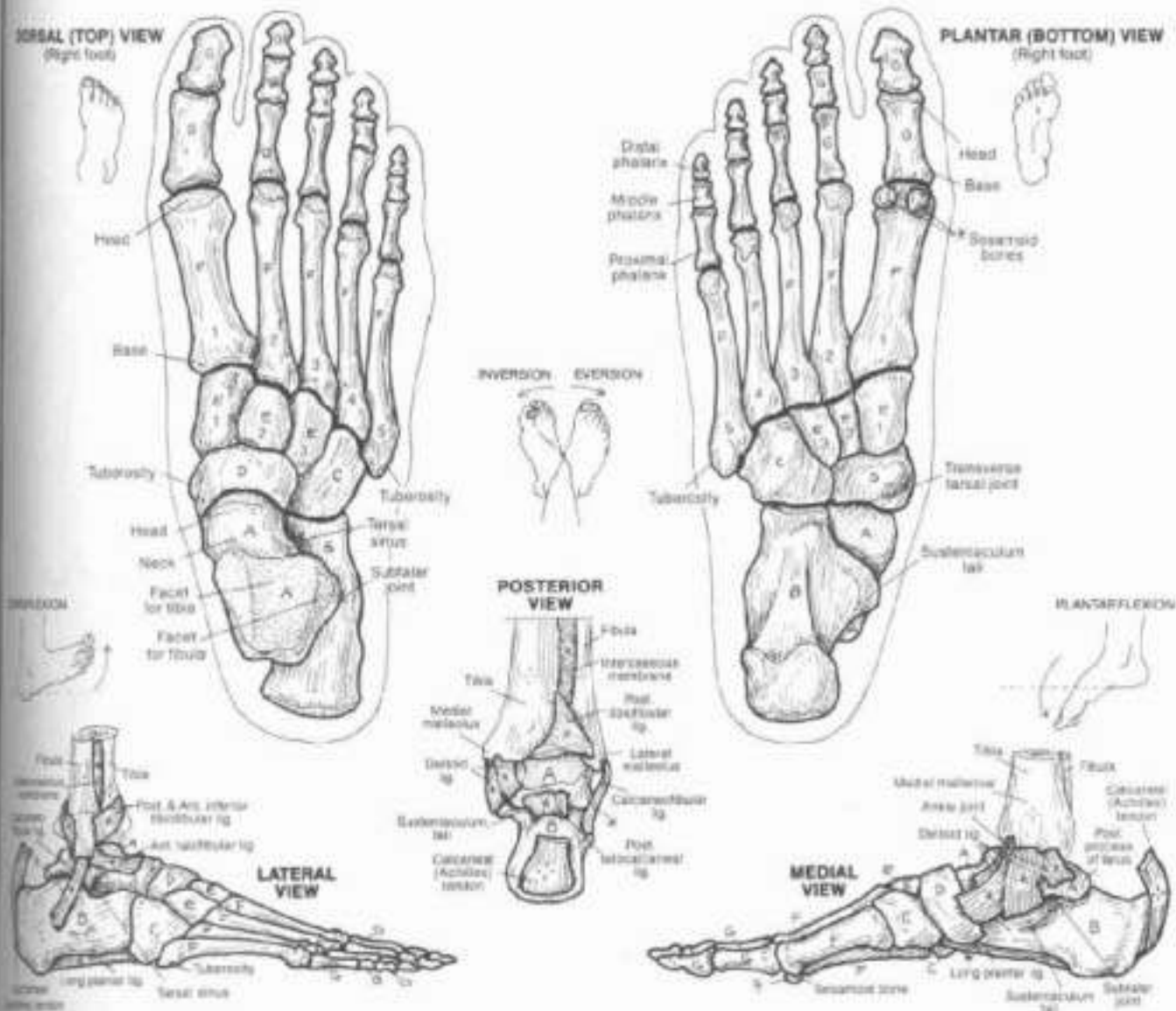
## ANKLE & FOOT BONES

**TARSALS: (7).**

**TALUS, CALCANEUS, CUBOID, NAVICULAR, CUNEIFORMS (3).**

**METATARSALS (5), PHALANGES (14), LIGAMENTS.**

DN: Use different colors from those used for the hum on Plate 29 and for the femur, tibia, fibula, and patella on Plate 30. (1) Begin with the talus (A); color that bone wherever it appears on the plate. Follow that procedure with each of the other bones. (2) Color gray all of the ligaments.



The foot is a mobile, weightbearing structure. The ankle joint (hinge-type synovial joint) between tibia, fibula, and the talus forms a mortise, permitting all flexor (plantar flexion) and extension (dorsiflexion) bars. With excessive motion of this joint, characteristic fractures and torn ligaments occur. The foot can adjust to walking/running on tilted surfaces by virtue of the subtle (talocalcaneal) and transverse tarsal (talocalcaneonavicular and calcaneocuboid) joints. Here inversion and eversion movements occur. The sole has strong medial (ligamentous) and weaker lateral

ligamentous support. The relatively high frequency of inversion sprains (tearing the lateral ligaments) over eversion sprains seems to reflect this fact. The bony architecture of the foot includes a number of arches that are reinforced and maintained by ligaments and influenced by muscles. The medial longitudinal arch transmits the force of body weight to the ground when standing and to the great toe in locomotion, creating a giant lever that gives spring to the gait. Both longitudinal arches function in absorbing shock loads and balancing the body.

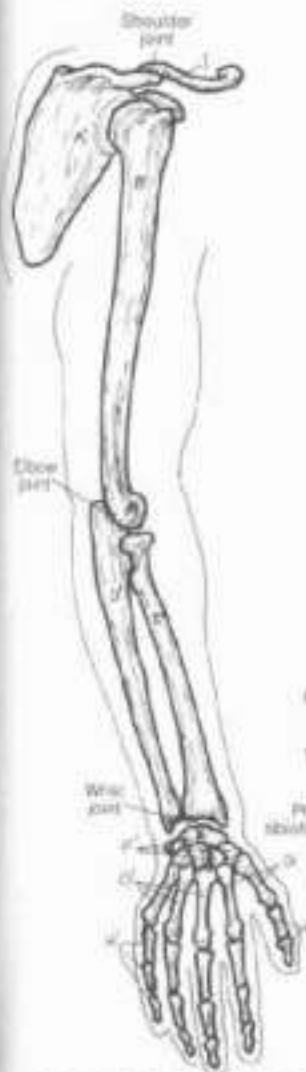
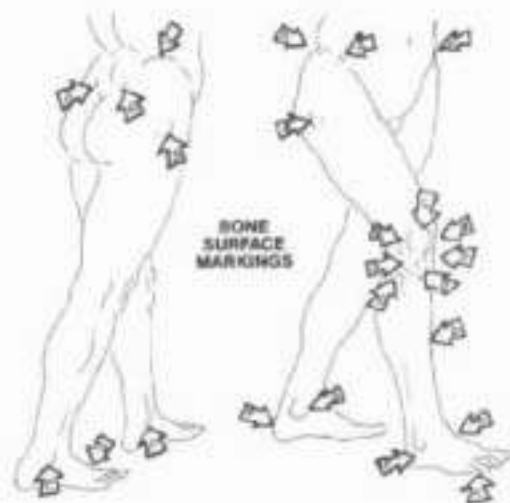
# III. SKELETAL SYSTEM/LOWER LIMB

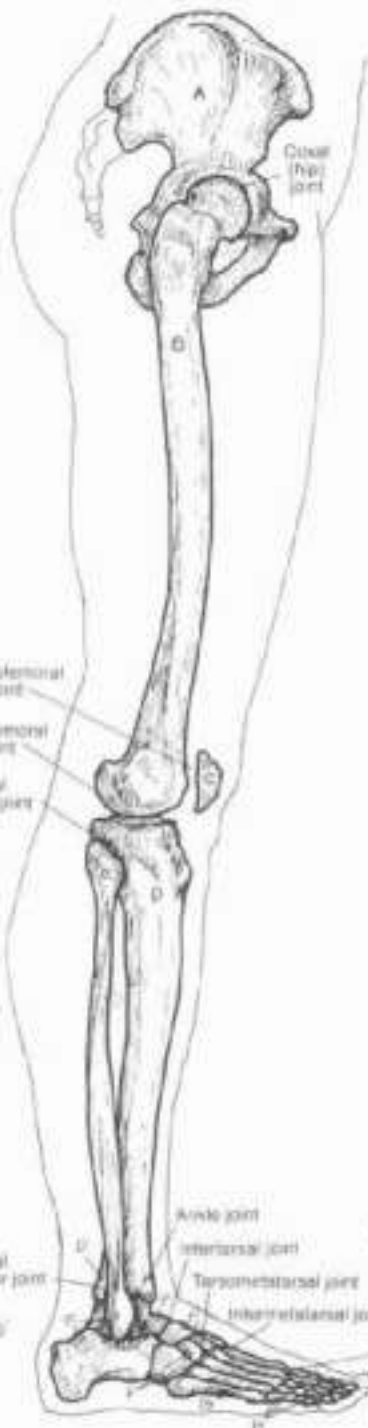## BONES IN REVIEW

CA: Use the same colors for these bones that you used for them on Plates 29-31. In the case of the coxal bone (A), use the color given to the ilium on Plate 29; for the tarsal bones (F), use any one of the tarsal colors; (1) Color the bones of the lower limb, their surface markings, and the corresponding bones on the hind limb of the dog; (2) Color the names and bones of the upper limb and the forelimb of the dog. The cavities of the dog is not shown in this view.

**LOWER LIMB:**  
**COXAL,**  
**FEMUR,**  
**PATELLA,**  
**TIBIA,**  
**FIBULA,**  
**TARSAL,**  
**METATARSAL,**  
**PHALANX.**

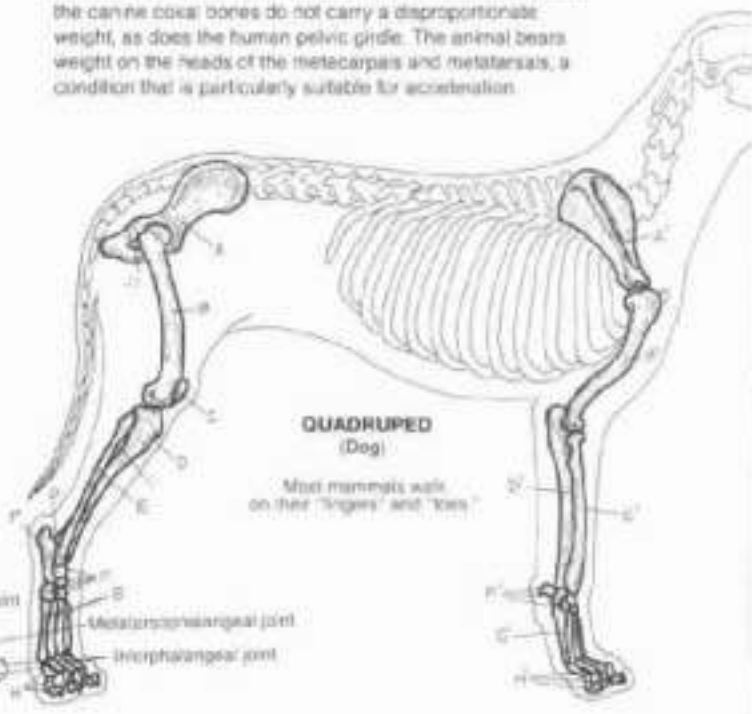


**UPPER LIMB:**  
**CLAVICLE,**  
**SCAPULA,**  
**HUMERUS,**  
**ULNA,**  
**RADIUS,**  
**CARPAL,**  
**METACARPAL,**  
**PHALANX.**



The structure of a part reflects an adaptation for function. The truth of this statement is borne out in comparing the bones of the upper and lower limbs in a biped (human) with those of a quadruped. The pectoral girdle provides a basis for mobility; the more sturdy pelvic girdle provides stability in both locomotion and weight bearing. The limb bones of the lower limb are large and solid, consistent with weight-bearing; the related joints are structurally secure, except the knee, which gives up stability for flexibility. In the upper limb, the bones are lighter, and the joints are more flexible and capable of greater ranges of motion (compare shoulder with hip, elbow with knee, wrist with ankle). Although forearm and leg each have two bones, there is little functional correlation between those pairs of bones. The foot is clearly adapted for locomotion and weight bearing; the hand (especially the thumb) for mobility and dexterity.

The quadruped (in this case, the domestic dog) uses both forelimbs and hindlimbs for supporting body weight and locomotion. The girdle (coxal/scapular) bones are adapted for locomotion, and are not as differentiated structurally or functionally as they are in humans. The canine scapula has much less scapulohumeral motion than the human scapula; the canine coxal bones do not carry a disproportionate weight, as does the human pelvic girdle. The animal bears weight on the heads of the metacarpals and metatarsals, a condition that is particularly suitable for acceleration.





# IV. ARTICULAR SYSTEM

## CLASSIFICATION OF JOINTS

Bones are connected at joints (articulations), and all bone movements occur at joints. Joints are structurally classified as fibrous, cartilaginous, or synovial. They are functionally classified as immovable, partly movable, or freely movable. The most secure joints are immovable; the most vulnerable are freely movable. The architecture of freely movable joints determines their directions and ranges of motion.

### FIBROUS JOINT. IMMOVABLE./PARTLY MOVABLE.

Fibrous joints, where bone is connected to bone by fibrous tissue, are immovable or partly movable. Sutures are immovable fibrous joints, so are teeth and their sockets. Syndesmoses, here represented by the interosseous ligament of the forearm, are partly movable fibrous joints.

### CARTILAGINOUS JOINT. IMMOVABLE./PARTLY MOVABLE.

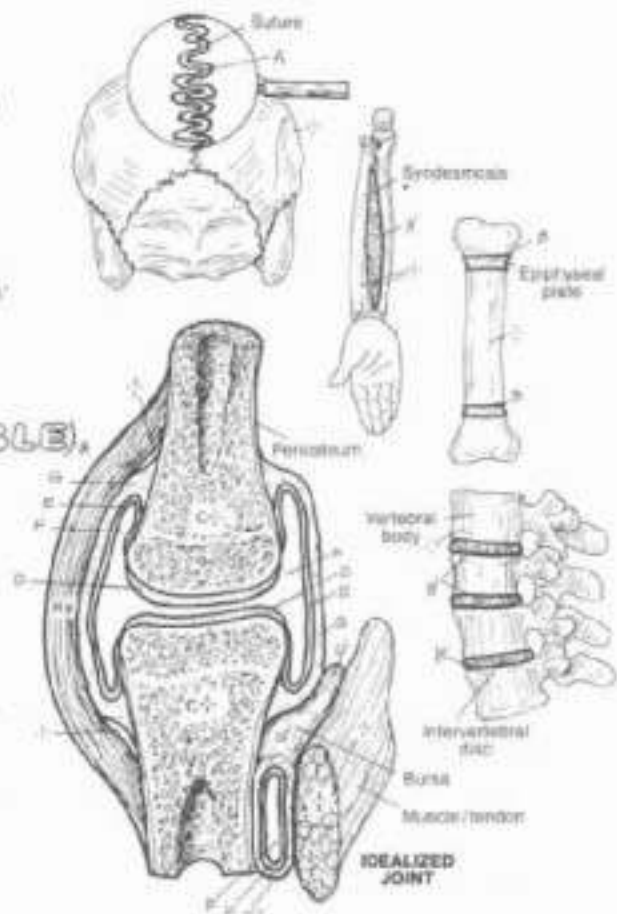
Cartilaginous joints, where bone is connected to bone by cartilaginous or fibrocartilaginous tissues, are immovable or partly movable. The epiphyseal growth plates are immovable cartilaginous joints, replaced by bone at skeletal maturity. The intervertebral discs are partly movable fibrocartilaginous joints.

### SYNOVIAL JOINT (FREELY MOVABLE).

- ARTICULATING BONES.
- ARTICULAR CARTILAGE.
- SYNOVIAL MEMBRANE.
- SYNOVIAL CAVITY FLUID.
- JOINT CAPSULE.
- BURSA CAPSULE.
- COLLATERAL LIGAMENT.

Synovial joints are all freely movable within the limitations of the bony architecture. Articular bones are capped with articular cartilage at the joint interface. The joint cavity is lined internally with vascular synovial membrane (except over the articular cartilage) and secretes a nutrient, lubricating synovial fluid. The fibrous, sensitive joint capsule is reinforced by ligaments. A cushion of synovial membrane reinforced by dense irregular connective tissue can be found interposed between bone and a moving structure (tendon, muscle). Such a device (bursa) facilitates friction-free movement.

Color: Use a light blue for D, and dark color for E and gray for F. (1) Do not color the bones in the upper half of the plate. (2) Below, color the grooves pointing to the location of the joints as well as the joint representations.

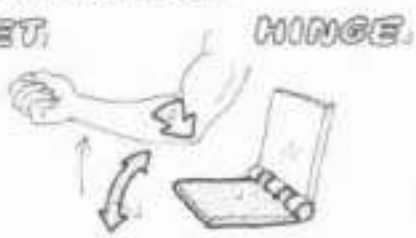

### TYPES OF SYNOVIAL JOINTS:-



#### BALL & SOCKET

The ball and socket joint is best seen at the hip and shoulder joints. Movements in all directions are permitted.



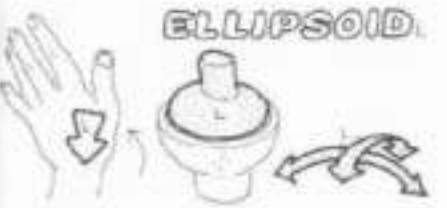#### HINGE

A hinge joint permits movement in only one plane, flexion/extension. It can be seen at the elbow, interphalangeal, and elbow (humero-ulnar) joints.



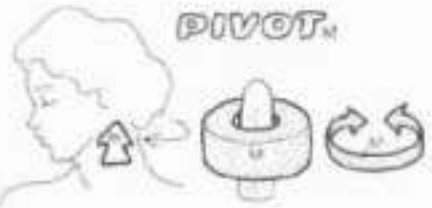
#### SADDLE

The saddle (sellar) joint has two concave surfaces articulating with one another. The carpometacarpal joint of the thumb is the best example of this joint which permits all movements but rotation.



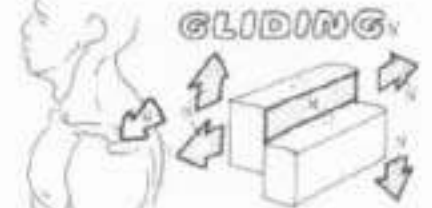
#### ELLIPSOID

The ellipsoid (condyloid, condylar) joint is a reduced ball and socket configuration in which significant rotation is largely excluded, e.g. the bicondylar knees and temporomandibular joints, and radiocarpal (wrist) joints.



#### PIVOT

A ring of bone (C1 vertebra) rotating about an axis of bone (dens/produral process of C2 vertebra) is a pivot joint (atlantoaxial joints). Also the rounded humeral capitulum and the radial head (radioulnar joint).



#### GLIDING

A gliding joint consists of generally flat surfaces gliding across one another during movement, such as the facet joints of the vertebrae, acromioclavicular, and intercarpal/intertarsal joints.

## IV. ARTICULAR SYSTEM

### TERMS OF MOVEMENTS

Or Color the arrows pointing to the joints demonstrating the various movements of body. Note that inversion (I) and eversion (E) occur among bones of the foot, not at the ankle.

**EXTENSION.**  
**DORSIFLEXION.**  
**FLEXION.**  
**PLANTARFLEXION.**  
**ADDUCTION.**  
**ABDUCTION.**  
**CIRCUMDUCTION.**  
**ROTATION.**  
**SUPINATION.**  
**PROMATION.**  
**INVERSION.**  
**EVERSION.**

Movements of bones occur at joints. Terms of movement are therefore applicable to joints, not bones (flexion of the humerus is to bend it). Ranges of motion are limited by the bony architecture of a joint, related ligaments, and the muscles crossing that joint. It is from the anatomical position that specific directions of movement can be clearly delineated and ranges of motion measured.

Extension of a joint is to generally straighten it. In the anatomical position, most joints are in relaxed extension (neutral). In relation to the anatomical position, movements of extension are located in the sagittal plane. Extreme, even abnormal extension is called hyperextension. At the ankle and wrist joints, extension is called dorsiflexion.

Flexion of a joint is to bend it or decrease the angle between the bones of the joint. Movements of flexion are directed in the sagittal plane. At the ankle joint, flexion is also called plantar flexion.

Adduction of a joint moves a bone toward the midline of the body (or in the case of the fingers or toes, toward the midline of the hand or foot). In relation to the anatomical position, movements of adduction are directed medially in the coronal plane.

Abduction of a joint moves a bone away from the midline of the body (or hand or foot). Movements of abduction are directed laterally in the coronal plane.

Circumduction is a circular movement permitted at ball and socket, conyolar, and saddle joints. It consists of the movements of flexion, abduction, extension, and adduction performed in sequence.

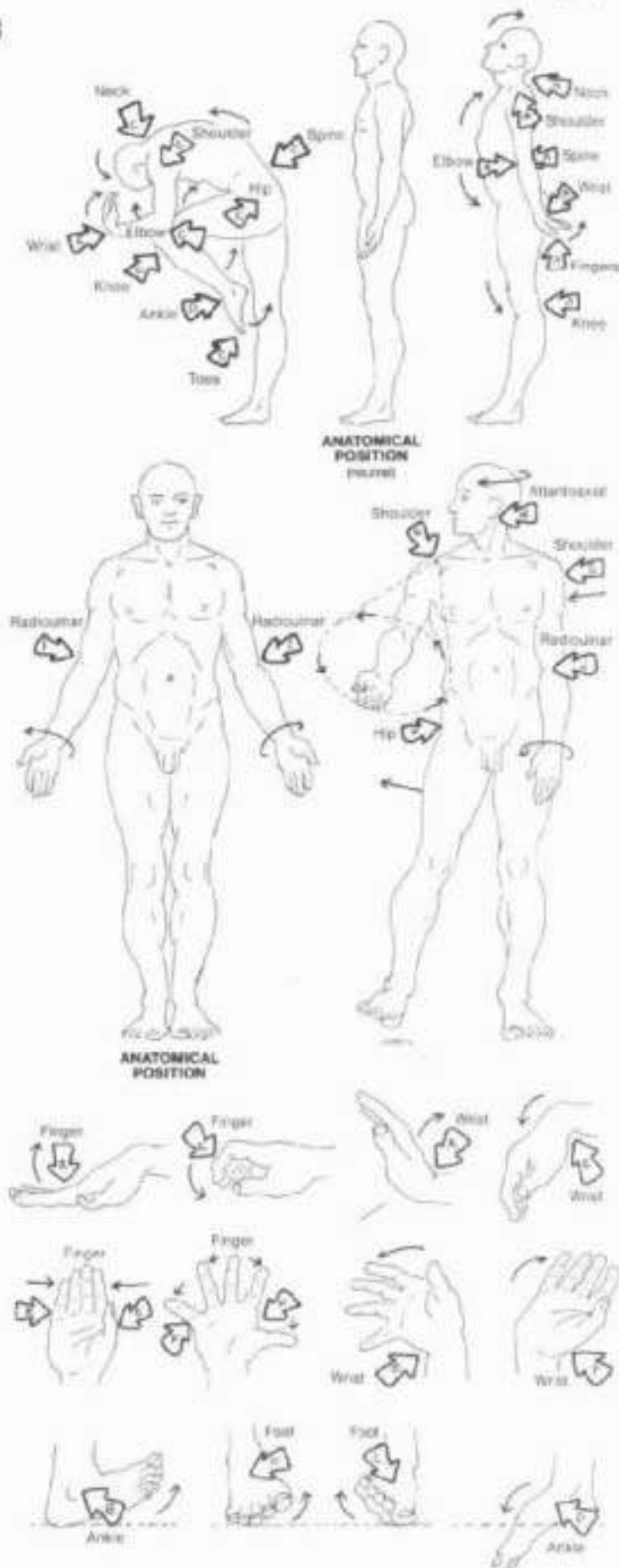
Rotation of a joint is to turn the moving bone about its axis. Rotation toward the body is internal or medial rotation; rotation away from the body is external or lateral rotation.

Supination is an external rotation of the radiohumeral joint in the foot, it is the combined movements of inversion, adduction around a vertical axis, and plantar flexion.

Pronation is an internal rotation of the radiohumeral joint in the foot, it is the combined movements of eversion, abduction around a vertical axis, and dorsiflexion. The joints involved in both supination and pronation are the tarsal and ankle joints.

Inversion turns the sole of the foot inward so that the medial border of the foot is elevated.

Eversion turns the sole of the foot outward so that its lateral border is elevated. Both inversion and eversion occur at subtalar (talocalcaneal) and transverse tarsal joints.



## V. MUSCULAR SYSTEM

### INTRODUCTION

24. Use light colors for A-E. (1) Begin with the muscle belly and tendons in the upper illustration. (2) When coloring the narrow borders of the endomysium (C) in the enlarged section, it is recommended that you also color over the muscle fiber ends (D) with the very light endomysium color, and then go back over the fiber ends with a darker color (E). Do not color the neurovascular bundle, or the cut ends of blood vessels and capillaries. (3) Color the lower illustration.

**SKELETAL MUSCLE:**  
**BELLY.**  
**FASCIA:**  
**EPIMYSIUM.**  
**PERIMYSIUM.**  
**ENDOMYSIUM.**  
**MUSCLE FIBER CELL.**  
**TENDON.**

A named skeletal muscle (e.g., biceps brachii), surrounded by a layer of deep fascia (epimysium), consists of fascicles or bundles of muscle cells enveloped in thin fibrous tissue (perimysium). Each muscle cell is surrounded by a thin sheath of fibrous tissue (endomysium). Each of these fibrous layers is important to muscle structure and function, providing support for nerves and vessels (neurovascular bundles), ensuring uniform distribution of muscle tension during contraction, and maintaining the elasticity of muscle, permitting it to recoil to its resting length following stretching. It is the merging of these fibrous layers at the ends of the muscle fibers that form the tendons which integrate the muscle to its attachment site(s), such as periosteum or another tendon. Broad, flat tendons are called aponeuroses. The mass of the fascia-enveloped contractile cells is called the belly of the muscle. It is the muscle belly that shortens during muscle contraction. The belly may be shaped one of a number of ways depending on its tendinous arrangement and attachments. Skeletal muscles are named in relation to their attachments (e.g., hyoglossus), shape (e.g., trapezius), number of heads (e.g., quadriceps), function (e.g., adductor magnus), and position (e.g., brachialis).

### MECHANICS OF MOVEMENT:

**FULCRUM: JOINT.**  
**EFFORT: (MUSCLE).**  
**RESISTANCE: (WEIGHT).**

#### 1ST CLASS LEVER.

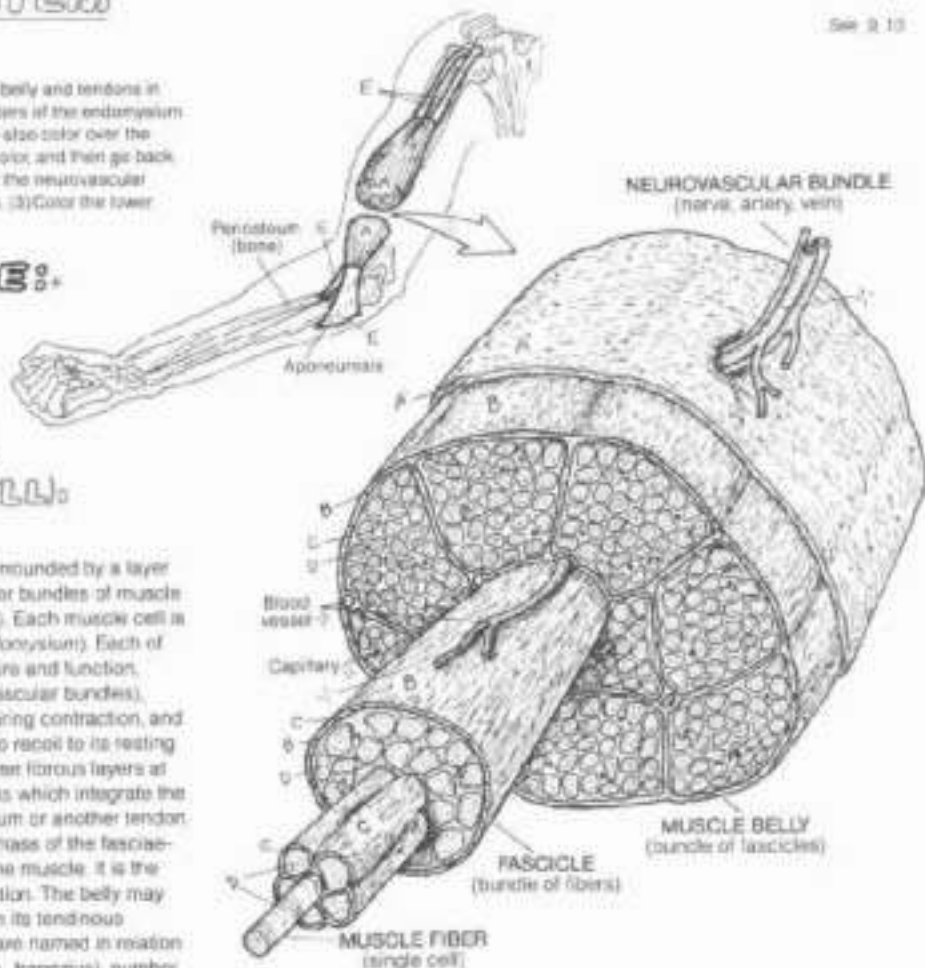
In a 1st class lever, the joint lies between the muscle and the load. This is the most efficient class of lever. By flexing the neck and tilting the head forward and downward, the load (G') is appreciably increased, and the muscular effort (A) to hold that posture may induce muscle pain and stiffness/tightness (overuse).

#### 2ND CLASS LEVER.

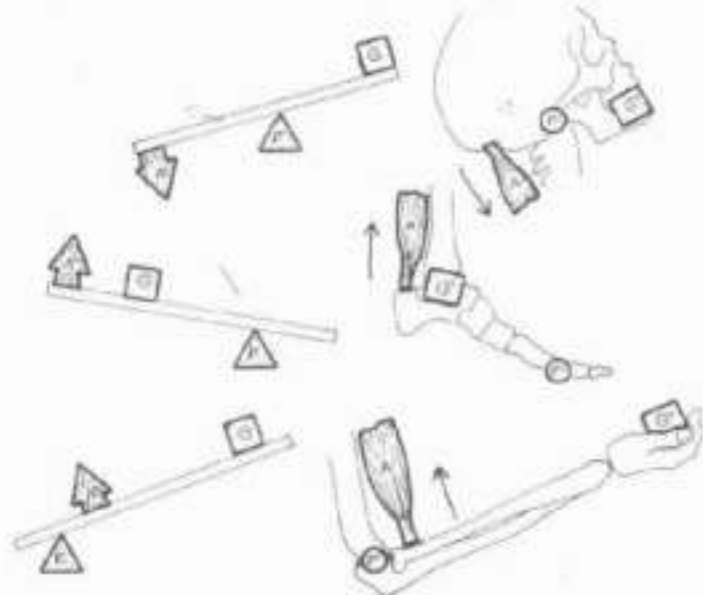
In a 2nd class lever, the load lies between the joint and the pulling muscle. This lever system operates in lifting a wheelbarrow (the wheel is the fulcrum) as well as lifting a 75 kg (165 lb) body onto the metatarsal heads at the metatarsophalangeal joints. This is a relatively easy task for the strong calf (triceps surae) muscles, but try standing on the heads of your middle phalanges (increasing the distance F-G').

#### 3RD CLASS LEVER.

In a 3rd class lever, the muscle lies between the joint and the load and has a poor mechanical advantage here. Consider the difference in muscular effort required to carry a 45 kg (100 lb) bag of cement in your hands with flexed elbows (elbow joint; 3rd class lever) and carrying your 75 kg (165 lb) body on the heads of your metatarsals (2nd class lever at the metatarsophalangeal joints). It is all a matter of leverage.



Skeletal muscles employ simple machines, such as levers, to increase the efficiency of their contractile work about a joint. Mechanically, the degree of muscular effort required to overcome resistance to movement at a joint (fulcrum) depends upon: (1) the force of that resistance (weight, G); (2) the relative distances from the anatomical fulcrum to the anatomical sites of muscular effort (F-A), and the anatomical sites of resistance (F-G'). The position of the joint relative to the site of muscle pull and the site of imposed load determines the class of the lever system in use.





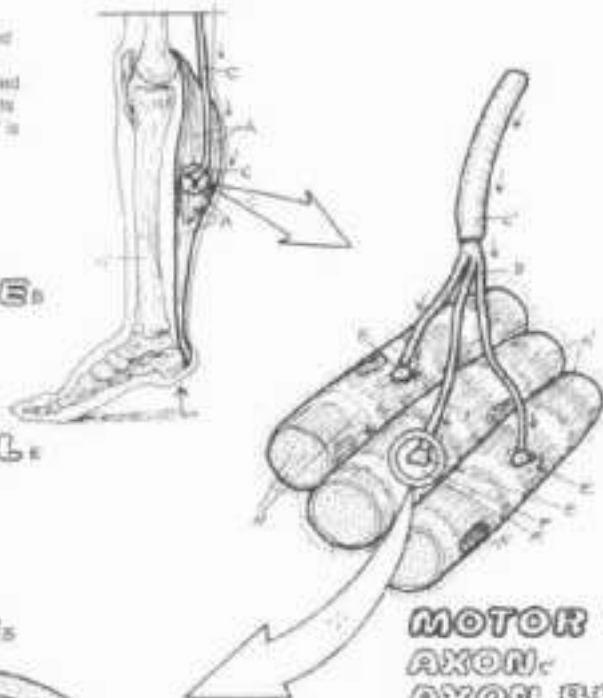
## V. MUSCULAR SYSTEM

### NEUROMUSCULAR JUNCTION / MOTOR UNIT

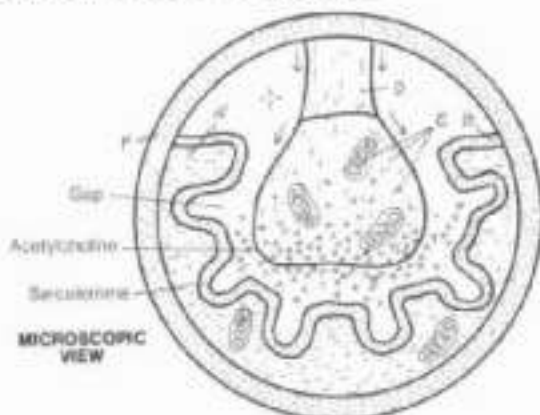
Ch: Use very light colors for A and E, and a dark color for F.

(1) Begin with the skeletal muscle lifting the heel of the foot and complete the motor unit and the enlarged view of the neuromuscular junction. (2) Color carefully the motor units and related files at the bottom of the plate; only the discharging motor units (in dark outline) are to be colored. Note that the word "partial" is not colored under the example of partial contraction.

**SKELETAL MUSCLE:**  
**MUSCLE CELL:**  
**MOTOR END PLATE:**  
**MOTOR NERVE:**  
**AXON:**  
**AXON BRANCH:**  
**AXON TERMINAL:**



**NEUROMUSCULAR JUNCTION:**  
**AXON TERMINAL:**  
**MOTOR END PLATE:**



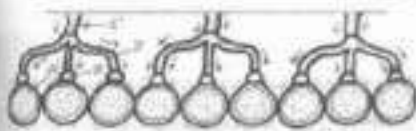
**MOTOR UNIT:**  
**AXON:**  
**AXON BRANCH:**  
**NEUROMUSCULAR JUNCTION:**  
**MUSCLE CELL:**

An axon of a single motor neuron, its axon branches, and the skeletal muscle cells with which they form neuromuscular junctions constitute a motor unit. Within any given skeletal muscle, the number of muscle cells innervated by a single motor neuron largely determines the specificity of contraction of that muscle; the fewer the number of muscle cells in each motor unit, the more selective and refined the degree of contraction of that skeletal muscle.

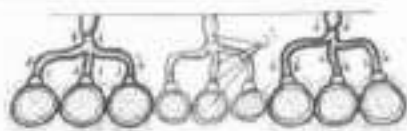
Given the fact of "all or none" contraction by individual skeletal muscle cells, grades of contraction of a skeletal muscle are made possible by activating a number of motor units and not activating others. In maximal contraction of a skeletal muscle, all motor units are discharged. In a partial contraction, only some of the motor units are activated. A resting muscle discharges no motor units. Gluteus maximus consists of skeletal muscle cells having a nerve to muscle ratio of 1:1000 or more. There is no possibility of controlled, refined contractions from this muscle. The facial muscles, on the other hand, have a much lower nerve to muscle ratio, closer to 1:10. Here small numbers of muscle cells can be contracted by implementing one or a few motor units, generating very fine control on the muscular effect (facial expression) desired.

Skeletal muscle consists of innumerable muscle cells (fibers). Skeletal muscle requires an intact nerve (innervation) to shorten (contract). Such a nerve is called a motor nerve, and consists of numerous axons of motor neurons. A motor neuron (recall Plate 11) is dedicated solely to stimulating muscle fibers to contract. Each single muscle cell in a skeletal muscle is innervated by a branch of an axon. The microscopic site at which the axon branch attaches to the skeletal muscle cell is called the neuromuscular junction. Each neuromuscular junction consists of an axon terminal closely applied to an area of convoluted muscle cell sarcolemma called the motor end plate. There is a gap between the two surfaces. When a skeletal muscle cell is about to be stimulated, a chemical neurotransmitter, called acetylcholine, is released by the axon terminal into the gap. The neurotransmitter induces a change in the permeability of the sarcolemma to calcium, which initiates muscle cell contraction. A muscle cell can only contract maximally ("all or none" law).

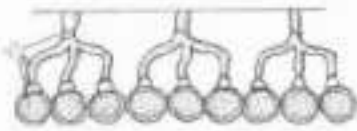
### GRADES OF CONTRACTION:



**MAXIMUM CONTRACTION:**



**PARTIAL CONTRACTION:**



**AT REST:**

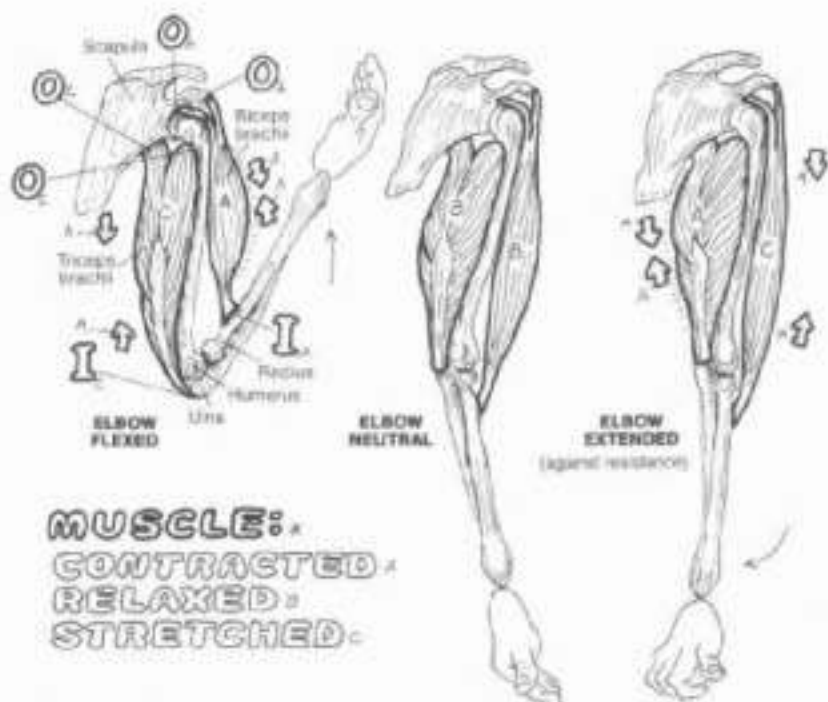
# V. MUSCULAR SYSTEM

## INTEGRATION OF MUSCLE ACTION

OK. Use a bright color for A and a light one for E. (1) Color the start arrows and the large letters of origin (O) and insertion (I) adjacent to the examples of contracted and stretched muscles. (2) In the lower illustration, color the portions of pronator teres and pronator quadratus that are outlined by dotted lines. These parts of the muscles are normally concealed by the radius in its lateral view.

When a skeletal muscle shortens (contracts), a joint is moved, and two bones come closer together, isometric contraction excepted. Muscles never push; they always pull. In any given movement between two bones, one bone is generally fixed, and the other moves. The muscle attachment at the fixed bone is the origin; the attachment at the moving bone is the insertion. In complex movements where it is difficult to identify a "fixed" bone, the origin of the muscle is the more proximal attachment.

When a muscle contracts across a joint, other muscles crossing that joint are affected. No one muscle acts alone in joint movement. In flexion of the elbow joint, for example, biceps brachii (and brachialis, not shown) contract, while triceps brachii is stretched. Conversely, in elbow extension, triceps is contracted, and the biceps/brachialis muscles are stretched. In neutral, all three are relaxed (at rest). Tense (contracted) muscles can often be relaxed by gentle stretching.



### ACTORS IN ELBOW FLEXION WITH SUPINATION vs. PRONATION \*

No muscle acts alone in the movement of a joint. In the movements shown at right, various muscles are functionally integrated in the simple act of lifting an object, with the forearm supinated in the first case, and pronated in the second case.

#### PRIME MOVER (AGONIST) \*

The primary muscle effecting a desired joint movement is called the prime mover (agonist). There may be more than one; in elbow flexion with the forearm supinated, brachialis and biceps brachii are both prime movers; biceps adds significantly to the lifting power because of the added work in supinating the radius during elbow flexion. With the forearm pronated and supination resisted, the biceps loses that supinating power, and brachialis, unaffected by a pronated forearm, becomes the prime mover.

#### ANTAGONIST \*

Muscles which potentially or actually oppose or resist a certain movement are called antagonists. In the lower illustrations, triceps is the antagonist in the act of elbow flexion, even though it is being stretched and is not contracted in the case illustrated.

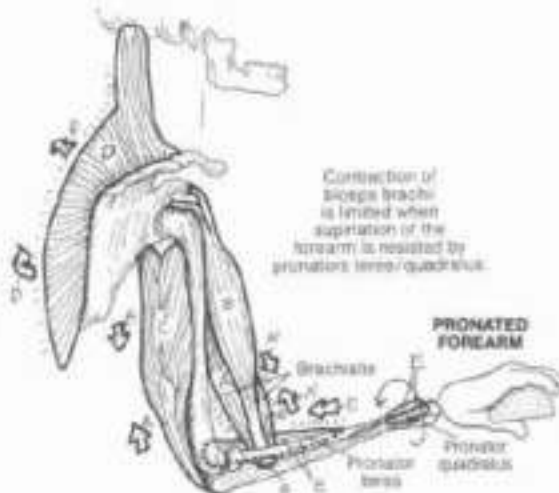
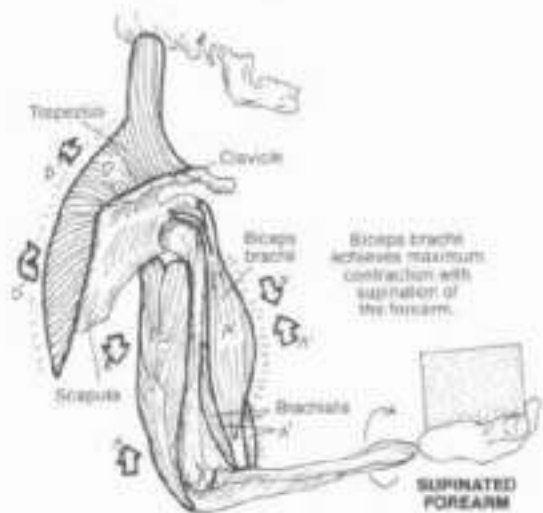
#### FIXATOR \*

Fixator muscles stabilize the more proximal joints during weightbearing functions of the more distal joints. Here the trapezius muscle contracts to stabilize (immobilize) the scapula, creating a rigid platform (the scapula) for operation of the weightbearing, ipsilateral limb.

#### NEUTRALIZER (SYNERGIST) \*

In undertaking a desired and specific movement, undesired movements are resisted by neutralizers (synergists). During flexion of the elbow with a pronated forearm, pronators of the forearm (pronator quadratus, pronator teres) contract to resist or neutralize supination of the forearm. In this action, the pronators are synergistic with the desired movement.

Globally integrated and harmonious muscle functioning makes possible painless, rhythmic, and dynamic movements, best revealed in such activities as dance, sports, and exercise. Joints affected by tense or weak interacting muscles, induced by mechanically disadvantaged posture/gait, can be subject to painful and limited movements.

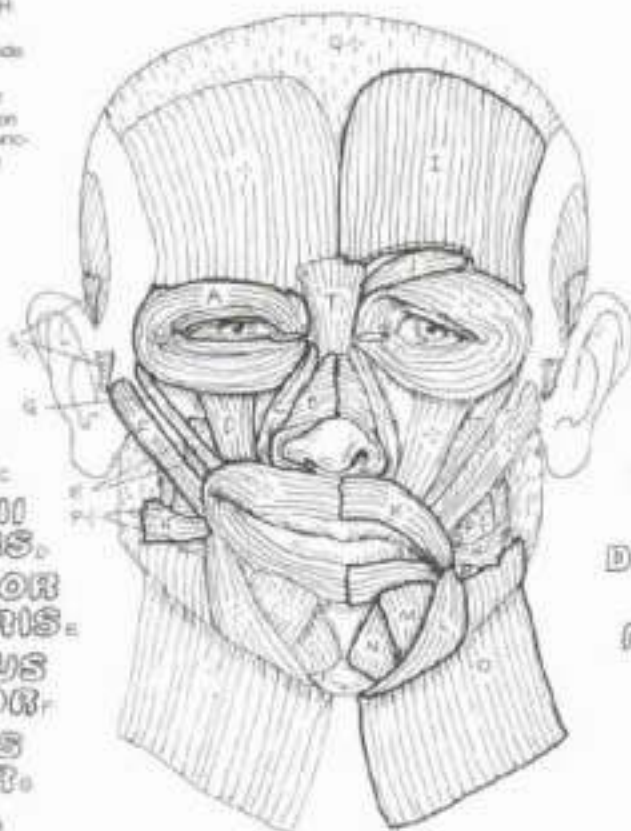


## V. MUSCULAR SYSTEM/HEAD

### MUSCLES OF FACIAL EXPRESSION

CA Use your lightest colors for O and Q.  
Use warm and cheerful colors for the muscles producing a smile (A-H). Color the muscles affecting sadness (I-O) with greens, blues, and grays. (1) Begin with the smiling side, and color only the muscles identified by letters A-H. Use color these muscles in the profile view below. (2) Repeat the process with the sad side, but a portion of frontalis (I) has been cut away to reveal procerus (J). (3) Color the sites at the bottom and the related muscles on the lower view. Include the portions of the auricular muscles that disappear beneath the ear.

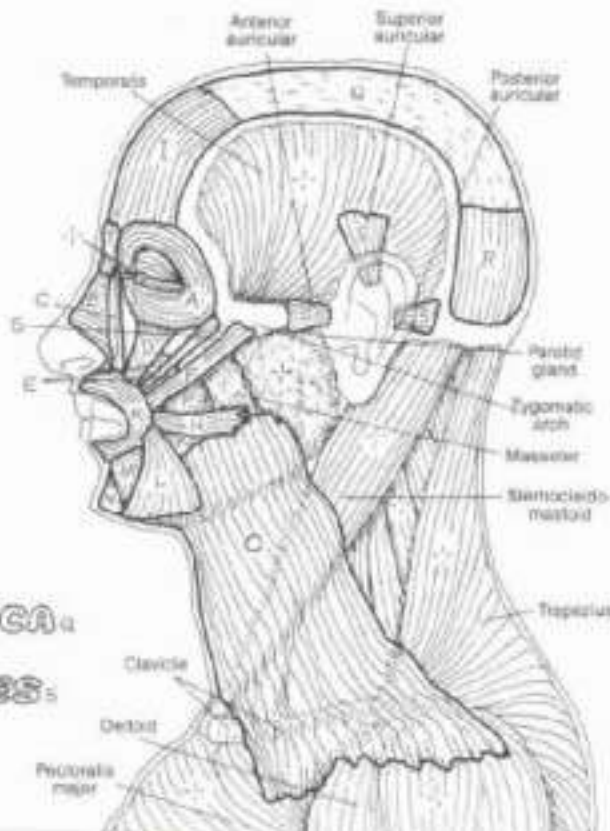
**ORBICULARIS OCULI.**  
**NASALIS.**  
**LEVATOR LABII SUPERIORIS.**  
**ALAEQUE NASI.**  
**LEVATOR LABII SUPERIORIS.**  
**LEVATOR ANGULI ORIS.**  
**ZYGOMATICUS MAJOR.**  
**ZYGOMATICUS MINOR.**  
**RISORIUS.**



**FRONTALIS:**  
**CONTRATOR SUPERCILII.**  
**ORBICULARIS ORIS.**  
**DEPRESSOR ANGULI ORIS.**  
**DEPRESSOR LABII INFERIORIS.**  
**MENTALIS.**  
**PLATYSMA.**

The muscles of facial expression are generally thin, flat bands arising from a facial bone or cartilage and inserting into the dermis of the skin or the fibrous tissue enveloping the sphincter muscles of the orbit or mouth. These muscles are generally arranged into the following regional groups: (1) the epicranial group (occipitofrontalis moving the scalp); (2) the orbital group (orbicularis oculi, corrugator supercilii); (3) the nasal group (nasalis, procerus); (4) the oral group (orbicularis oris, zygomaticus major and minor, the levators and the depressors of the lips and angles of the mouth, risorius, buccinator, and part of platysma); and (5) the group moving the ear (auricular muscles). The general function of each of these muscles is to move the skin wherever they insert. As you color each muscle, try contacting it on your self while looking into a mirror, and see what develops. Orbicularis oculi and oris are sphincter muscles, tending to close the skin over the eyelids and tighten the lips, respectively. Contractions of the cheek muscle, buccinator, makes possible rapid changes in volume of the oral cavity, as in playing a trumpet or squirting water. The nasalis muscle has both compressor and dilator parts which influence the size of the anterior nasal opening.

**GALEA APONEUROTICA.**  
**OCCIPITALIS:**  
**AURICULAR MUSCLES:**  
**PROGERUS.**  
**BUCCINATOR.**



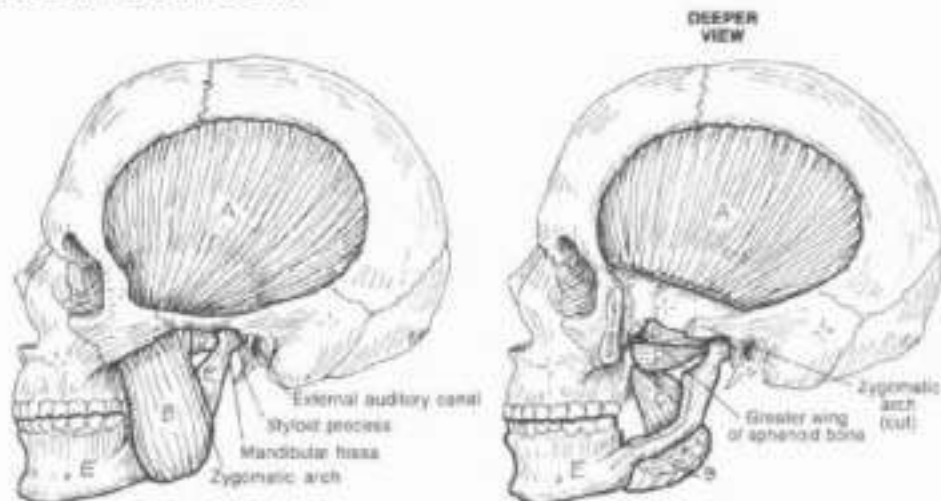


# V. MUSCULAR SYSTEM/HEAD

## MUSCLES OF MASTICATION

Use a bright, yellowish color for the mandible (M) which appears in all the illustrations.  
 (1) Begin at the upper left and work your way through the various movements of the mandible.  
 (2) In coloring the temporomandibular joint, note the superior and inferior joint spaces (S, I) as colored black.

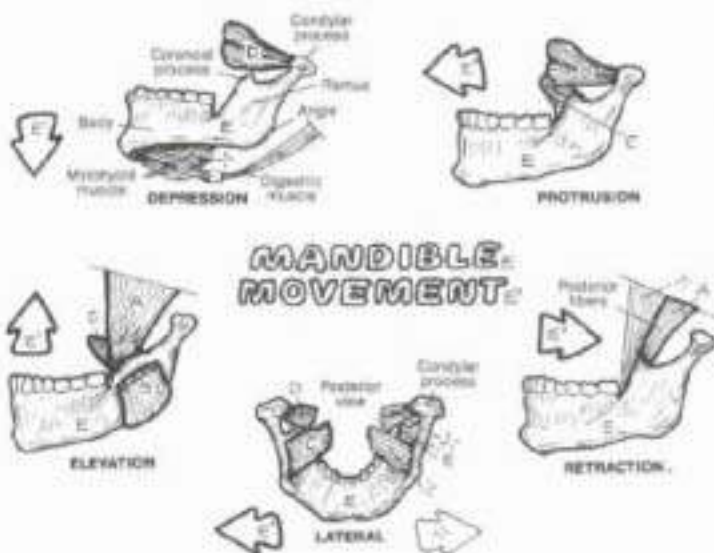
**MUSCLES:**  
**TEMPORALIS,**  
**MASSETER,**  
**MEDIAL**  
**PTERYGOID,**  
**LATERAL**  
**PTERYGOID.**



The act of chewing is called mastication. The muscles of mastication move the temporomandibular joint and are largely responsible for elevation, depression, protrusion, retraction, and lateral motion of the mandible. These muscles function bilaterally to effect movements of the single bone (mandible) at two joints.

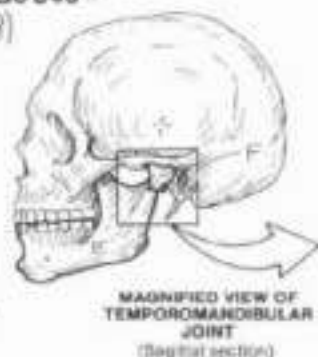
The temporalis and masseter muscles are often contracted unconsciously (clenching teeth) when stressed, giving rise to potentially severe bilateral and presauricular headaches. The muscles can easily be palpated when contracted.

The medial and lateral pterygoids are in the infratemporal fossa and cannot be palpated. In the lowest drawing at right, note how the two heads of the lateral pterygoid insert on the anterior part of the articular disc. During mouth opening, the muscle pulls the articular disc forward as the mandibular head rotates forward in the fossa. On mouth closing, the muscle relaxes, permitting the disc to move posteriorly. Rapid, forced jaw opening may disrupt the articular disc.

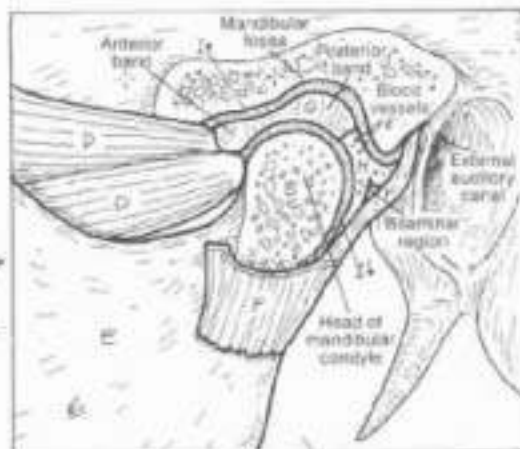


### TEMPOROMANDIBULAR (CRANIOMANDIBULAR) JOINT:

**JOINT CAPSULE,**  
**ARTICULAR DISC**  
**(MENISCUS),**  
**RETRODISCAL PAD,**  
**SUP. JOINT SPACE,**  
**INF. JOINT SPACE.**



The mandible has two condylar processes (left and right) each of which articulates with a mandibular fossa of the temporal bone. Two temporomandibular joints are connected by one bone, hence the alternate term, craniomandibular joint. Intervening between the mandibular fossa and the head of the condylar process is a fibrocartilaginous, movable oval plate called the articular disc or meniscus. The disc embodies two (anterior and posterior) avascular fibrous bands, their long axes directed in the coronal plane. The two bands are separated by a thinner intermediate zone. With closed mouth, the mandibular head rests against the posterior band; with full opening (35-50 mm between upper and lower incisors), the head lies against the anterior band. Posterior to the disc is the retrodisical pad, a



two-layered (biamniar) region of loose fibrous, vascular, sensitive connective tissue from which the disc gets its nutrition. Medially and laterally, the disc is attached to the condyle of the mandible. The mandibular head, the disc, and the fossa are enclosed by a joint capsule. The disc divides the joint space into two compartments, one above and one below the disc. The disc may be structurally incomplete from birth, even perforated; it frequently tends to fray with aging. Disc displacement may be responsible for clicking and limited range of jaw motion.

# V. MUSCULAR SYSTEM/NECK

## ANTERIOR & LATERAL MUSCLES

ON: Except for B and E, use your lightest colors throughout the plate. (1) Begin with the diagrams of the triangles of the neck and the sternocleidomastoid (A, B, C). Color over all the muscles within the triangles. (2) Then work top and bottom illustrations simultaneously, coloring each muscle in as many views as you can find it. Note the relationship between muscle name and attachment.

The neck is a complex tubular region of muscles, viscera, vessels, and nerves surrounding the cervical vertebrae. The muscles of the neck are arranged in superficial and deep groups. Here we concentrate on superficial muscles. The superficial posterior and posterolateral muscle of the neck is trapezius (Plate 46). The deep posterior muscles are covered in Plate 41. The most superficial anterior muscle of the neck is platysma (Plate 38). The anterior and lateral muscle groups are divided into triangular areas by the sternocleidomastoid muscle.

### ANTERIOR TRIANGLE

#### SUPRAHYOID MUSCLES:

STYLOHYOID, DIGASTRIC,  
MYLOHYOID, HYOGLOSSUS,  
GENIOHYOID

#### HYOID BONE

#### INFRAHYOID MUSCLES:

STERNOHYOID, OMOHYOID,  
THYROHYOID, STERNOHYOID

The anterior region of the neck is divided in the midline, each half forms an anterior triangle. The borders of the anterior triangle of superficial neck muscles are clearly illustrated. The hyoid bone, suspended from the styloid processes of the skull by the stylohyoid ligaments, divides each anterior triangle into upper suprahyoid and lower infrahyoid regions.

The suprahyoid muscles arise from the tongue (glossus), mandible (mylo-, geno-, anterior digastric), and skull (stylo-, posterior digastric) and insert on the hyoid bone. They elevate the hyoid bone, influencing the movements of the floor of the mouth and the tongue, especially during swallowing. With a fixed hyoid, the suprahyoid muscles, especially the digastrics, depress the mandible.

The infrahyoid muscles generally arise from the sternum, thyroid cartilage of the larynx, or the scapula (omohyoid) and insert on the hyoid bone. These muscles partially resist elevation of the hyoid bone during swallowing. Thyrohyoid elevates the larynx during production of high-pitched sounds; sternohyoid depresses the larynx to assist in production of low-pitched sounds.

### POSTERIOR TRIANGLE

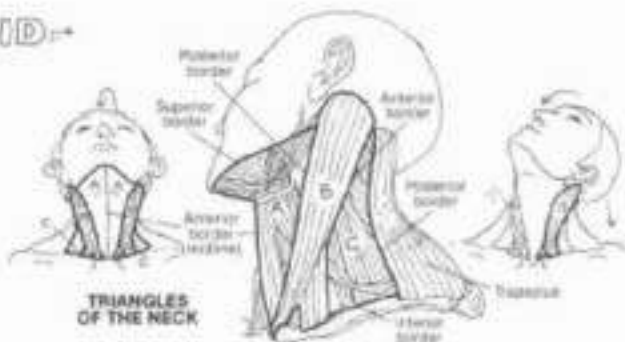SEMI-SPINALIS CAPITIS,  
SPLENIUS CAPITIS,  
LEVATOR SCAPULAE,  
SCALENUS: ANT., MED., POST.

The posterior triangle consists of an array of muscles covered by a layer of deep (investing) cervical fascia just under the skin between sternocleidomastoid and trapezius. The borders of the triangle are clearly illustrated. Muscles of this region arise from the skull and cervical vertebrae; they descend to and insert upon the upper two ribs (scalenus), the upper scapula (omohyoid, levator scapulae), and the cervical/thoracic vertebral spines (splenius capitis, semispinalis capitis). Visualizing their attachments, these muscles' function becomes clear.

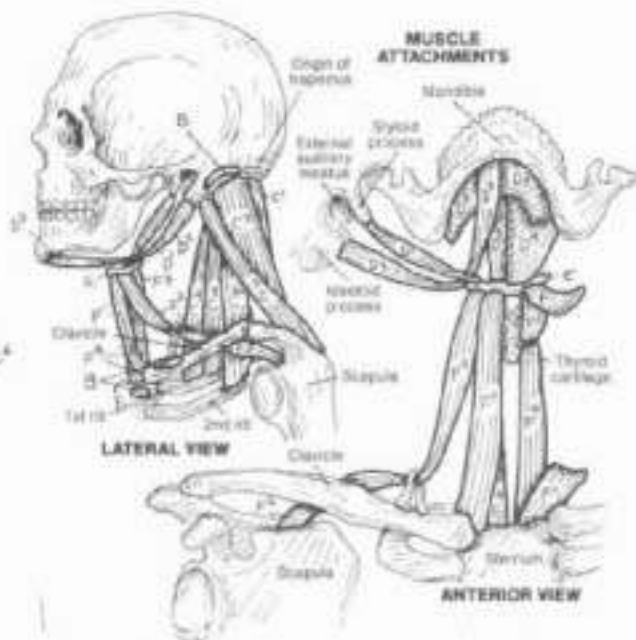


### STERNOCLEIDOMASTOID

The sternocleidomastoid muscle, acting unilaterally, tilts the head laterally on the same side while simultaneously rotating the head and pulling the back of the head downward, lifting the chin, and rotates the front of the head to the opposite side. Both muscles acting together move the head forward (anteriorly) while extending the upper cervical vertebrae, lifting the chin upward.



TRIANGLES OF THE NECK



LATERAL VIEW

ANTERIOR VIEW





















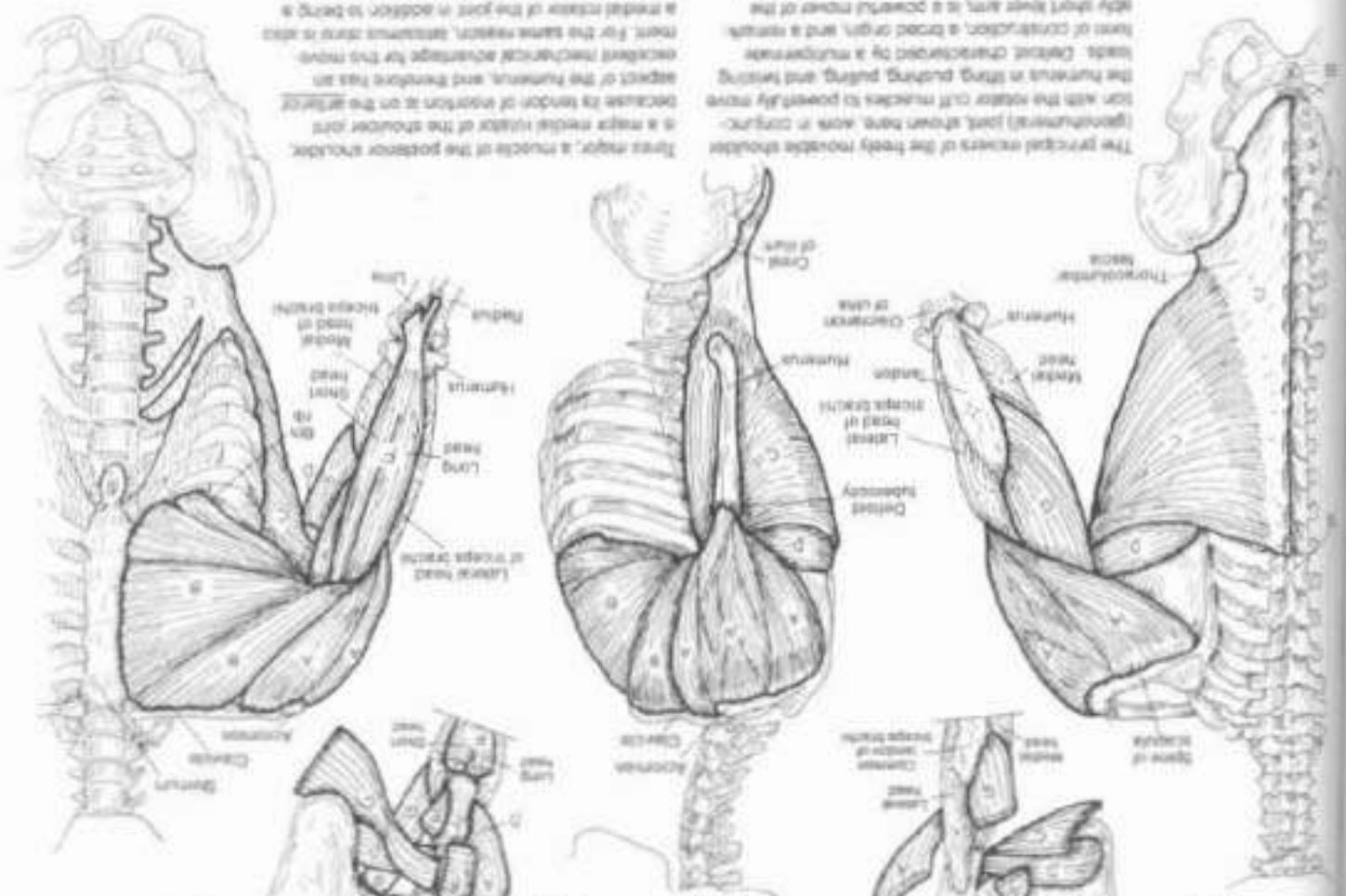




# MUSCULAR SYSTEM / UPPER LIMB MOVERS OF SHOULDER JOINT

DELTOID, PECTORALIS MAJOR,  
LATTISSIMUS DORSI, TRAPES MAJOR,  
CORACOBRACHIALIS, BICEPS BRACHII,  
TRICEPS BRACHII (LONG HEAD)

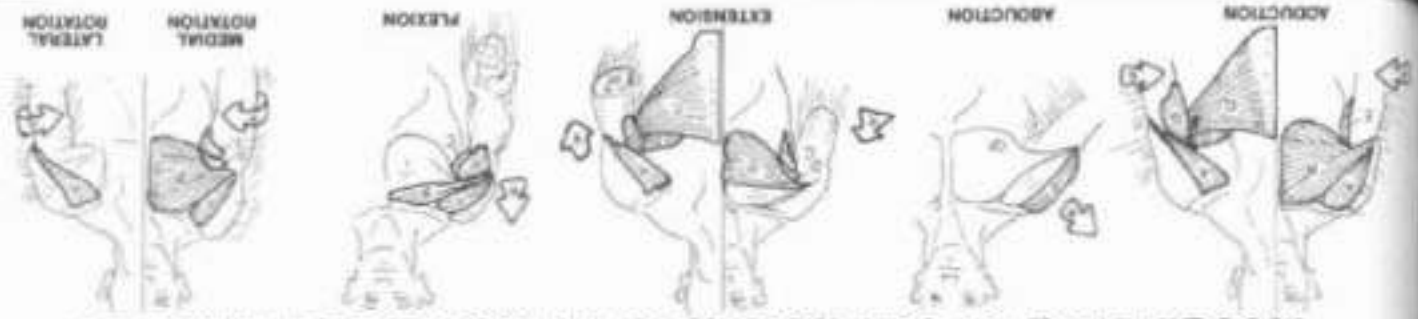(C) (1) Begin with both humeri  
vertical, note that the biceps and triceps  
are not shown in the lateral view  
(2) Begin covering the muscles back  
over the axilla at different parts of  
the chest (A) and posteriorly (B)



The principal movers of the freely movable shoulder (glenohumeral) joint shown here, are in contact with the rotator cuff muscles to powerfully move the humerus in flexing, pushing, pulling, and twisting loads. Deltoid characterized by a multipennate form of construction, a broad origin, and a nearly flat distal fiber area, is a powerful mover of the humerus in flexion, extension and abduction. The coracobrachialis (upper) fibers of pectoralis major are active in flexion of the shoulder joint, the lateral/abductor (lower) fibers extend the (Deltoid) joint. But we effective medial rotators as well.

Three major muscles of the posterior shoulder girdle are active in extension of the shoulder joint. The long head of triceps brachii is not a major mover in extension of the shoulder joint. For the same reason, latissimus dorsi is also inactive in extension of the joint in addition to being a medial rotator of the joint. In addition to being a medial rotator of the joint, latissimus dorsi is also inactive in extension of the joint in addition to being a medial rotator of the joint. In addition to being a medial rotator of the joint, latissimus dorsi is also inactive in extension of the joint in addition to being a medial rotator of the joint.

## MOVEMENTS OF THE HUMERUS AT THE SHOULDER JOINT





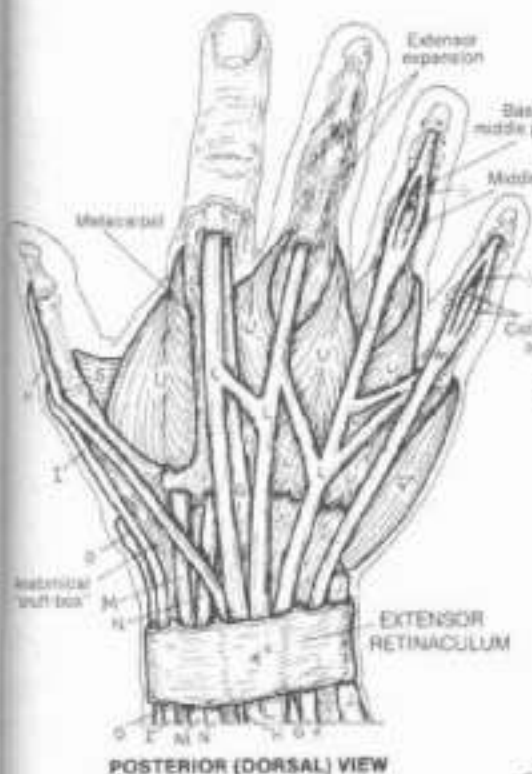




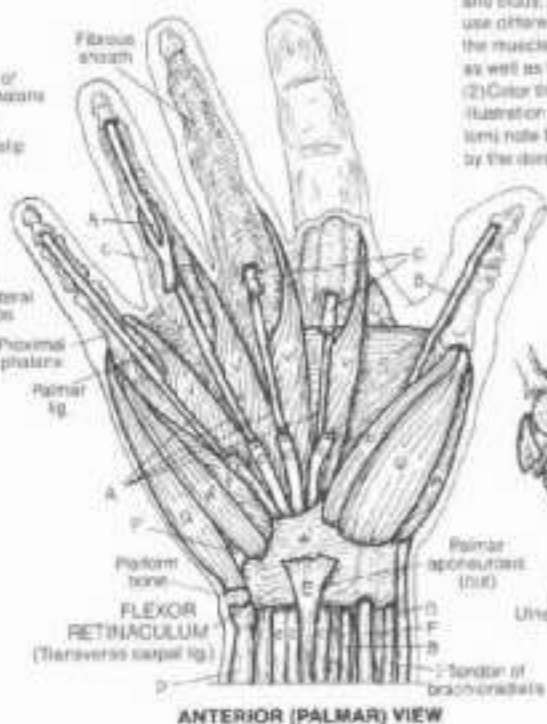# V. MUSCULAR SYSTEM/UPPER LIMB

## MOVERS OF HAND JOINTS (INTRINSICS)

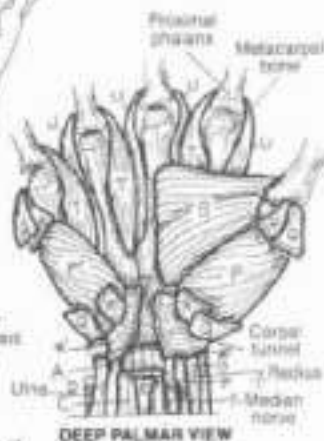CR: The extrinsic muscles which move the wrist and finger joints were covered on Plate 50, and their tendons are shown in dark line and labeled here for identification and study, but not for coloring. If possible, use different colors on this plate. (1) Color the muscles of the two anterior views, as well as the flexor retinaculum (gray). (2) Color the posterior view. (3) In the illustration of finger abduction (at the bottom) note that the little finger is not moved by the dorsal interossei (U).



POSTERIOR (DORSAL) VIEW



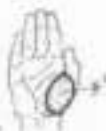ANTERIOR (PALMAR) VIEW



DEEP PALMAR VIEW

### THENAR EMINENCE:

- OPPONENS POLLICIS,
- ABDUCTOR POLLICIS BREVIS,
- FLEXOR POLLICIS BREVIS.



Note the palpable bulge of muscle (thenar eminence) just proximal to the thumb on your own hand. Integrated with the action of the other thumb movers, these three muscles make possible complex movements of the thumb. The thenar muscles arise/insert in the same general area as one another, however, their different orientation orders different functions.

### HYPOTHENAR EMINENCE:

- OPPONENS DIGITI MINIMI,
- ABDUCTOR DIGITI MINIMI,
- FLEXOR DIGITI MINIMI BREVIS.



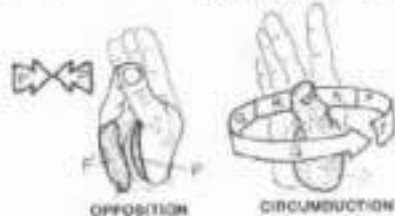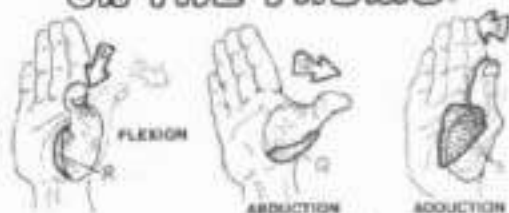These muscles move the 5th digit, they are complementary to the thenar muscles in attachment and function. The function of opposition is basic to some of the complex grasping functions of the hand.

### DEEP MUSCLES:

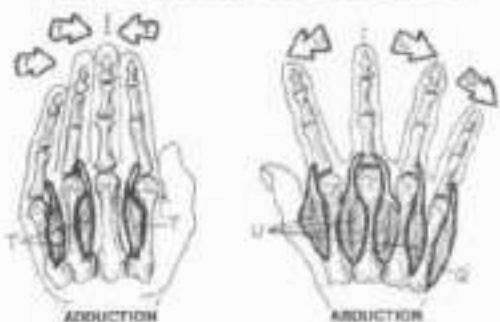
- ADDUCTOR POLLICIS,
- PALMAR INTEROSSEUS,
- DORSAL INTEROSSEUS,
- LUMBRICAL.

Adductor pollicis, in concert with the first dorsal interosseus muscle provides great strength in grasping an object between thumb and index finger. Try it. The interossei and lumbrical muscles insert into expanded finger extensor tendons (extensor expansion; see posterior view) forming a complex mechanism for flexing the metacarpophalangeal joints and extending the interphalangeal joints. By their phalangeal insertions, the interossei abduct/adduct certain digits.

### ACTIONS OF INTRINSIC MUSCLES ON THE THUMB.



### ON THE FINGERS.



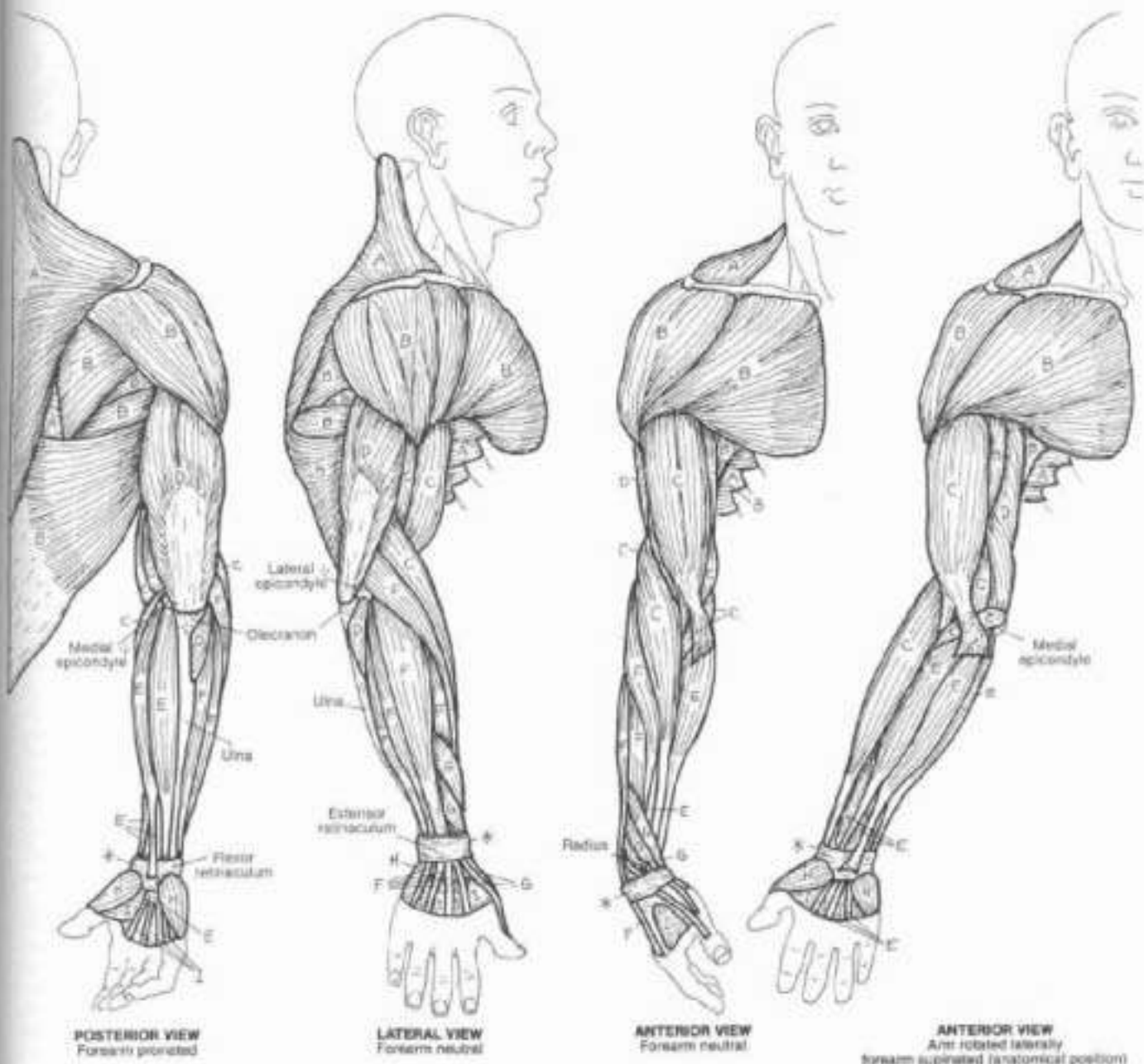
# 1. MUSCULAR SYSTEM / UPPER LIMB

## SUMMARY OF MUSCLE GROUPS

OK! Color all the muscles in a single group of each view before going on to the next group.

The muscles shown are the superficial muscles of the upper limb, many of which can be felt or seen on yourself. Try to find the outline and bulk of as many of these muscles as you can as you color each group.

- MUSCLES ACTING ON THE SCAPULA.
- MUSCLES ACTING ON THE SHOULDER JOINT.
- FLEXORS OF THE ELBOW JOINT.
- EXTENSORS OF THE ELBOW JOINT.
- FLEXORS OF WRIST, HAND, & FINGERS.
- EXTENSORS OF WRIST, HAND, & FINGERS.
- FOREARM MUSCLES ACTING ON THE THUMB.
- THENAR & HYPOTHENAR MUSCLES.
- OTHER MUSCLES ACTING ON THUMB & FINGERS.



# V. MUSCULAR SYSTEM / LOWER LIMB

## MUSCLES OF THE GLUTEAL REGION

ON. Note in the two superficial views that the upper part of the iliotibial tract (I, site in the left, lower corner), normally covering gluteus medius (B), has been cut away (1). Color each muscle in all views, including the directional arrows, before going on to the next one. The site of origin of the piriformis muscle (E) on the anterior sacrum cannot be seen at lower right. The origin of the obturator externus (F) on the right cannot be seen, but the origin of the muscle on the contralateral side can be colored. See plate 44 for additional views of these muscles.

- GLUTEUS MAXIMUS
- GLUTEUS MEDIUS
- GLUTEUS MINIMUS
- TENSOR FASCIAE LATAE

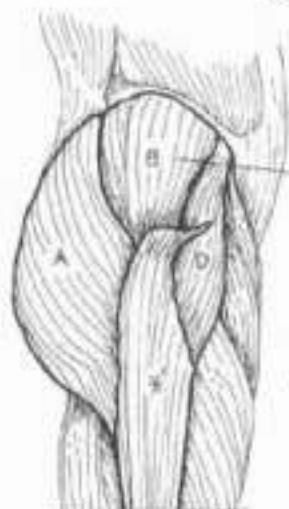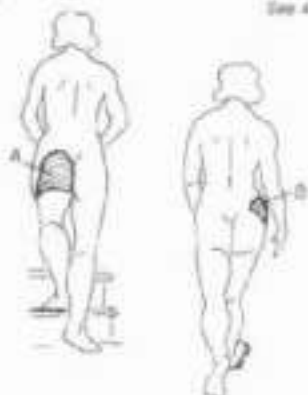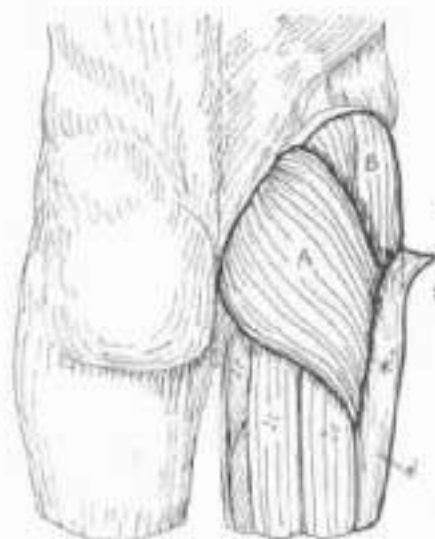- 6 DEEP, LATERAL ROTATORS:
- PIRIFORMIS
- OBTURATOR INTERNUS
- OBTURATOR EXTERNUS
- QUADRATUS FEMORIS
- GEMELLUS SUPERIOR
- GEMELLUS INFERIOR

The gluteal muscles are arranged in three layers: the most superficial is gluteus maximus. The large sciatic nerve runs deep to it, as every student nurse has warned well. Its thickness varies. Gluteus maximus extends the hip joint during running and walking uphill but does not act in relaxed walking. The immediately placed, more lateral gluteus medius is a major abductor of the hip joint and an important stabilizer (leveler) of the pelvis when the opposite lower limb is lifted off the ground.

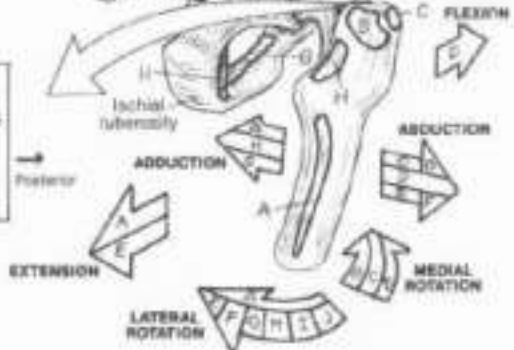
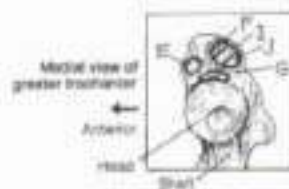
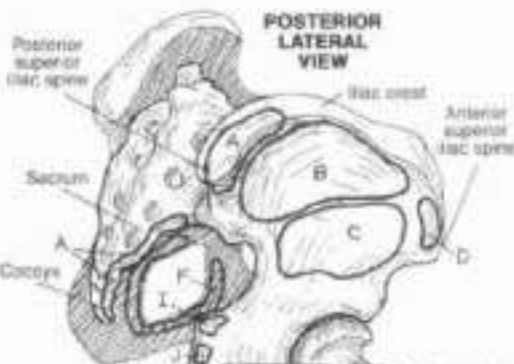
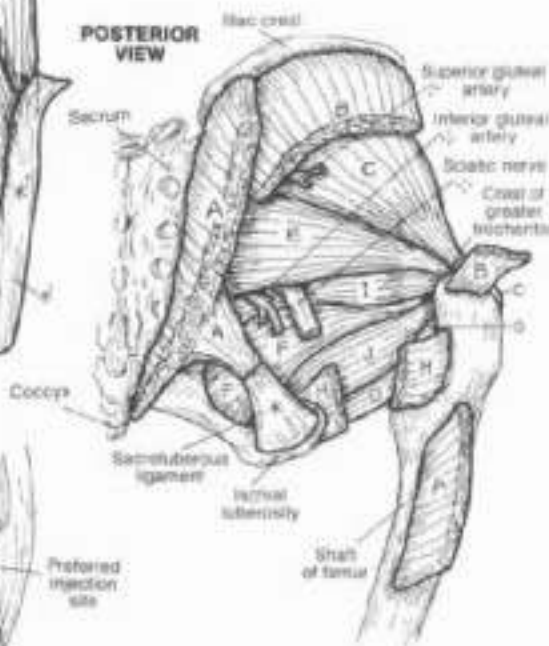
The deepest layer of gluteal muscles is the gluteus minimus and the lateral rotators of the hip joint. They cover up/fill the greater and lesser sciatic notches. These muscles generally insert at the posterior aspect of the greater trochanter of the femur. The gluteal muscles (less gluteus maximus) correspond to some degree with the rotator cuff of the shoulder joint: lateral rotators posteriorly, abductor (gluteus medius) superiorly, medial rotators (gluteus medius and minimus, tensor fasciae latae) anteriorly.

### ILIOTIBIAL TRACT

The iliotibial tract, a thickening of the deep fascia (fascia lata) of the thigh, runs from ilium to tibia and helps stabilize the knee joint laterally. The muscle tensor fasciae latae, a frequently visible and palpable flexor and medial rotator of the hip joint, inserts into this fibrous band, tensing it.



LATERAL VIEW



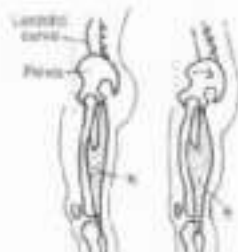
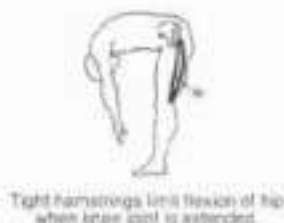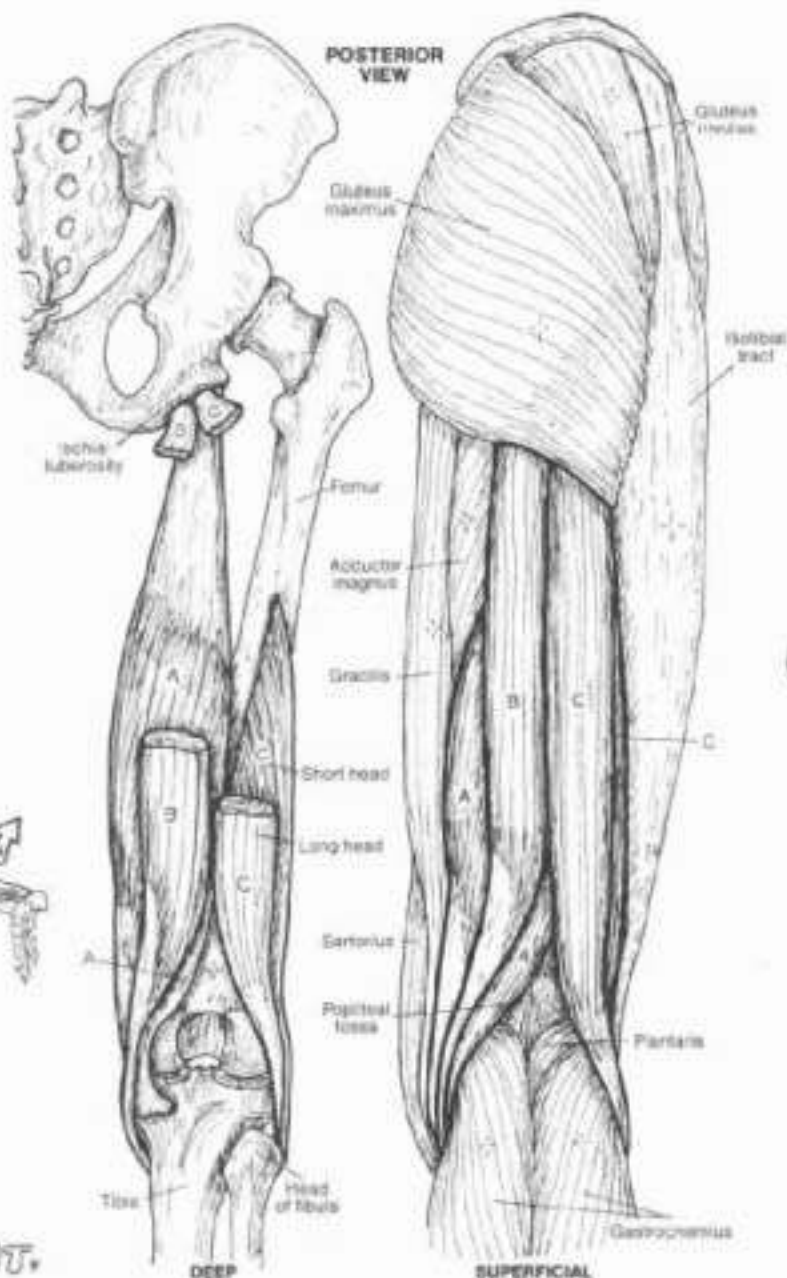


# MUSCULAR SYSTEM / LOWER LIMB

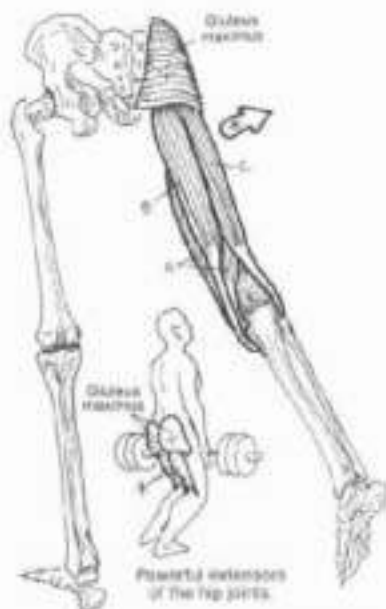
## MUSCLES OF POSTERIOR THIGH

### HAMSTRINGS: SEMIMEMBRANOSUS, SEMITENDINOSUS, BICEPS FEMORIS.

On (1) Color each hamstring muscle in the deep view before going on to the superficial. Then color the diagram of flexion or extension.  
 (2) Color gray the outline of the muscles in the drawings at upper right.



Tight hamstrings (at right) tilt pelvis backwards, flattening lordotic curve of lower back.



EXTENSORS OF THE HIP JOINT.

FLEXORS OF THE KNEE JOINT.

The muscles of the posterior thigh (called hamstrings after a procedure for cutting the tendons of these muscles in certain domestic animals) are equally effective at both extension of the hip joint and flexion of the knee joint; contraction of antagonists can isolate one or the other joint movement. Unlike the hip extensor gluteus maximus, the hamstrings are active during normal walking. In relaxed standing, the hamstrings (and gluteus maximus) are inactive. In knee flexion, the hamstrings act in concert with sartorius, gracilis, and gastrocnemius.

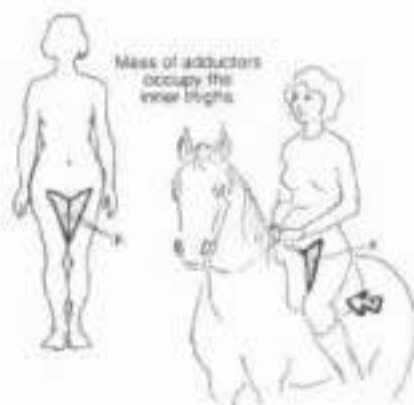Reduced hamstring stretch ("tight hamstrings") limits hip flexion with the knee extended; flexion of the knee permits increased hip flexion. Try this on yourself! Tight hamstrings, by their ischial origin, pull the posterior pelvis down, lengthening the erector spinae muscles, and flattening the lumbar lordosis, potentially contributing to limitation of lumbar movement and back pain. The long tendons of the hamstrings can be easily felt just above the partially flexed knee.

# 1. MUSCULAR SYSTEM / LOWER LIMB

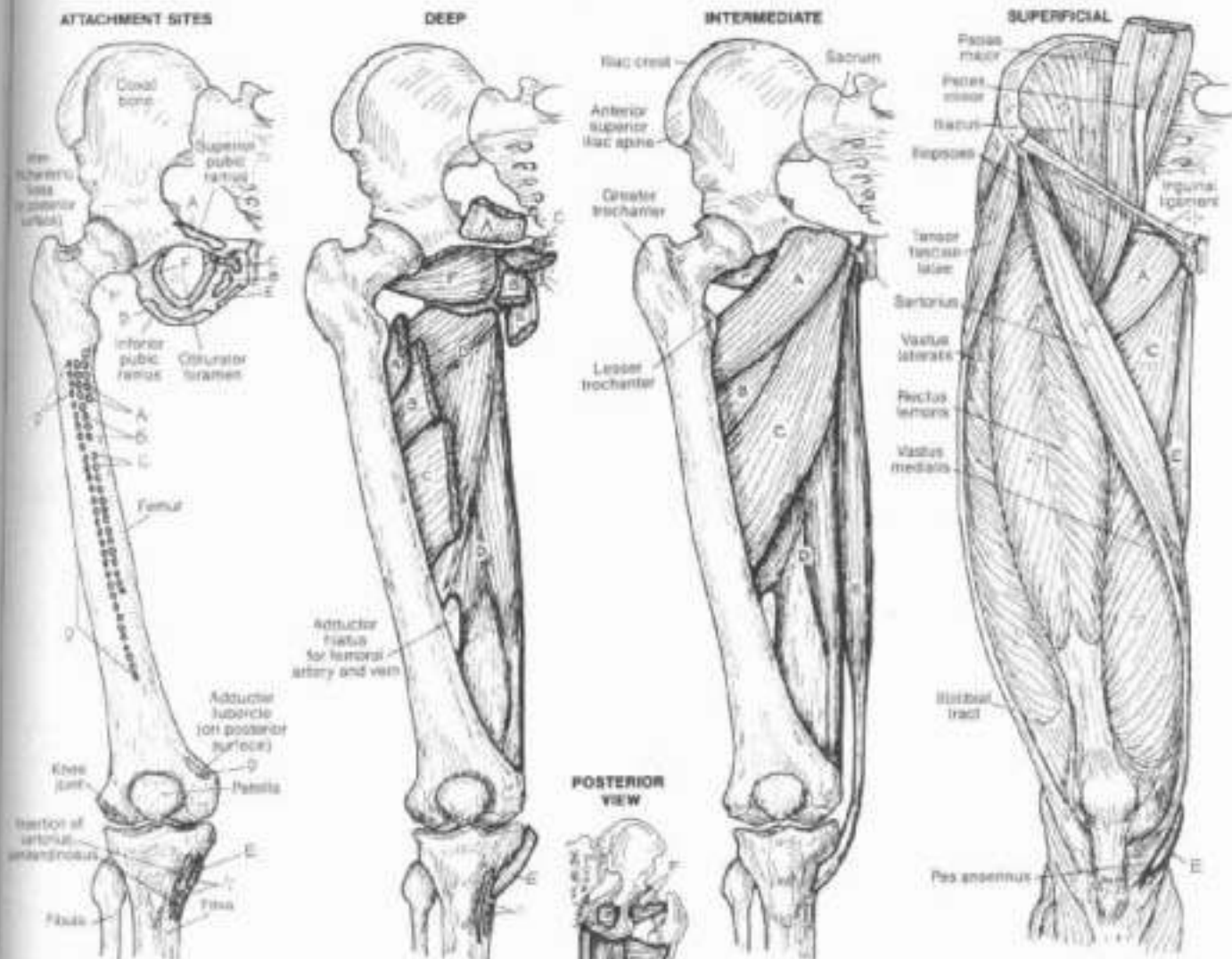
## MUSCLES OF MEDIAL THIGH

**PECTINEUS,  
ADDUCTOR BREVIS,  
ADDUCTOR LONGUS,  
ADDUCTOR MAGNUS,  
GRACILIS,  
OBTURATOR EXTERNUS,**

Do. Color one muscle at a time in the five main views below going to the next one. Note that the attachment sites on the posterior surface of the femur are represented by solid lines.

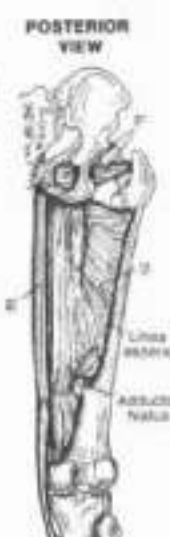

### ANTERIOR VIEW



The medial thigh muscles consist of the hip joint adductors (A through E) and obturator externus, a lateral rotator of that joint. The latter was colored on Plate 53 as one of the deep gluteal muscles, as its tendon passes into that region. However, it is compartmentalized by fasciae in the medial thigh, covers the external surface of the obturator foramen in the deep upper medial thigh, and receives the same innervation as the adductors. The gracilis is the longest of the adductor group, crosses the medial knee

(fixing it), and inserts only on the medial tibia; its tendon joins the tendons of sartorius and semitendinosus to form an insertion shaped like a goose's foot (hence called the pes anserinus). The adductor magnus is the most massive of the group (see posterior view). In its lower half, adductor magnus fibers give way to the passage of the femoral vessels (adductor hiatus). All the adductors, except gracilis, insert on the vertical rough line (linea aspera) on the posterior surface of the femur.



# MUSCULAR SYSTEM / LOWER LIMB

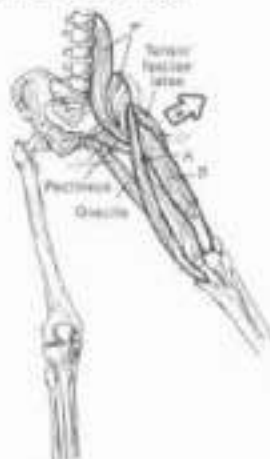## MUSCLES OF ANTERIOR THIGH

**SARTORIUS.**  
**QUADRICEPS FEMORIS:**  
**RECTUS FEMORIS.**  
**VASTUS LATERALIS.**  
**VASTUS INTERMEDIUS.**  
**VASTUS MEDIALIS.**  
**ILIOPSOAS.**

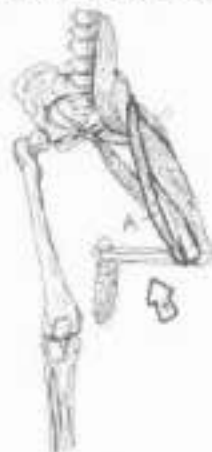**PATELLAR**  
**LIGAMENT.**

On the patellar ligament (G) is colored gray but the patella is left uncolored (1) Begin with the deep view of the thigh and then complete the superficial view (2) On the far left, color the portions of the quadriceps that are innervated by the hamstring group. (3) Complete the action diagrams along the right margin.

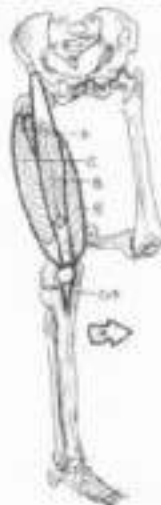**FLEXORS**  
**OF THE**  
**HIP JOINT.**



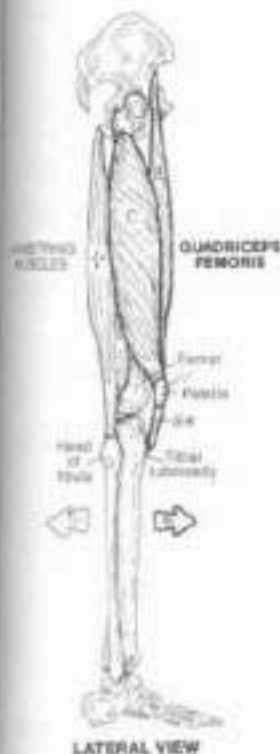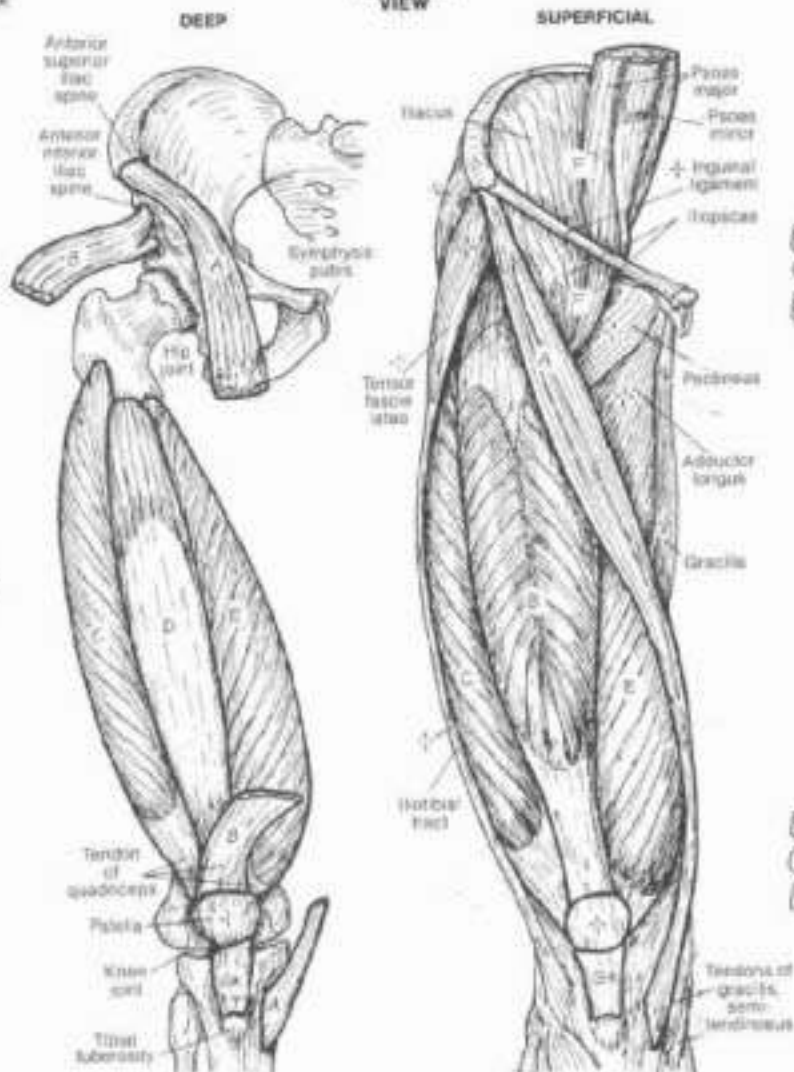
**FLEXOR**  
**OF THE**  
**KNEE JOINT.**



**EXTENSORS**  
**OF THE**  
**KNEE JOINT.**



**ANTERIOR**  
**VIEW**



The sartorius ("tailor's" muscle; so-called because of the role of this muscle in enabling a crossed-legs-sitting posture) is a flexor and lateral rotator of the hip joint, and a flexor of the knee joint, as you can infer from its illustrated attachments. The quadriceps femoris muscle arises from four heads. The vastus medialis and lateralis arise from the linea aspera on the posterior aspect of the femur; the vastus intermedius arises from the anterior femoral shaft. All four converge on to the superior aspect (base) of the patella to form the patellar tendon. Some tendon fibers continue over the patellar surface to join the ligament below. At the inferior aspect (apex) of the patella, the tendinous fibers continue to the tibial tuberosity.

The tendon between the patella and the tibial tuberosity is called the patellar ligament. Rectus femoris is a strong hip joint flexor, and is the only member of quadriceps to cross that joint. Quadriceps femoris is the only knee extensor. The significance of its role becomes crystal clear to those having experienced a knee injury; the muscles tend to atrophy and weaken rapidly with disuse, and "quad" exercises are essential to maintain structural stability of the joint. The iliopsoas is the most powerful flexor of the hip, having a broad thick muscle belly and attaching at the lesser trochanter at the proximal end and of the femoral shaft. Recall Plate 42 for its posterior abdominal origin.



# V. MUSCULAR SYSTEM / LOWER LIMB

## MUSCLES OF ANTERIOR & LATERAL LEG

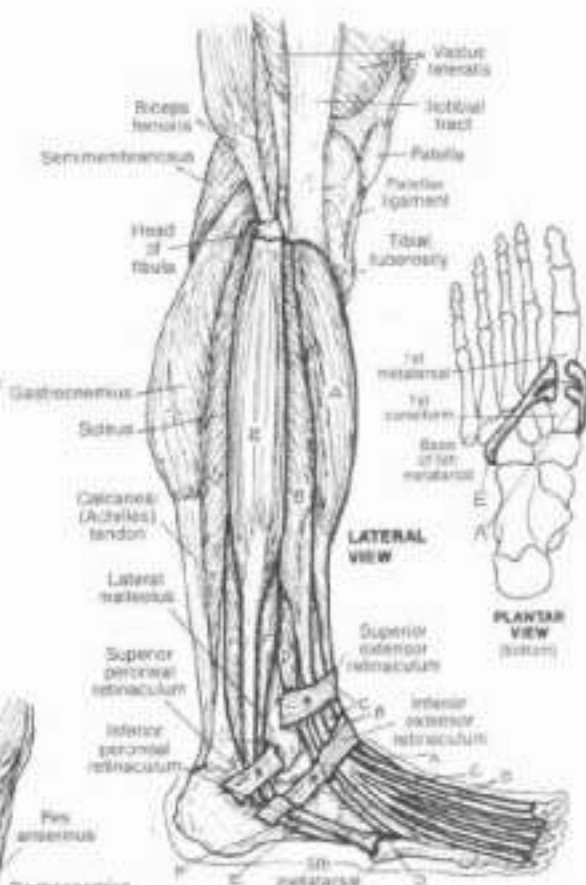
On page 56, begin with the attachment sites of the anterior leg. Note that the muscles A, B, and C arise from the interosseous ligament as well as the tibia and the fibula. Do not color the attachment sites of the thigh muscles (in small circles). Attachment sites on the plantar surface of the foot are shown at upper right.

The muscles of the leg are arranged into anterior-lateral, lateral, and posterior compartments. The bony ridge (anterior margin) of the tibia creates two oblique surfaces the antero-lateral of which relates to the anterior leg muscles, the antero-medial surface is bony (ouch!) and devoid of muscle. The lateral compartment muscles largely arise from the fibula and the interosseous ligament between tibia and fibula.

### ANTERIOR LEG:-

**TIBIALIS ANTERIOR.**  
**EXTENSOR DIGITORUM LONGUS.**  
**EXTENSOR HALLUCIS LONGUS.**  
**PERONEUS TERTIUS.**

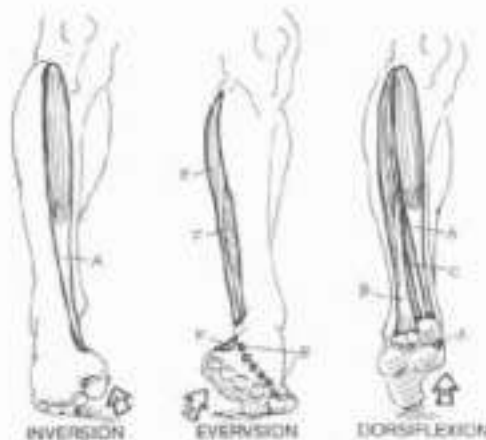
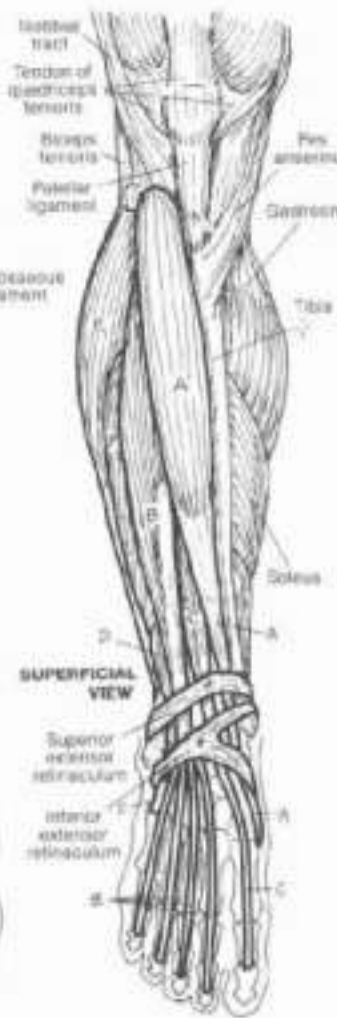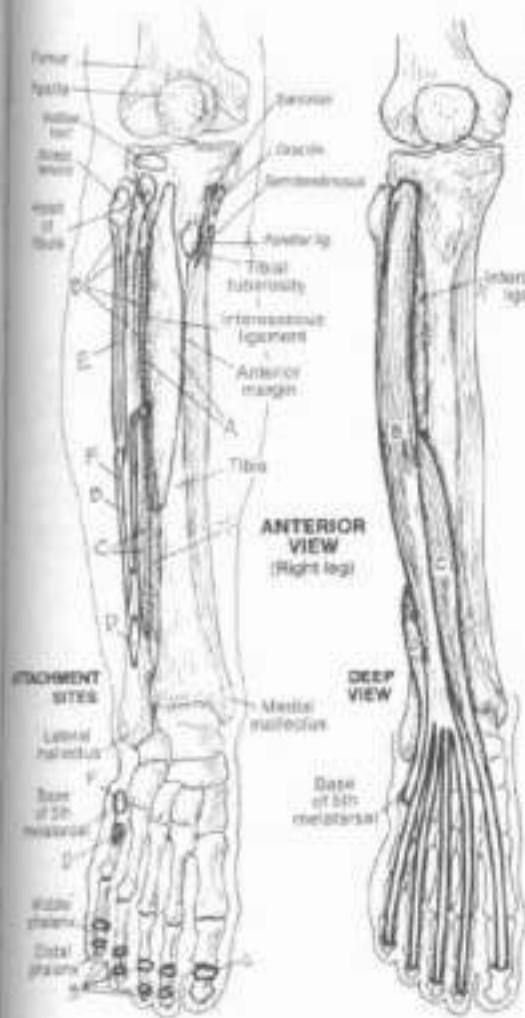
All of the anterior leg muscles are dorsiflexors (extensors) of the ankle, extensor hallucis and digitorum longus are toe extensors; tibialis anterior is an inverter of the subtalar joints as well, and peroneus tertius (the 5th tendon of extensor digitorum) is an evertor. Due to rotation of the lower limb during embryonic development, these extensors are anterior to the bones in the anatomical position (unlike the upper limb wrist extensors). Tibialis anterior is particularly helpful in lifting the foot up during the swing phase of walking to avoid striking the toes.



### LATERAL LEG:-

**PERONEUS LONGUS.**  
**PERONEUS BREVIS.**

The peroneal muscles are principally evertors of the foot, and are especially active during plantar flexion, as in walking on the toes or pushing off with the great toe. Peroneus tertius arises in the peroneal compartment but is actually part of extensor digitorum.

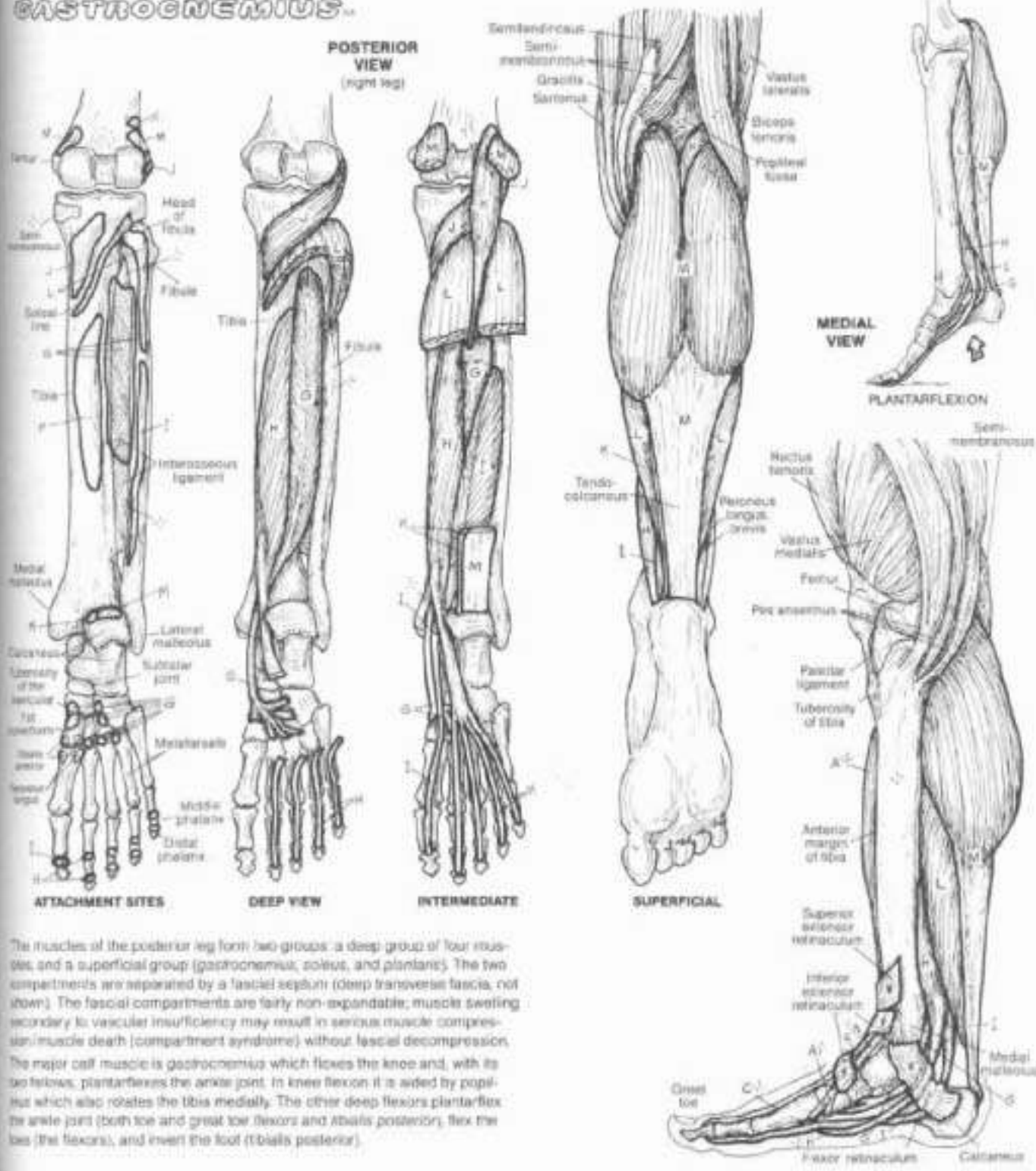


# V. MUSCULAR SYSTEM / LOWER LIMB

## MUSCLES OF POSTERIOR LEG

**TIBIALIS POSTERIOR.**  
**FLEXOR DIGITORUM LONGUS.**  
**FLEXOR HALLUCIS LONGUS.**  
**POPLITEUS.**  
**PLANTARIS.**  
**SOLEUS.**  
**GASTROCNEMIUS.**

CA: The muscles to be colored on this plate are labeled G-M; any other letter label found here (A-F from Pl. 57, N-Y from Pl. 59) is for identification only, and those muscles should be left uncolored. You may repeat colors used for muscles on Plate 57 on this and/or the next plate. (1) Color one muscle at a time in each of the posterior views. Note that the plantaris (K), the soleus (L) and the gastrocnemius (M) all insert into the same tendon (tendocalcaneus) which receives the color M. (2) Color the upper and lower medial views.



The muscles of the posterior leg form two groups: a deep group of four muscles, and a superficial group (gastrocnemius, soleus, and plantaris). The two compartments are separated by a fascial septum (deep transverse fascia, not shown). The fascial compartments are fairly non-expandable; muscle swelling secondary to vascular insufficiency may result in serious muscle compression/muscle death (compartment syndrome) without fascial decompression. The major calf muscle is gastrocnemius which flexes the knee and, with its two fellows, plantarflexes the ankle joint. In knee flexion it is aided by popliteus which also rotates the tibia medially. The other deep flexors plantarflex the ankle joint (both toe and great toe flexors and tibialis posterior), flex the leg (the flexors), and invert the foot (tibialis posterior).

# 1. MUSCULAR SYSTEM / LOWER LIMB

## MUSCLES OF THE FOOT (INTRINSICS)

On feet free to use the colors used for the letter labels on plates 57 and 58. These letters are provided here for identification, and the muscles they refer to are not meant to be colored. Also note that plantar surface attachment sites for those extrinsic foot muscles have been omitted in the illustration of the foot layer but can be found on the two preceding plates. (1) Begin with the foot layer and complete each illustration below going on to the next.

The dorsal intrinsic muscles of the foot (those that arise and insert within the dorsum of the foot) are limited to two small extensors of the toes shown at right, most of the extensor function being derived from extrinsic extensors.

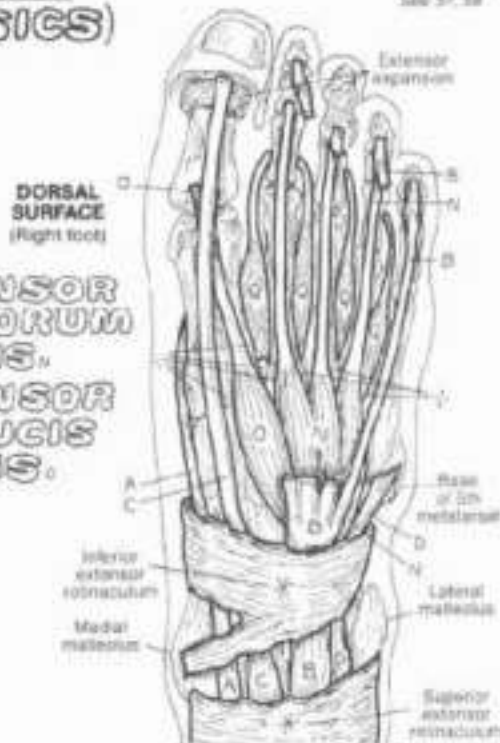
The intrinsic muscles of the plantar region of the foot are shown here in four layers. The plantar interossei, wedged between the metatarsal bones, constitute the deepest (4th) layer. They adduct toes 3-5, flex the metatarsophalangeal (MP) joints of these toes, and contribute to tension of the interphalangeal (IP) joints of these toes through the mechanism of the extensor expansion. The dorsal interossei adduct toes 3-5, and facilitate the other actions of the plantar interossei.

The third layer of muscles acts on the great toe (hallux) and 5th digit (5th toe). The second layer includes the quadratus plantae, inserting into the lateral border of the common tendon (H) of flexor digitorum longus (FDL). It assists that muscle in flexion of the toes. The umbilicals arise from the individual tendons of FDL and insert into the medial aspect of the extensor expansion (dorsal aspect). They flex the MP joints, and extend the IP joints of toes 2-5 via the extensor expansion.

The superficial (first) layer consists of the abductors of the 1st and 5th digits, and the flexor digitorum brevis. The plantar muscles are covered by the thickened deep fascia of the sole, the plantar aponeurosis, extending from calcaneus to the fibrous sheath of the flexor tendons.

**DORSAL SURFACE (Right foot)**

**EXTENSOR DIGITORUM BREVIS.**  
**EXTENSOR HALLUCIS BREVIS.**



**FLEX. HALLUCIS BREVIS.**

**ABDUCTOR HALLUCIS.**

**FLEX. DIGITI MINIMI BREVIS.**

**QUADRATUS PLANTAE.**

**& LUMBRICALS.**

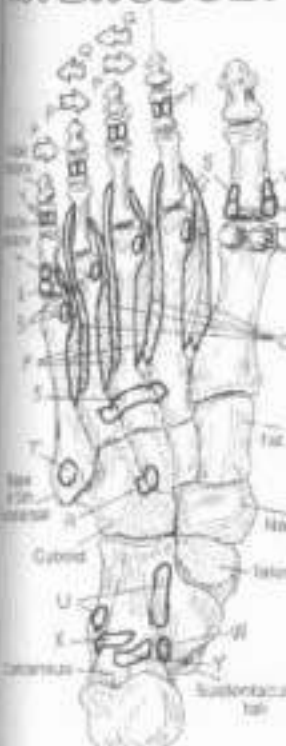**ABDUCTOR HALLUCIS.**

**ABDUCTOR DIGITI MINIMI.**

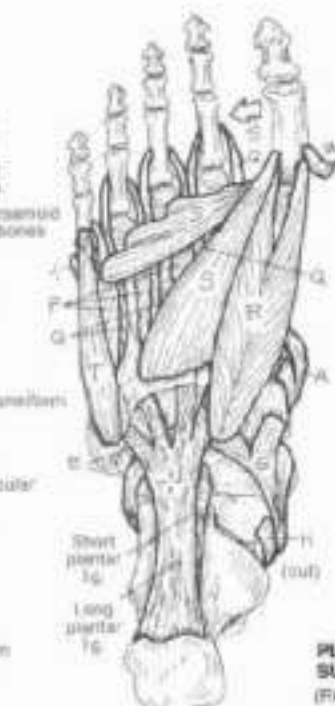
**FLEX. DIGITOR. BREVIS.**

**PLANTAR INTEROSSEI.**

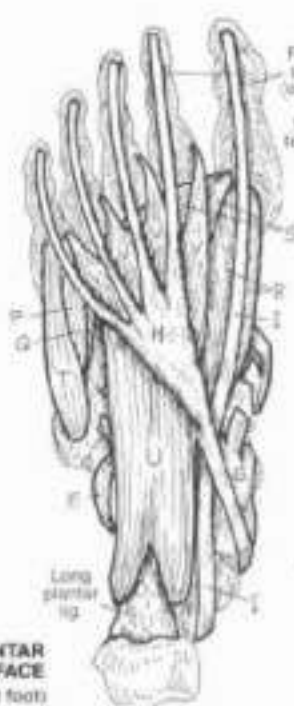**DORSAL INTEROSSEI.**



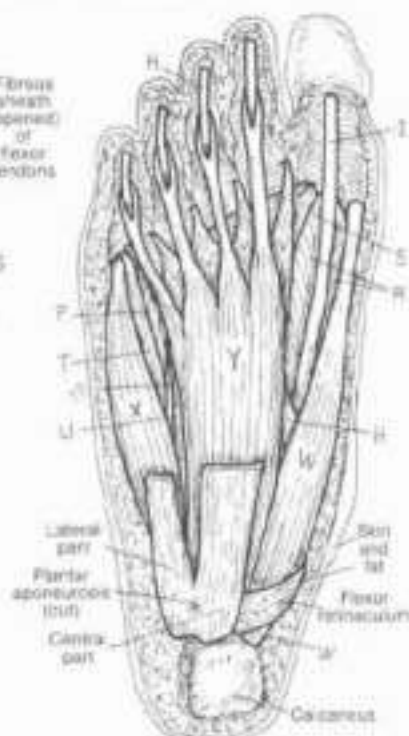
FOURTH LAYER



THIRD LAYER



SECOND LAYER



FIRST LAYER (superficial)

**PLANTAR SURFACE (Right foot)**



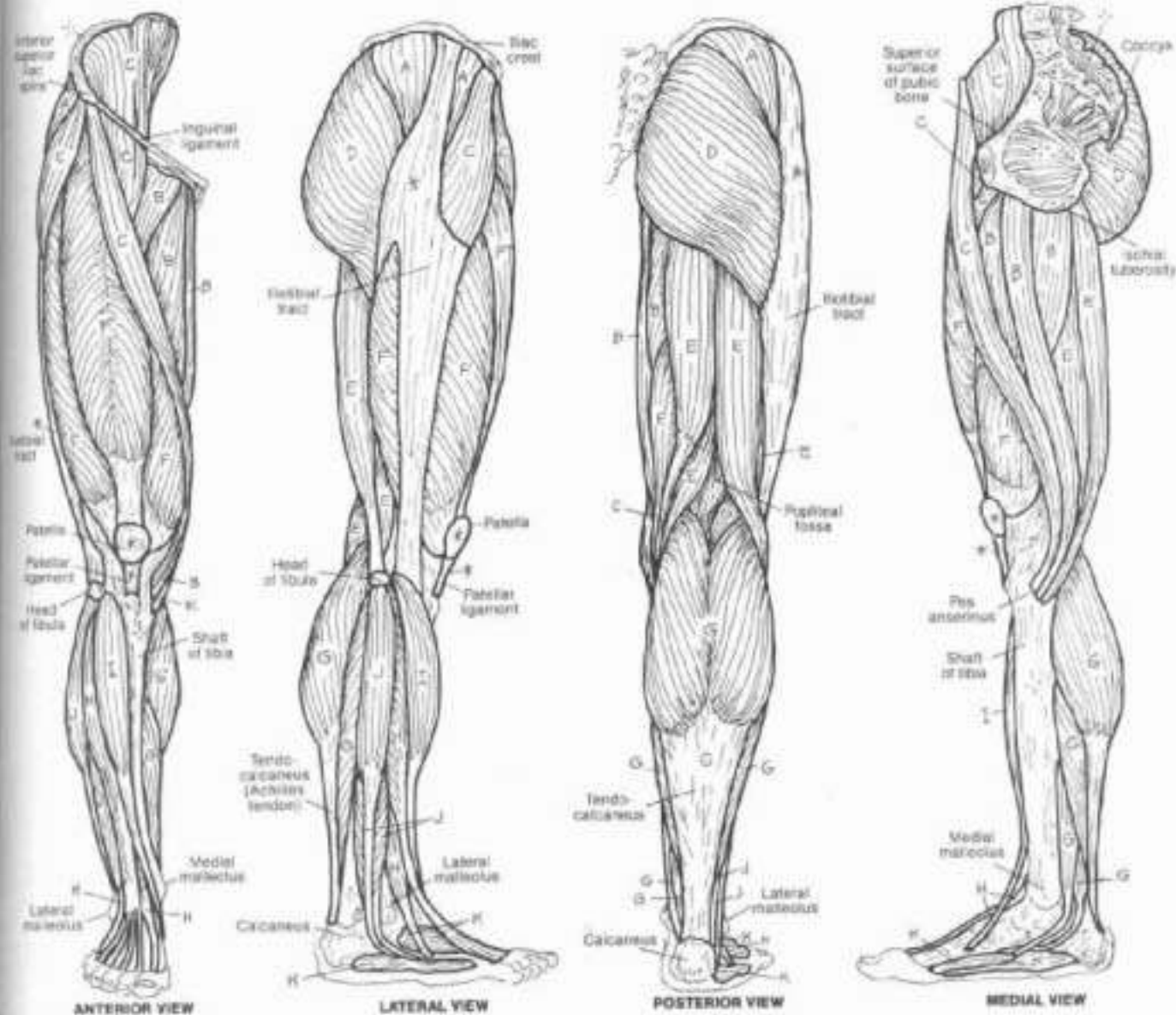
# I. MUSCULAR SYSTEM / LOWER LIMB

## SUMMARY OF MUSCLE GROUPS

- ABDUCTORS OF THE HIP.
- ADDUCTORS OF THE HIP.
- FLEXORS OF THE HIP.
- EXTENSORS OF THE HIP.
- FLEXORS OF THE KNEE.
- EXTENSORS OF THE KNEE.
- PLANTAR FLEXORS OF ANKLE & FOOT.
- DORSAL FLEXORS OF ANKLE & FOOT.
- INVERTORS OF THE ANKLE.
- EVERTORS OF THE ANKLE.
- INTRINSIC MUSCLES OF THE FOOT.

CH - Color one group of muscles in as many views as it appears before going on to the next. Most of the intrinsic muscles of the foot (IC) are on the plantar surface and are not shown here.

Some of the muscles shown here cross two joints and/or have more than one function; the primary functions of the muscles are labeled here, as in Plate 52 (summary of upper limb muscles).



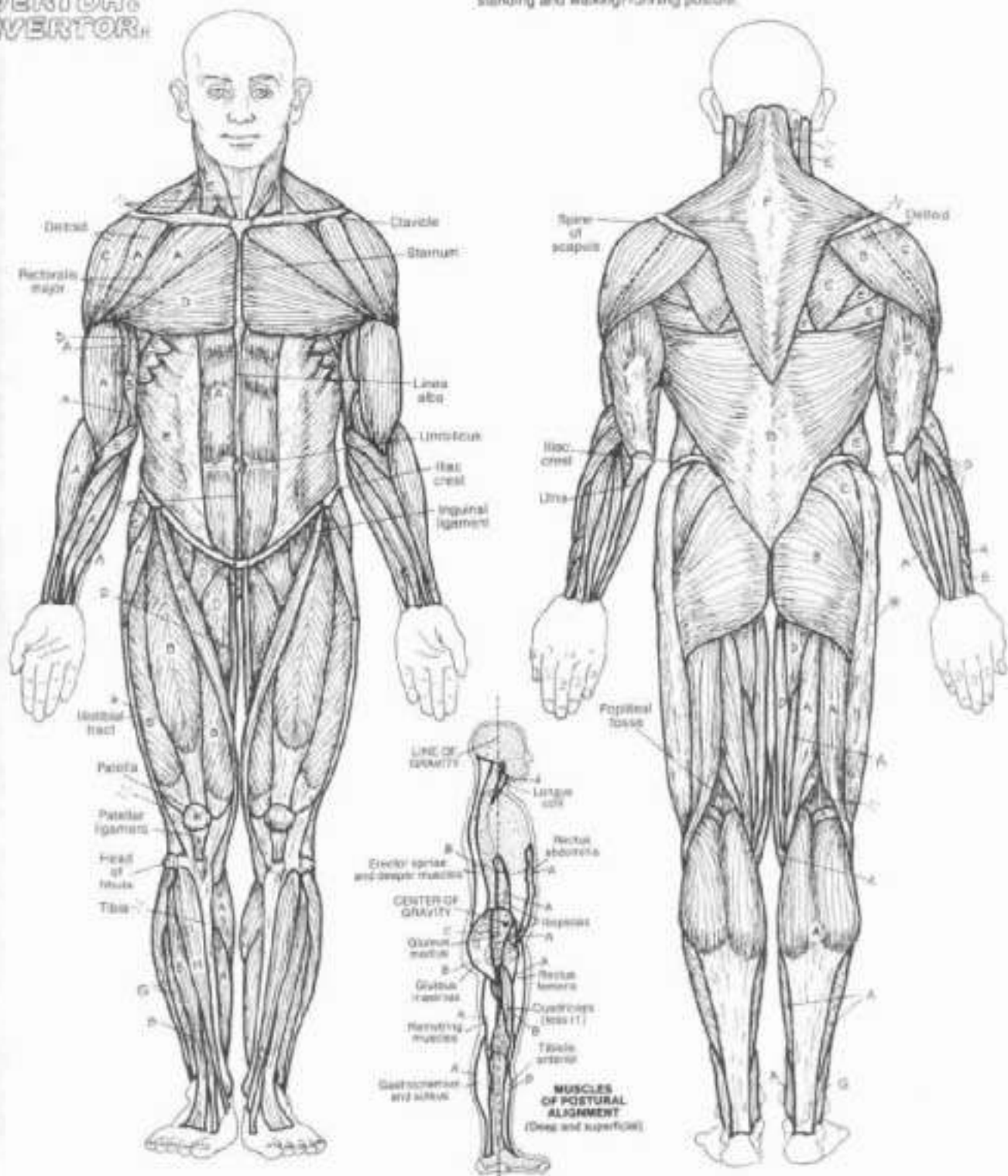
# I. MUSCULAR SYSTEM / SKELETAL MUSCULATURE

## FUNCTIONAL OVERVIEW

**FLEXOR,  
EXTENSOR,  
ABDUCTOR,  
ADDUCTOR,  
ROTATOR,  
SCAPULAR  
STABILIZER,  
EVERTOR,  
INVERTOR.**

CA: Use light colors throughout (especially for A and B). Deeper muscles are not included in the large illustrations. (1) Color all of the muscle groups in the anterior view before going on to the posterior view at right. Only the muscles on one side of the figure have been labeled. As you color the muscle, also color its opposite. (2) Color the small diagram below.

Upon coloring these functional groups, note the spatial relationship of adductors to abductors and evertors to invertors. Take particular note of the extensors and flexors. Recall that extension of weightbearing joints is an anti-gravity function, and extensor muscles of these joints tend to keep the standing body vertically straight. Note the line of gravity and its relationship to the vertebral, hip, knee, and ankle joints. The center of gravity of an average human being standing with perfect posture is just anterior to the motion segment of S1-S2. Flexion of the neck and torso moves the center of gravity forward, loading the posterior cervical, thoracic, and lumbar paraspinal (extensor) muscles. The actors moving the vertebral, hip, knee, and ankle joints make possible erect standing and walking/running posture.



# VI. CARDIOVASCULAR SYSTEM

## BLOOD AND BLOOD ELEMENTS

Color these subscripts: DP = dark purple, LP = light purple, C = orange, P = pink, PB = pale blue, PO = pale orange, R = red, and T = tan. These colors match the stains usually employed to observe these cells. (1) Color the test tube (use any color for B and C). (2) In the eosinophil and basophil (bottom left), first color the cytoplasm and then stipple in the rest.

### ERYTHROCYTES

(RED BLOOD CORPUSCLES)



Erythrocytes (RBCs, approximately 4.5–5.2 million per milliliter of blood in men; 4–5.5 million/ml in women) are formed in the bone marrow where they lose their nucleus and most of their organelles prior to their release into the peripheral blood. Recently released immature erythrocytes (reticulocytes) may retain some ribosomal RNA in their cytoplasm; these granules appear dark purple and reticulated when stained. Normally making up about 1% of the RBC population, reticulocytes may increase in number during chronic oxygen lack (e.g., at prolonged high altitude). The circulating RBC (without nucleus or organelles, it is truly a corpuscle and not a cell) is a non-rigid, biconcave-shaped, membrane-lined sac of hemoglobin, a large iron-containing protein. Hemoglobin (12–16 grams/deciliter of blood in women; 14–18 g/dL in men) has a powerful affinity for oxygen, and is the principal carrier of oxygen in the body; plasma is the other carrier. Erythrocytes pick up oxygen in the lungs and release it in the capillaries to the tissues/cells. RBCs circulate for about 120 days until ineffective, and are then taken out of the blood and broken down by cells of the spleen.

### THROMBOCYTES

(PLATELETS)

Thrombocytes or platelets (150,000–400,000/ml of blood; 2–5 μm in diameter) are small bits of cytoplasm from giant cells (megakaryocytes) of the bone marrow. Circulating in the blood for a lifetime of 10 days or so, platelets adhere to injured endothelium and play a significant role in limiting hemorrhage (aggregation of platelets, blood coagulation/clotting, and clot removal).



### GRANULAR NEUTROPHIL

Segmented neutrophils (55–75% of the WBC population) arise in the bone marrow and live short lives in the blood and connective tissues (hours–4 days). Immature forms (band neutrophils, 1–5%) may be seen in the blood; their numbers often increase in acute infections. Neutrophils rapidly engulf foreign elements/cellular debris; strong enzymes in specific granules and lysosomes destroy them (phagocytosis).

### EOSINOPHIL

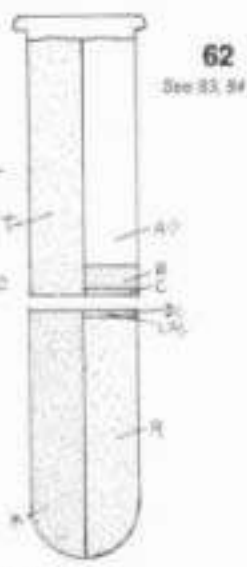
Eosinophils (1–3% of WBCs) exhibit colorful granules when properly stained. Eosinophils are phagocytic in immune reactions. They are involved in the late-onset phase of asthmatic attacks (subsequent bronchial constriction), possibly enhancing cell injury by increasing cell membrane permeability in the bronchial mucosa to allergic substances. They also appear to limit the expression of mast cell degranulation (histamine release and effects) during allergic reactions.

### BASOPHIL

Basophils (0–1% of WBCs) contain dark-staining granules. Basophils are known to degranulate in allergic reactions, releasing histamine, serotonin, and heparin. Such degranulation induces contraction of smooth muscle, increases vascular permeability (enhancing the effects of inflammation), and slows down movement of white blood cells in inflammation.

### LEUKOCYTES (WHITE BLOOD CELLS)

**PLASMA (55%)**  
**WATER (90%)**  
**PROTEINS (8%)**  
**ACIDS, SALTS (2%)**



### FORMED ELEMENTS OF THE BLOOD (45%)

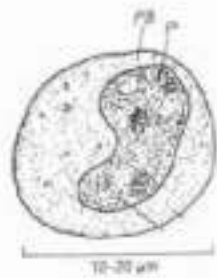**ERYTHROCYTES (99%)**  
**THROMBOCYTES (0.6–1.0%)**  
**LEUKOCYTES (0.2%)**

All constituents of the blood that can be observed as discrete structures with the aid of the light microscope are called formed elements of the blood. The rest of the blood is a protein-rich fluid called plasma. When blood is allowed to clot, the cells disintegrate (hemolysis) and a thick yellow fluid emerges called serum. Serum is basically plasma less clotting elements. If whole blood is centrifuged in a test tube, the RBCs will settle to the bottom, the leukocyte fraction will form a buffy coat on top of that, and the plasma, being the lightest, will take up the upper 55% of the total volume. Packed RBC's in a test tube constitute a hematocrit (40–52% of the blood volume in men; 37–47% in women). The difference in blood values between men and women is probably related to iron storage and metabolism differences (men store up to 50% more iron than women). A low hematocrit may be associated with anemia or hemorrhage.



### NONGRANULAR LYMPHOCYTE

Lymphocytes (20–45% of WBCs) arise from the bone marrow, and reside in the blood as well as the lymphoid tissues (lymph nodes, thymus, spleen, and so on). Lymphocytes generally consist of about 20% B cells (short-lived cells from the bone marrow and concerned with humoral immunity, transformation into plasma cells and the secretion of antibodies or immunoglobulins) and 70% T cells (long-lived cells from the thymus; may be cytotoxic, helper, or suppressor cells associated with cell-mediated immunity). Lymphocytes with neither B or T surface antigens (less than 5%) are called natural killer cells.



### MONOCYTE

Monocytes (2–6% of WBCs) arise in the bone marrow, mature in the blood (about eight hours), then leave the circulation to enter the extracellular spaces as macrophages. They are critical to the functioning of the immune system, as they present antigen to the immune cells, secrete substances in immune reactions, and destroy antigens (see glossary). They phagocytose cellular and related debris in wound healing, bone formation, and multiple other cellular activities where breakdown occurs.



## VI. CARDIOVASCULAR SYSTEM

### SCHEME OF BLOOD CIRCULATION

Or: Use blue for A, purple for B, red for C, and very light colors for D and E. (1) Color the lines for systemic and pulmonary circulation; the two figures, and the borders bracketing the large illustration. Also color purple (representing the transitional state between oxygenation and deoxygenation) the two capillaries, demonstrating the difference between capillary function in the lungs versus the body. (2) Begin in the right atrium of the heart and color the flow of deoxygenated blood (A) into the lungs. After coloring the pulmonary capillary network (B), color the oxygenated blood (C) that re-enters the heart and is pumped into and through the systemic circuit.



Circulation of blood begins with the heart which pumps blood into arteries and receives blood from veins. Arteries conduct blood away from the heart regardless of the amount of oxygen (oxygenation) in that blood. Veins conduct blood toward the heart, regardless of the degree of oxygenation of the blood. Capillaries are networks of extremely thin-walled vessels throughout the body tissues that permit the exchange of gases and nutrients between the vessel interior (vascular space) and the area external to the vessel (extracellular space). Capillaries receive blood from small arteries and conduct blood to small veins.

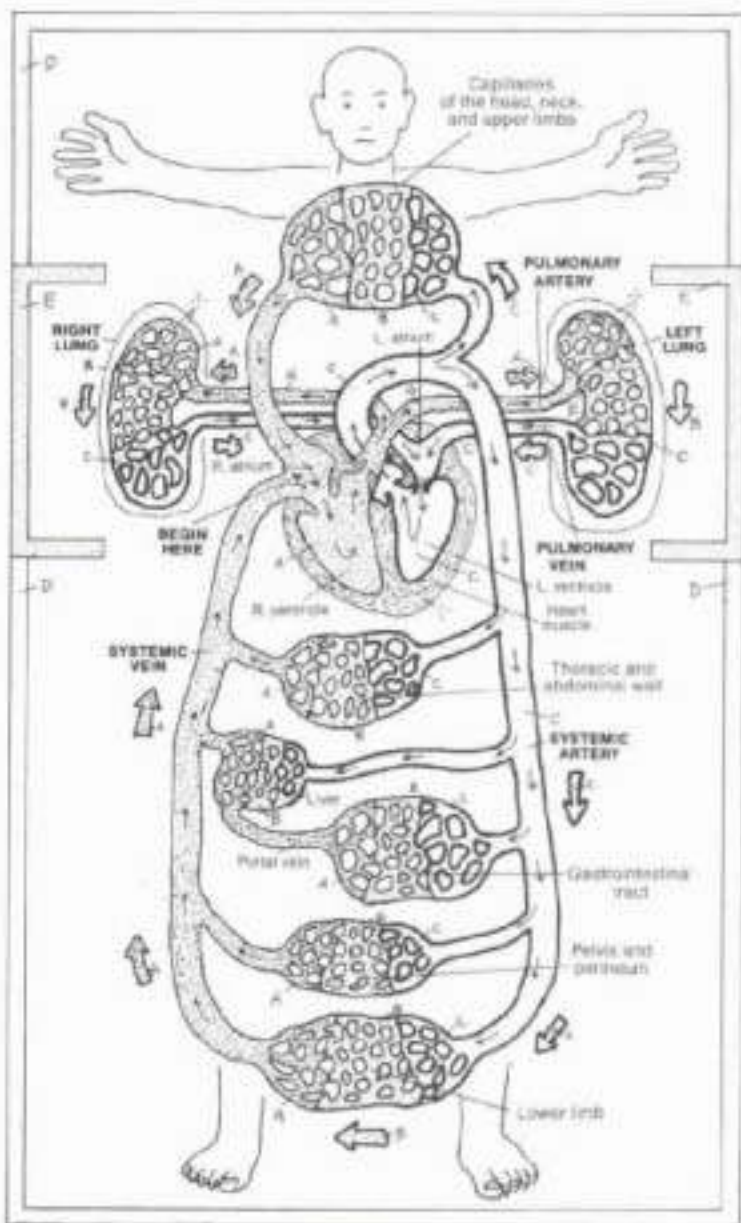
There are two circuits of blood flow: (1) the pulmonary circuit, which conveys deoxygenated blood from the right side of the heart to the lungs and freshly oxygenated blood back to the left side of the heart, and (2) the systemic circuit, which conveys oxygenated blood from the left heart to the body tissues and returns deoxygenated blood to the right heart. The color red is used universally for oxygenated blood, the color blue is used for deoxygenated blood.

Clearly, not all arterial blood is oxygenated (in the pulmonary circulation, arteries conduct deoxygenated blood to the lungs), and not all venous blood is deoxygenated (pulmonary veins conduct oxygenated blood to the heart).

Capillary blood is mixed; it is largely oxygenated on the arterial side of the capillary bed, and it is largely deoxygenated on the venous side, as a consequence of delivering oxygen to and picking up carbon dioxide from the tissues it supplies.

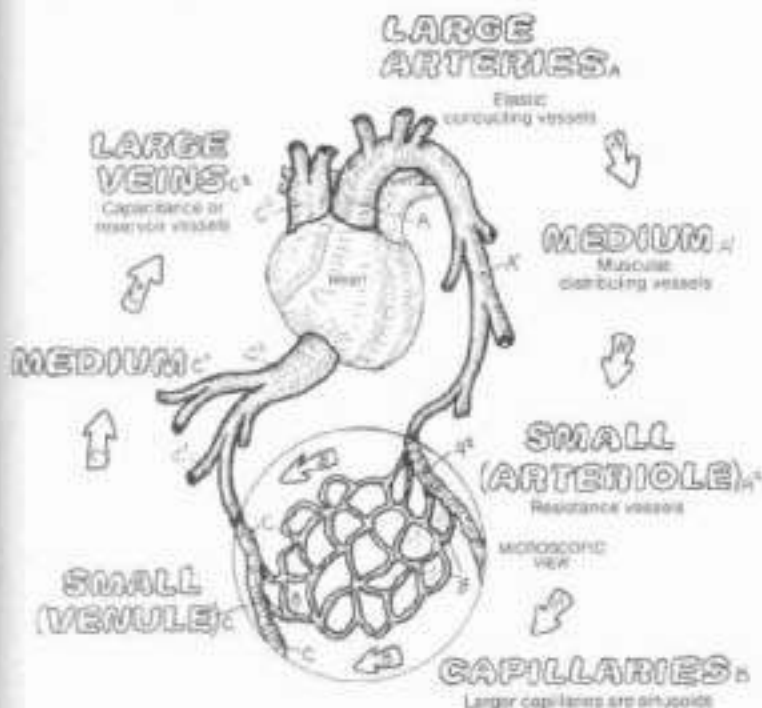
One capillary network generally exists between an artery and a vein; an exception is the portal circulation characterized by two capillary beds between artery and vein. The vein between the two networks is the portal vein. Such can be seen between the gastrointestinal tract and the liver.

### DEOXYGENATED BLOOD CAPILLARY BLOOD OXYGENATED BLOOD



# VI. CARDIOVASCULAR SYSTEM

## BLOOD VESSELS



CN. Use red for A, purple for B, blue for C, and very light colors for D, F, and H. (1) Complete the upper left diagram, beginning with the large arteries. (2) Color the blood vessels and their sites at the bottom of the plate. Note that the ves and nervus vasorum in the fibrous tissue layer (H) are not colored. (3) In the diagram of venous valve action, the blood in both vein and artery is colored gray.

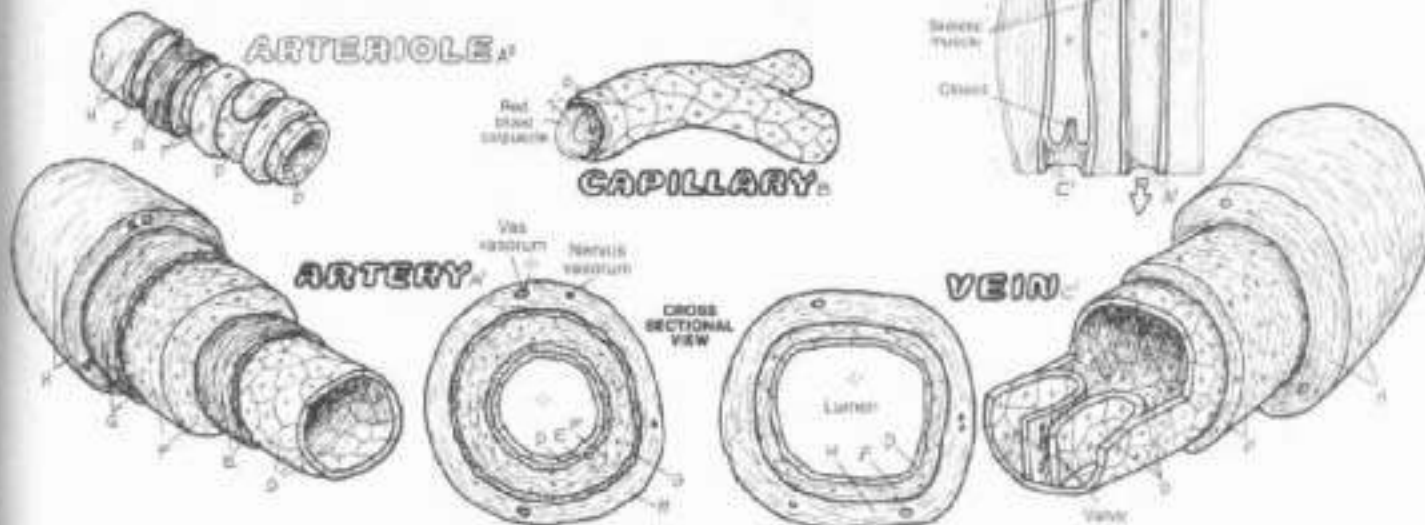
Large arteries (elastic or conducting arteries), such as the aorta or common carotid, contain multiple layers of elastic tissue. They are roughly the size of a finger. Medium arteries (muscular distributing arteries), averaging the size of a pencil, are generally named (e.g., brachial). Diminutive branches of medium arteries are called small arteries (arterioles); unnamed, they control the flow of blood into capillary beds (resistance vessels). Capillaries are unnamed simple endothelial tubes supported by the fibrous tissue. Microscopic in dimension, some capillaries are larger (sinusoids) or more specialized than others.

Veins get progressively larger as they get closer to the heart. Veins have tributaries; except in portal circulations, they do not have branches. Venules (small veins) are formed by the merging of capillaries and are basically of the same construction. Venules merge to form medium veins and these are the tributaries of large veins (capacitance or reservoir vessels). Certain specialized large veins, as in the skull, are called sinuses. The walls of these veins are thinner than those of their arterial counterparts, and their lumens are generally larger. Large veins can stretch significantly becoming virtual reservoirs of blood.

All vessels demonstrate a simple squamous epithelial (endothelial) lining (tunica interna) supported by a thin layer of fibrous tissue (not shown). Most medium veins of the neck and extremities have a series of small pockets formed from the endothelial layer. These valves are paired and point in the direction of blood flow. Though offering no resistance to blood flow, they will bend into and close off the lumen of the vein when the flow of blood is reversed. Valves resist gravity-induced blood pooling, especially in the lower limb vessels. Venous flow here is enhanced by the contraction of skeletal muscles the bulges of which give an anti-gravity boost to the movement of blood. The internal elastic lamina is a discrete layer only in medium-sized arteries and assists in maintaining blood pressure; this tissue is more diffuse in other vessels. The tunica media consists of concentrically arranged smooth muscle fibers. It is well developed in medium arteries, least developed in veins. Medium arteries use this layer in distributing blood from one field to another. In arterioles, reduced to only one or two layers, the smooth muscle can literally block blood flow into capillary beds. The external elastic lamina exists as a discrete layer only in muscular arteries. The tunica externa (adventitia) is fibrous tissue contiguous with the fascial layer in which the vessel is located; within this tunic much smaller nutrient vessels (vasa vasorum) and motor nerves (nervi vasorum) are found.

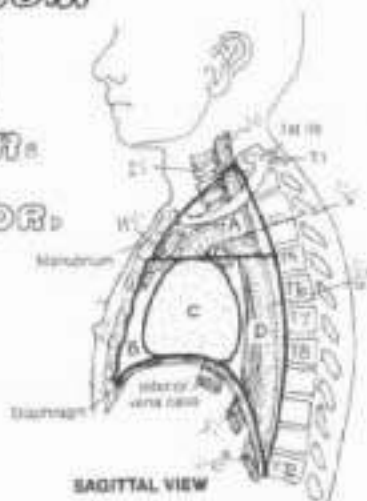
### STRUCTURE:

- TUNICA INTERNA:
- ENDOTHELIUM,
- INTERNAL ELASTIC LAMINA.
- TUNICA MEDIA:
- SMOOTH MUSCLE.
- EXTERNAL ELASTIC LAMINA.
- TUNICA EXTERNA:
- FIBROUS TISSUE.



**MEDIASTINUM REGIONS:**

**SUPERIOR:**  
**INFERIOR:**  
**ANTERIOR:**  
**MIDDLE:**  
**POSTERIOR:**



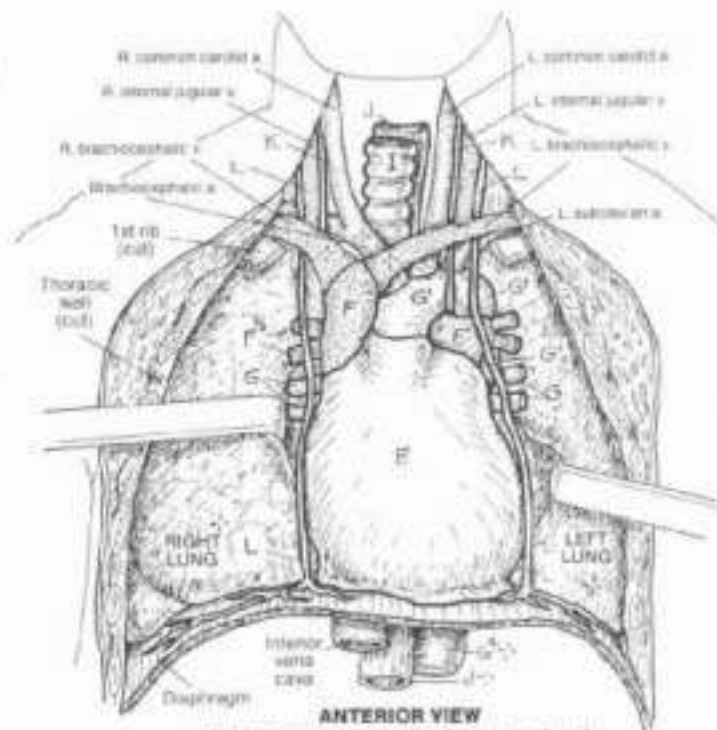
SAGITTAL VIEW

**STRUCTURES:**  
**PERICARDIUM-LINED HEART:**  
**GREAT VESSELS:**

**SUPERIOR VENA CAVA**  
**PULMONARY TRUNK**  
**PULMONARY ARTERY**  
**PULMONARY VEIN**  
**AORTIC ARCH**  
**THORACIC AORTA**

**THYMUS**  
**TRACHEA**  
**ESOPHAGUS**  
**VAGUS NERVE**  
**PHRENIC NERVE**

CA: Use blue for T, red for G, and your lightest colors for A-D. (1) Begin with the regions of the mediastinum at upper left and color over all the structures within the dark outline. (2) Color the major structures within the mediastinum in the anterior view. Note that the lungs, not being in the mediastinum, remain uncolored. Note that the thymus, which can be seen in the sagittal view, has been deleted here to show the great vessels covered by it. (3) Finally, color the walls of the heart and layers of pericardium at lower left. The pericardial cavity has been greatly exaggerated for coloring. It is normally only a potential space.

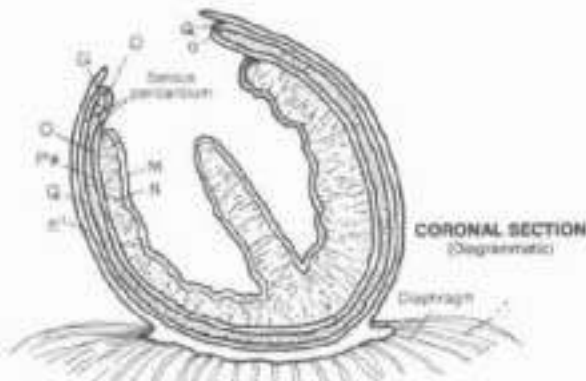


**ANTERIOR VIEW**  
 (Lungs retracted to visualize deeper structures)

The mediastinum (median septum or partition) is a highly populated region between and excluding the lungs. A variety of passageways, nerves, and vessels enter, pass through, and exit the mediastinum. For descriptive purposes, the mediastinum is divided into the subdivisions (regions) illustrated. The superior mediastinum is remarkable for the array of great vessels of the heart, and the trachea, esophagus, vagus and phrenic nerves. At the level of the T4-T5 vertebrae (superior/inferior mediastinal border), the trachea bifurcates into the main bronchi (see Plate 95) posterior to the great vessels, and the aorta makes its arch. The posterior mediastinum includes the inferior continuation of the esophagus embraced by a fine network of vagal nerve fibers, the thoracic duct (see Plate 83), and the descending (thoracic) aorta. The floor of the mediastinum is the diaphragm, penetrated by the thoracic aorta, esophagus, and inferior vena cava.

The heart wall consists of an inner layer of simple squamous epithelium (endocardium) overlying a variably thick myocardium (cardiac muscle). External to the myocardium is a three-layered sac (pericardium). The innermost layer of this sac is the visceral pericardium (epicardium), coating the heart. At the origin of the aortic arch, this layer turns (reflects) outward to become the parietal pericardium (imagine a fist clutching the edges around the opening of a paper bag; now push the fist into the closed bag still clutching the edges; as you do so, note that your fist becomes surrounded by two layers of the paper bag, yet is not inside the bag itself). The relationship of your fist to the two layers of the bag is the relationship of the heart to the visceral and parietal pericardium. The cavity of the bag is empty—the fist is not in the bag (if you did it right). Similarly, the pericardial cavity between the two pericardial layers is empty as well, except for serous fluid that makes for friction-free movement of the heart in its sac.

The fibrous pericardium is the outer surface of the parietal pericardium; it is fibrous and fatty, and is strongly attached to the sternum, the great vessels, and the diaphragm. It keeps the heaving, contracting, squeezing heart within the middle mediastinum.



**CORONAL SECTION**  
 (Diagrammatic)

**WALLS OF THE HEART/PERICARDIUM:**

**ENDOCARDIUM**  
**MYOCARDIUM**  
**VISCERAL PERICARDIUM**  
**PERICARDIAL CAVITY**  
**PARIETAL PERICARDIUM**  
**FIBROUS PERICARDIUM**



# VI. CARDIOVASCULAR SYSTEM

## CHAMBERS OF THE HEART

Ch. Use blue for A, red for H, and your lightest colors for B, C, I, and J.  
(1) Begin with the four chambers of the heart, and follow the direction of blood flow as you color your way down the list of titles. Also color the directional arrows blue (striped) and red, their sites are at lower right. (2) Color the circulation chart below, beginning with numeral one (1) at the right atrium. Color the arrows accordingly along with the four numerals. Do not color the chambers or the vessels.

**SUPERIOR VENA CAVA,**  
**INFERIOR VENA CAVA,**  
**RIGHT ATRIUM.**

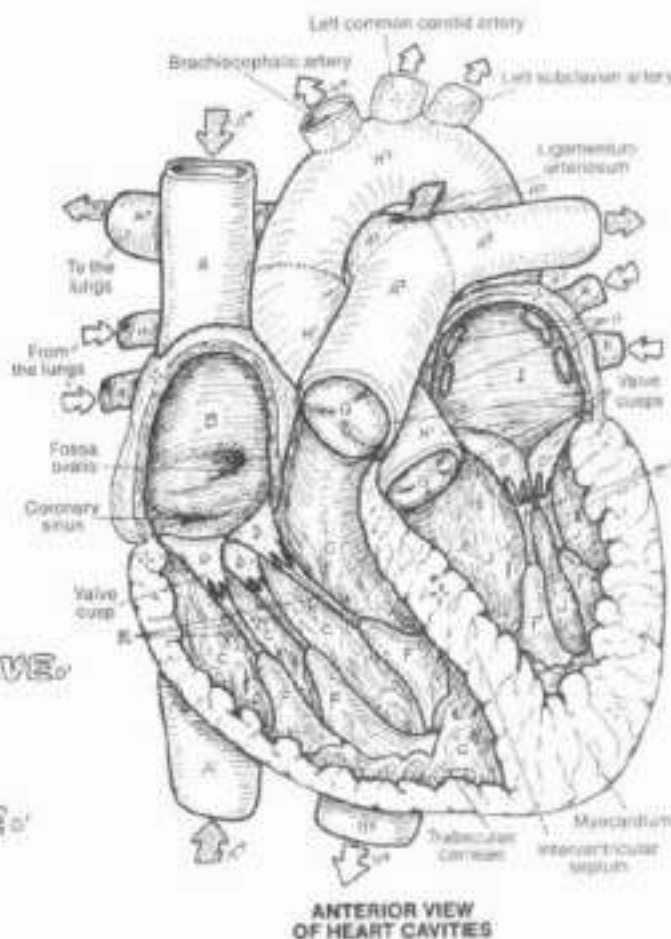
**RIGHT VENTRICLE.**  
**A-V TRICUSPID VALVE.**  
**CHORDAE TENDINEAE.**  
**PAPILLARY MUSCLE.**

**PULMONARY TRUNK,**  
**PUL. SEMILUNAR VALVE.**  
**PUL. ARTERY.**

**PULMONARY VEIN,**  
**LEFT ATRIUM.**

**LEFT VENTRICLE.**  
**A-V BICUSPID (MITRAL) VALVE.**  
**CHORDAE TENDINEAE.**  
**PAPILLARY MUSCLE.**

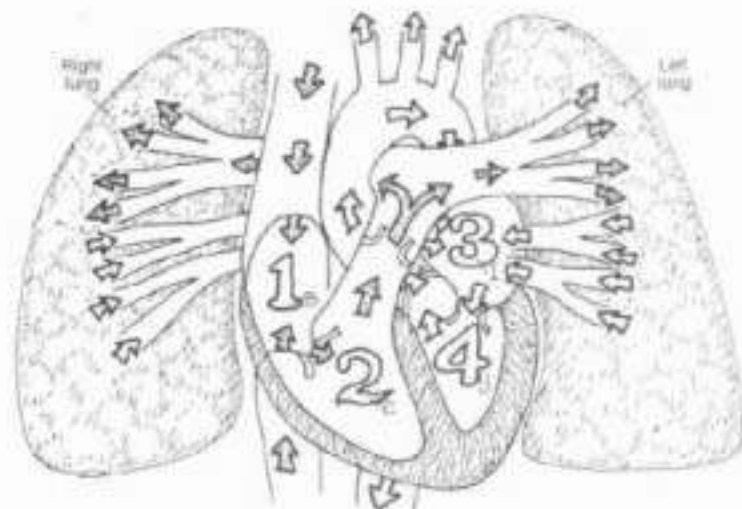
**ASCENDING AORTA,**  
**AORTIC SEMILUNAR VALVE.**  
**AORTIC ARCH,**  
**THORACIC AORTA.**



The heart is the muscular pump of the blood vascular system. It contains four cavities (chambers): two on the right side (pulmonary heart); two on the left (systemic heart). The pulmonary "heart" includes the right atrium and right ventricle. The thin-walled right atrium receives deoxygenated blood from the superior and the inferior vena cava, and from the coronary sinus (draining the heart vessels). The thin-walled left atrium receives oxygenated blood from pulmonary veins. Arterial blood is pumped at a pressure of about 5 mm Hg into the right and left ventricles simultaneously through the atrioventricular orifices, guarded by the 3-cusp tricuspid valve on the right and the 2-cusp bicuspid valve on the left. The cusps are like panels of a parachute, secured to the papillary muscles in the ventricles by tendinous chordae tendineae. These muscles contract with the ventricular muscles, tensioning the cords, and resisting cusp over-flap as ventricular blood bulges into them during ventricular contraction (systole). The ventricles, significantly more muscular than their fellow aorta, pump deoxygenated blood to the lungs via the pulmonary trunk at a pressure of about 25 mm Hg (right ventricle), and into the ascending aorta at a pressure of about 120 mm Hg (left ventricle) simultaneously. This pressure difference is reflected in the thicker walls of the left ventricle compared to the right. The pocket-like pulmonary and aortic semilunar valves guard the trunk and aorta, respectively. As blood falls back toward the ventricle from the trunk/aorta during the "resting phase" (diastole), these pockets fill, closing off their respective orifices, and preventing reflux into the ventricles.

### CIRCULATION THROUGH THE HEART.

**OXYGENATED BLOOD** →  
**DEOXYGENATED BLOOD** →



## VI. CARDIOVASCULAR SYSTEM

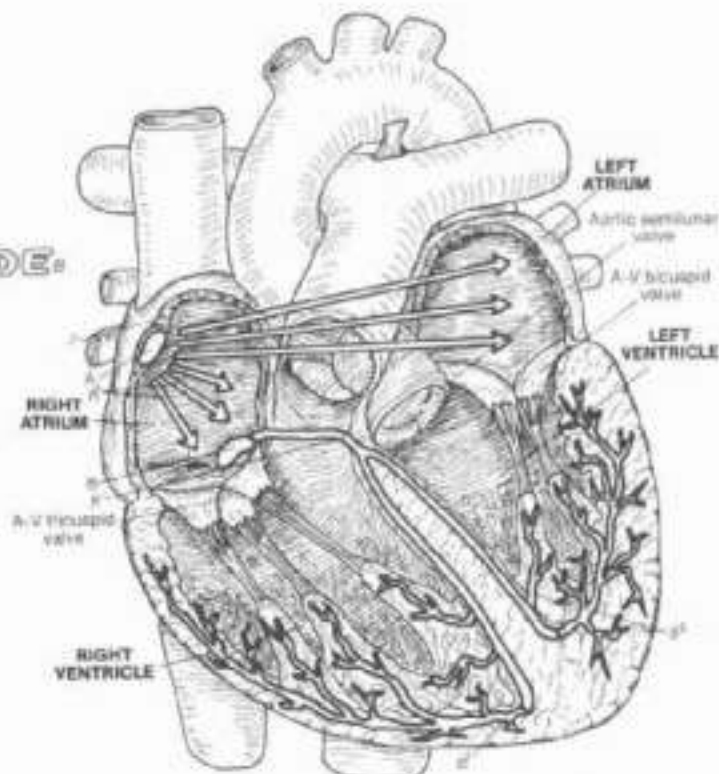
### CARDIAC CONDUCTION SYSTEM & THE ECG

CA Use blue for C and red for D. (1) Begin with the conduction system in the large illustration. (2) Color the waves of the ECG chart and the corresponding drawings illustrating simultaneous events in the heart. The T wave receives both blue and red as it represents the refilling of the atria with deoxygenated (right) and oxygenated blood (left). Be sure to color the large letters as well.

#### CONDUCTION SYSTEM:\*

**SA (SINOATRIAL) NODE,**  
**INTERNODAL TRACT,**  
**AV (ATRIOVENTRICULAR) NODE,**  
**AV BUNDLE,**  
**PURKINJE PLEXUS\***

Contraction of cardiac muscles occurs without motor nerves. Groups of specialized muscle cells conduct electrochemical impulses among the cardiac muscles. These cells constitute the cardiac conduction system. They are more excitable than their cardiac muscle counterparts; thus they are capable of contracting and synchronizing cardiac muscle contraction to permit the movement of blood from atria to ventricles and from ventricles to the pulmonary trunk/ascending aorta. The most excitable cells of the system are in the sinoatrial (SA) node; it is called the "pacemaker" as it sets the pace (or rate) of impulse conduction, the artificial replacement for a diseased, dysfunctional SA node is also called the pacemaker. Impulses travel the internodal tracts through the atrial wall to the atrioventricular (AV) node located in the lower interatrial septum; then through the atrioventricular (AV) bundle in the interventricular septum to and through the Purkinje plexus supplying the ventricular walls. The SA node fires about 45 times a minute. Each cycle of impulse conduction initiates a sequence of coordinated pumping actions by the heart cavities. Contraction of the ventricular muscles constitutes the heart beat, the rate of which is mediated by nerves of the autonomic nervous system.



#### DEOXYGENATED BLOOD.

#### OXYGENATED BLOOD.



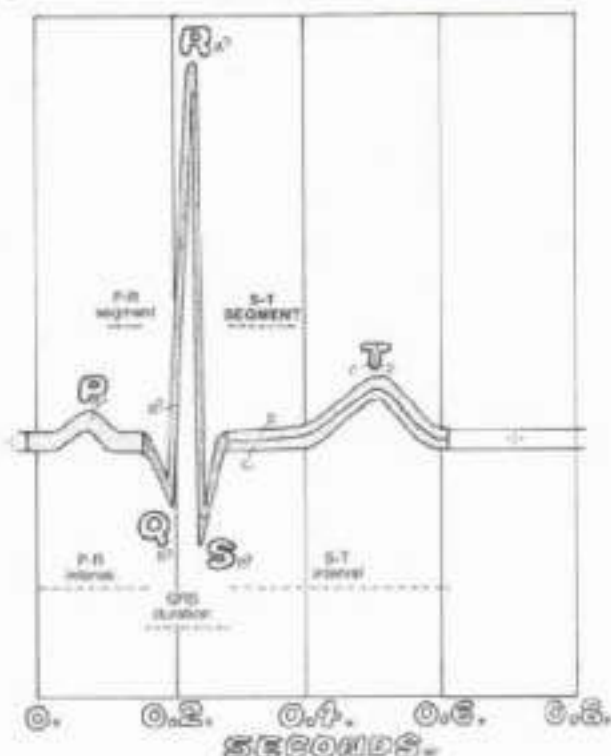
#### ELECTROCARDIOGRAM (ECG):\*

#### P WAVE:\*

#### QRS WAVE (COMPLEX):\*

#### T WAVE:\*

The activity of the conduction system generates electrical activity about the heart, and this activity (specifically voltage changes) can be monitored, assessed, and measured by electrocardiograph machines. The recorded data (various waves of varying voltage over time) from such machines constitute the electrocardiogram (ECG). To gain these data, electrodes are placed on a number of body points on the skin. When the SA node fires, it causes the baseline voltage to drop (depolarize) over both atria, and this is reflected in the ECG by an upward deflection of the baseline voltage (a line produced on an oscilloscope or on a moving paper tape). This upward deflection is called the P wave, which causes the right and left atrial musculature to contract. The AV node takes about 0.1 second to excite the AV bundle, which then conducts the impulses to the Purkinje plexus. The electrical events here constitute the QRS complex of waves. As a result, the ventricles depolarize and the ventricular muscles contract. The T wave represents a period of recovery of baseline voltage (repolarization), following which the atria fill with blood from the vena cava and the pulmonary veins. The ST segment is an especially important indicator of heart muscle function/dysfunction in certain electrode configurations. The shape and direction of wave deflection are dependent upon the spatial relationship of the electrodes (leads) on the body surface.





## VI. CARDIOVASCULAR SYSTEM

### CORONARY ARTERIES & CARDIAC VEINS

CH Use your brightest colors for A, D, and L. (1) When coloring the arteries, include the broken lines which represent vessels on the posterior surface of the heart. (2) Do the same with the veins. (3) Color the artery in front of the papus in the circled area; color the vessel after the plaque a lighter shade of the same color or do not color it at all.

#### CORONARY ARTERIES:

**RIGHT CORONARY ARTERY:**

**MUSCULAR BRANCH:**

**MARGINAL BRANCH:**

**POSTERIOR INTERVENTRICULAR  
(DESCENDING) BRANCH:**

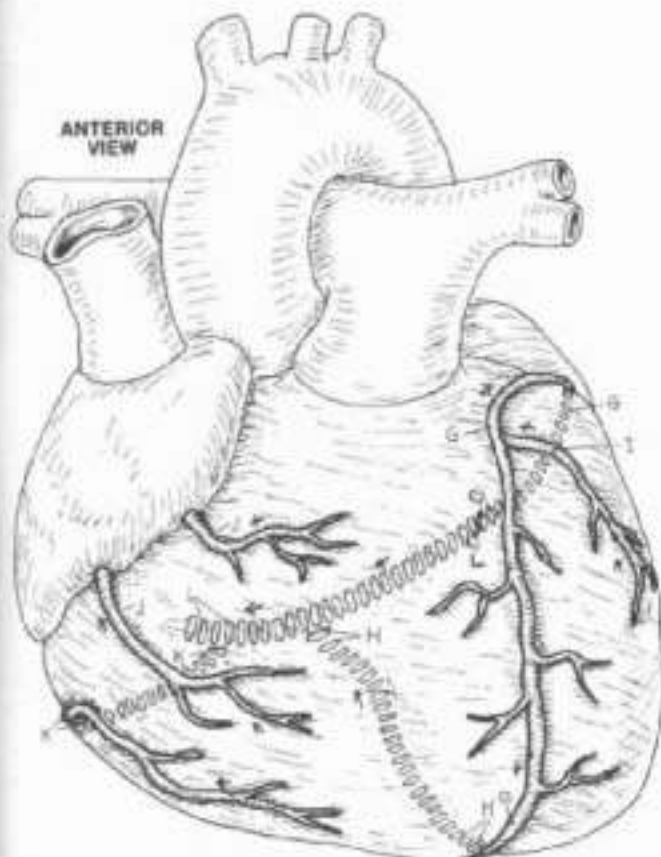
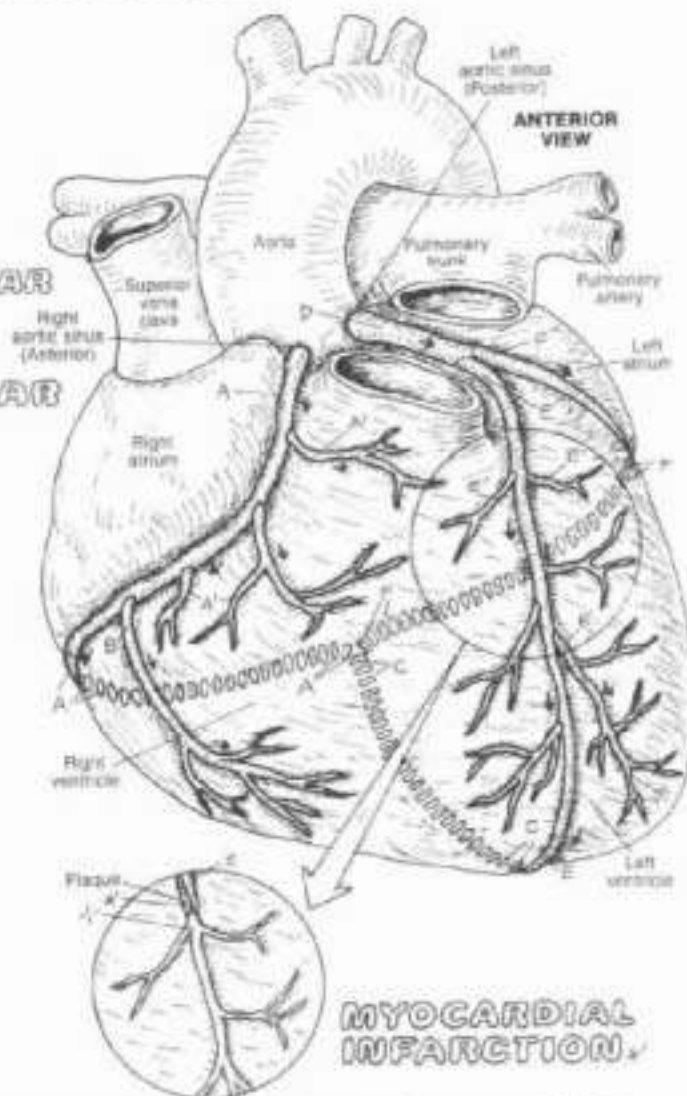
**LEFT CORONARY ARTERY:**

**ANTERIOR INTERVENTRICULAR  
(DESCENDING) BRANCH:**

**MUSCULAR BRANCH:**

**CIRCUMFLEX BRANCH:**

The coronary arteries form an upside down crown (L. corona) about or just deep to the surface of the heart. The arteries lie in grooves or sulci, often covered over by the epicardium and sometimes the myocardium as well. Both left and right arteries arise from small openings (aortic sinuses) just above the two aortic semilunar valve cusps. Generally, the left coronary artery is somewhat larger than the right; the flow rate through the left is greater in most people than that through the right during the cardiac cycle. There may be considerable variation in the anastomotic pattern of the left and right arterial branches. These branches terminate in multitudes of arterioles supplying the vast capillary network among the muscle fibers. The apparent multiple communications among the left and right coronary arteries notwithstanding, varying degrees of vascular insufficiency occur when there is significant obstruction of one or both coronary arteries. There is some extra-coronary arterial supply to the heart from the epicardial vessels (branches of internal thoracic arteries) and aortic vasa vasorum.



Insufficient oxygenation (hypoxia) of the myocardium occurs with significantly reduced blood flow to the muscle (ischemia), often inducing sharp, crushing chest pain (angina pectoris). About 75% or more obstruction by atherosclerotic plaque (thromb) can cause myocardial damage (myocardial infarction). Significant plaque in the artery to the sinoatrial node (not shown) can cause arrhythmias in the cardiac conduction system, often necessitating the installation of an artificial pacemaker in the chest.

#### CARDIAC VEINS:

**GREAT CARDIAC V.:**

**MIDDLE CARDIAC V.:**

**MARGINAL V.:**

**ANTERIOR CARDIAC V.:**

**SMALL CARDIAC V.:**

**CORONARY SINUS.**

The cardiac veins travel with the coronary arteries, but incompletely. Vast anastomoses of veins occur throughout the myocardium; most drain into the right atrium by way of the coronary sinus. The anterior cardiac veins conduct blood directly into the right atrium. Other small veins may drain directly into the right atrium as well. Some deep (arteriovenous) veins drain directly into the atria and ventricles. Extracardiac venous drainage can also occur through the vasa vasorum of the vena cavae.



# VI. CARDIOVASCULAR SYSTEM

## ARTERIES OF THE HEAD & NECK

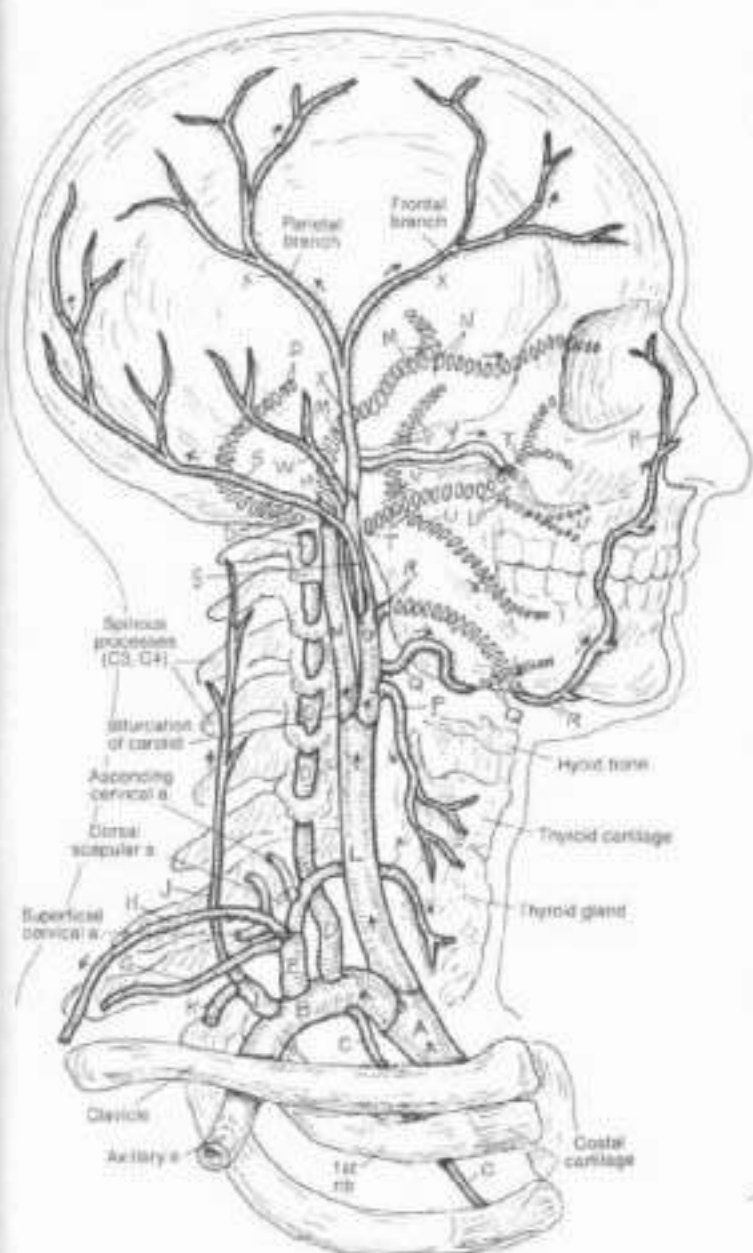
Color the red for A and dark or bright colors for B and C. (1) Begin with the brachiocephalic (A) and the right subclavian (B) and its branches. Color the broken lines which repre-

sent deeper vessels. (2) Do the same for the right common carotid (L) and its branches. (3) Color the arrows pointing to the four sites where the arterial pulse may be palpated.

### BRACHIOCEPHALIC.

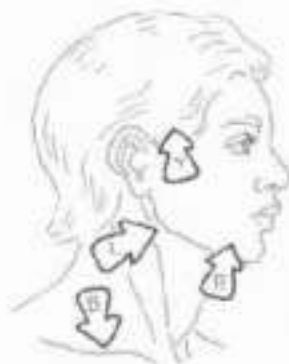- RIGHT SUBCLAVIAN.
- INTERNAL THORACIC.
- VERTEBRAL.
- THYROCERVICAL TRUNK:
- INFERIOR THYROID.
- SUPRASCAPULAR.
- TRANSVERSE CERVICAL.
- COSTOCERVICAL TRUNK:
- DEEP CERVICAL.
- HIGHEST INTERCOSTAL.

- RIGHT COMMON CAROTID.
- INTERNAL CAROTID.
- OPHTHALMIC.
- EXTERNAL CAROTID.
- SUPERIOR THYROID.
- LINGUAL.
- FACIAL.
- OCIPITAL.
- MAXILLARY.
- ALVEOLAR BRANCHES:
  - INF.
  - SUP.
- MIDDLE MENINGEAL.
- POSTERIOR AURICULAR.
- SUPERFICIAL TEMPORAL.
- TRANSVERSE FACIAL.



The subclavian artery is the major source of blood to the upper limb, and contributes vessels to the lateral and posterior neck and shoulder. On the right, the artery springs from the brachiocephalic; on the left, the artery comes directly off the aortic arch as does the common carotid (Plate 73). The vertebral artery dives deep into the neck to find and enter the transverse foramen of the 6th cervical vertebra. It supplies vessels to the spinal cord, brain stem, and cerebellum. The thyrocervical trunk arises just medial to the anterior scalene muscle (see Plate 40) and immediately gives off its branches, the destinations of which are obvious by name. The subclavian artery ends and the axillary artery begins at the lateral border of the first rib.

The common carotid artery ascends the neck ensheathed with the internal jugular vein and vagus nerve (not shown). Between the hyoid bone and the upper thyroid cartilage, the artery bifurcates into internal and external carotid arteries. The internal carotid passes into the skull, gives off the ophthalmic artery to the orbital region and joins the circle of Willis (Plate 70). The external carotid artery and its branches supply all of the visceral, musculo-skeletal, and dental structures of the head and neck less the brain and orbit. The external carotid divides into maxillary and superficial temporal arteries. The maxillary artery is a major source of blood to the deep skull cavities, the orbit, teeth, the muscles of mastication, and the dura mater (middle meningeal artery). The middle meningeal artery on the dura mater immediately deep to the temporal bone is a potential site of rupture with a hard fall on the side of the head (epidural hematoma).



**PULSE SITES.**

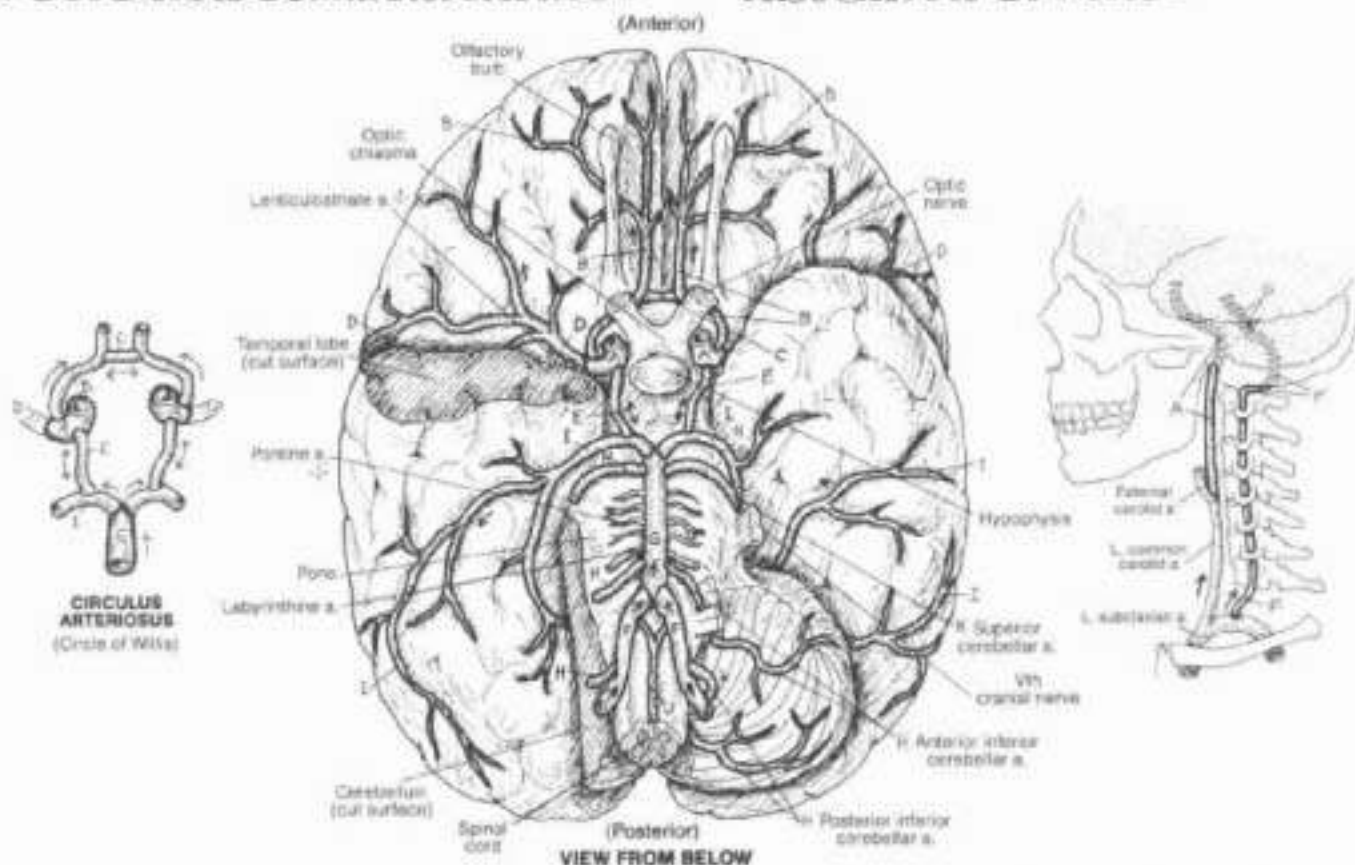
# VI. CARDIOVASCULAR SYSTEM

## ARTERIES OF THE BRAIN

CA. Use red for A and dark or bright colors for F and G. (1) Begin with the internal carotid (A) and related arteries. Color all illustrations simultaneously as you proceed through the titles. (2) Do the same for the vertebral artery and its branches.

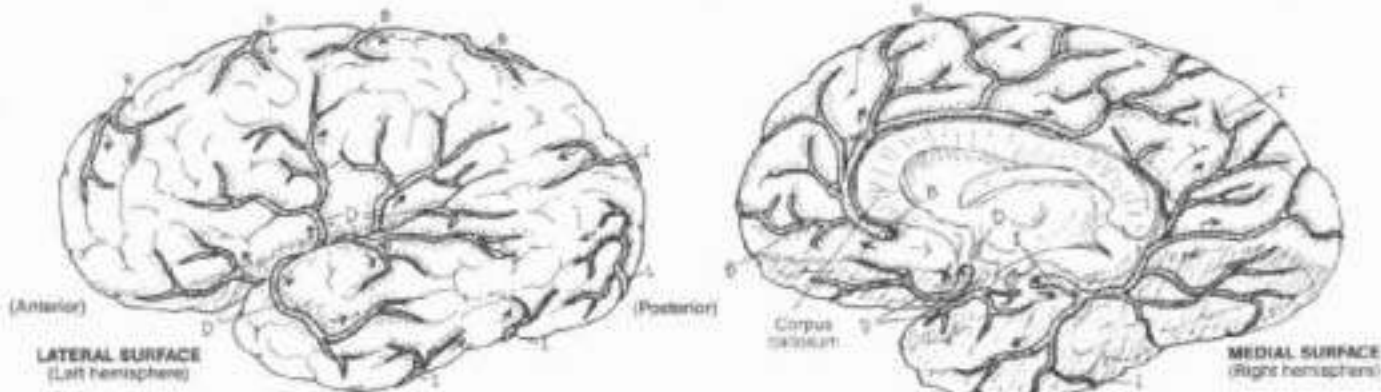
**INTERNAL CAROTID A.**  
**ANTERIOR CEREBRAL A.**  
**ANTERIOR COMMUNICATING A.**  
**MIDDLE CEREBRAL A.**  
**POSTERIOR COMMUNICATING A.**

**VERTEBRAL A.**  
**BASILAR A.**  
**CEREBELLAR A.**  
**POSTERIOR CEREBRAL A.**  
**ANTERIOR SPINAL A.**



The paired *internal carotid arteries* pass up through the carotid canals of the temporal bones, curve within the base of the skull (petrous part), travel through the cavernous sinuses (cavernous part), and divide into the anterior and middle cerebral arteries just lateral to the crossing of the optic nerves (cerebral part). Small lenticulostriate arteries come off the middle cerebral at right angles, supplying the basal ganglia. These "stroke arteries" are commonly the ruptured vessels in intracerebral hemorrhage, often resulting in at least partial paralysis of the limb muscles on the side of the body contralateral to the hemorrhage. Note the

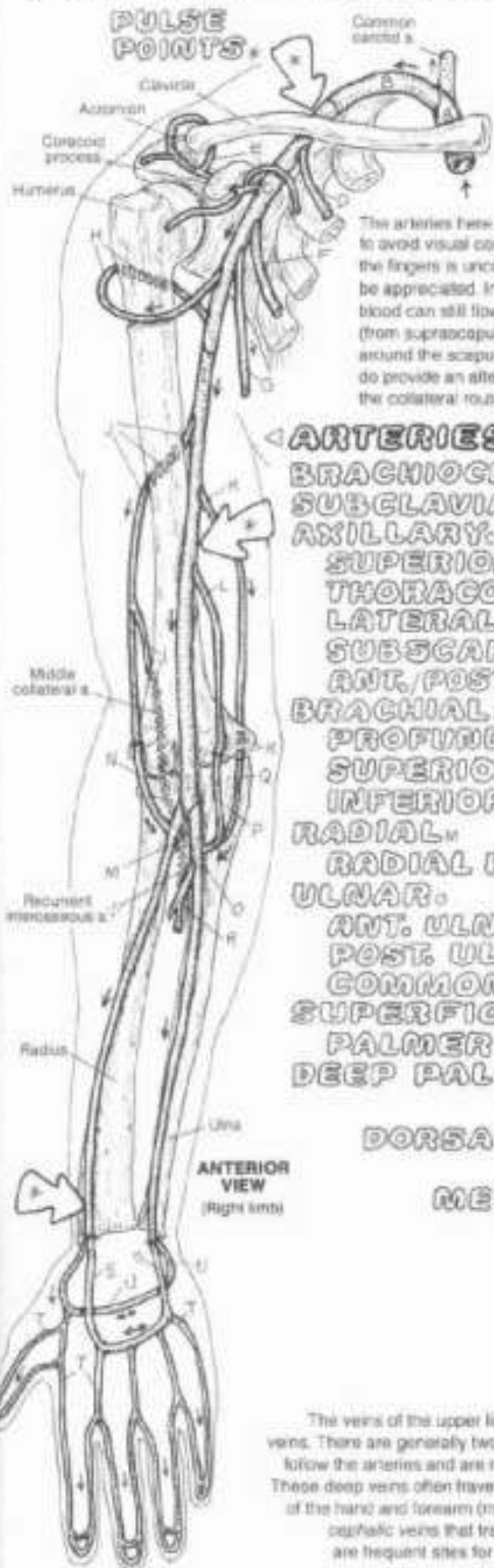
anastomosis permitting blood from the internal carotids to mix with that of the vertebrals. Note how these vessels form an irregular vascular circle (circulus arteriosus; circle of Willis). There is considerable variation in the size of the communicating vessels, casting some doubt on the functional significance of these interconnections of the arterial circle. Note the vessels serving the brain stem. You can see that cerebral hemorrhages usually involve the carotid system, while brain stem infarcts relate to the vertebral system. Note that a major supplier of the spinal cord (anterior spinal artery) comes off the vertebral arteries as well.



# VI. CARDIOVASCULAR SYSTEM

## ARTERIES & VEINS OF UPPER LIMB

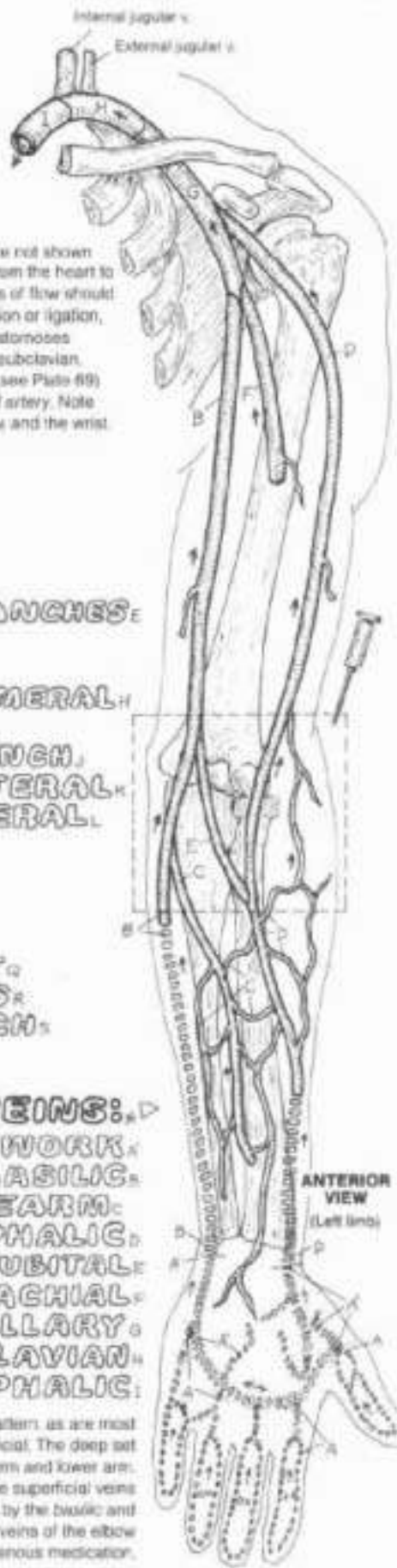
### PULSE POINTS.



Div. Use red for A (under the title arteries) and blue for V (under the title veins). You can repair colors, but do not use the same color for an artery and its corresponding vein. Color the arterial pulse point arrows gray. Broken lines represent veins on the posterior surface.

The arteries here are major ones, their multiple branchings are not shown to avoid visual congestion. Although the basic arterial route from the heart to the fingers is uncomplicated, the existence of collateral routes of flow should be appreciated. In the event of subclavian or axillary obstruction or ligation, blood can still flow to the distal extremities. The scapular anastomoses (from supraclavicular and superficial cervical branches of the subclavian, around the scapula to the subscapular branch of the axillary; see Plate 69) do provide an alternate means of getting blood to the brachial artery. Note the collateral routes about the neck of the humerus, the elbow and the wrist.

- ARTERIES:
  - BRACHIOCEPHALIC.
  - SUBCLAVIAN.
  - AXILLARY.
  - SUPERIOR THORACIC.
  - THORACO-ACROMIAL & BRANCHES.
  - LATERAL THORACIC.
  - SUBSCAPULAR.
  - ANT./POST. CIRCUMFLEX HUMERAL.
  - BRACHIAL.
  - PROFUNDA BRACHII & BRANCH.
  - SUPERIOR ULNAR COLLATERAL.
  - INFERIOR ULNAR COLLATERAL.
  - RADIAL.
  - RADIAL RECURRENT.
  - ULNAR.
  - ANT. ULNAR RECURRENT.
  - POST. ULNAR RECURRENT.
  - COMMON INTEROSSEOUS.
  - SUPERFICIAL PALMER ARCH.
  - PALMER DIGITAL.
  - DEEP PALMER ARCH.



### VEINS:▷

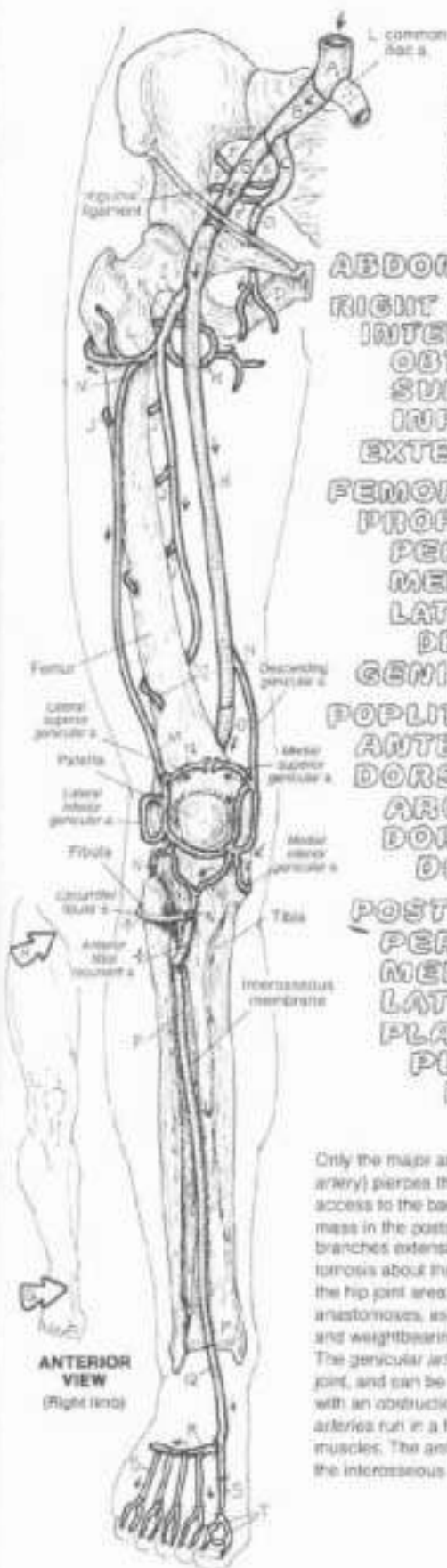- DORSAL DIGITAL & NETWORK.
- BASILIC.
- MEDIAN V. OF FOREARM.
- CEPHALIC.
- MEDIAN CUBITAL.
- BRACHIAL.
- AXILLARY.
- SUBCLAVIAN.
- BRACHIOCEPHALIC.

The veins of the upper limb are quite variable in their number and pattern, as are most veins. There are generally two sets of veins in the limb: deep and superficial. The deep set follow the arteries and are not shown in the anterior aspect of the forearm and lower arm. These deep veins often travel in pairs (venae comitantes, not shown). The superficial veins of the hand and forearm (many observable under the skin) are drained by the basilic and cephalic veins that travel in the superficial fascia. The superficial veins of the elbow are frequent sites for blood sampling and administration of intravenous medication.



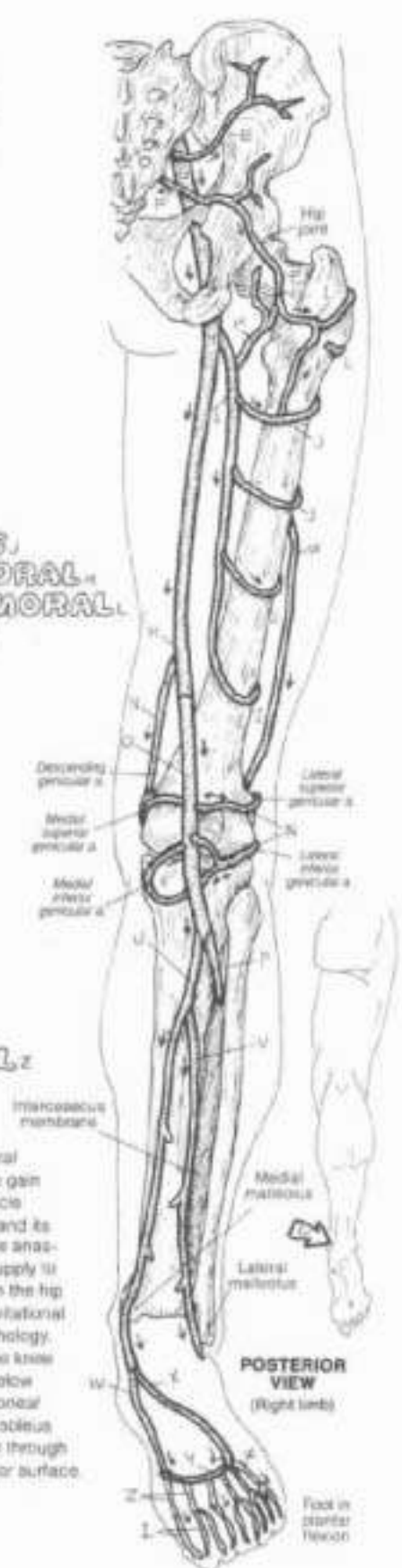
# VI. CARDIOVASCULAR SYSTEM

## ARTERIES OF THE LOWER LIMB



ON: Use red for A. (1) Work both views of the lower limb simultaneously. Color the parts of the genicular artery (A) so it forms a pattern around the knee joint. Also part of that anastomosis, but not to be colored, are the circumflex tibial and the anterior tibial recurrent arteries. (2) The foot in the posterior view is plantar flexed with the sole showing. (3) Color the three puzator parts.

- ABDOMINAL AORTA:
- RIGHT COMMON ILIAC:
- INTERNAL ILIAC:
- OSTIUM:
- SUPERIOR GLUTEAL:
- INFERIOR GLUTEAL:
- EXTERNAL ILIAC:
- FEMORAL:
- PROFUNDA FEMORIS:
- PERFORATING BRANCHES:
- MEDIAL CIRCUMFLEX FEMORAL:
- LATERAL CIRCUMFLEX FEMORAL:
- DESCENDING BRANCH:
- GENICULAR:
- POPLITEAL:
- ANTERIOR TIBIAL:
- DORSALIS PEDIS:
- ARCUATE:
- DORSAL METATARSAL:
- DORSAL DIGITAL:
- POSTERIOR TIBIAL:
- PERONEAL:
- MEDIAL PLANTAR:
- LATERAL PLANTAR:
- PLANTAR ARCH:
- PLANTAR METATARSAL:
- PLANTAR DIGITAL:



Only the major arteries are shown here. The artery of the thigh (femoral artery) pierces the medial muscular compartment (adductor canal) to gain access to the back of the knee and leg. Due to the considerable muscle mass in the posterior thigh, the profunda femoris artery is quite large and its branches extensive. Note how the circumflex arteries contribute to the anastomosis about the hip (femoral head and neck, hip joint). The blood supply to the hip joint area can be compromised due to congenital anomalies in the hip anastomoses, as well as degenerative and traumatic processes. Gravitational and weightbearing factors can be important mediators in hip joint pathology. The genicular arteries form a significant anastomotic pattern about the knee joint, and can be an important source of blood flow to the knee and below with an obstruction of the popliteal artery. The posterior tibial and peroneal arteries run in a fascial compartment, deep to the gastrocnemius and soleus muscles. The anterior tibial artery exits the posterior leg compartment through the interosseous membrane and descends on the membrane's anterior surface.

## VI. CARDIOVASCULAR SYSTEM

### AORTA & BRANCHES; INTERCOSTAL ARTERIES

CS: Use red for A and use light, bright colors for B, J, L and L. (1) When coloring the posterior intercostal arteries (K) under the thoracic aortic section, color all the arteries even though only a few are labeled. (2) In the abdomen, note the location of the inferior phrenic, suprarenal, middle sacral, internal iliac, and external iliac arteries, none of which are to be colored. Also note the inferior vena cava (striped) which echoes the shape of the abdominal aorta.

#### AORTIC ARCH

CORONARY,

BRACHIOCEPHALIC,

COMMON CAROTID,

SUBCLAVIAN,

INTERNAL THORACIC,

MUSCULOPHRENIC,

SUPERIOR EPIGASTRIC,

COSTOCERVICAL TRUNK,

HIGHEST INTERCOSTAL.

#### THORACIC AORTA

BRONCHIAL,

ESOPHAGEAL,

POSTERIOR INTERCOSTAL.

#### ABDOMINAL AORTA

CELIAC TRUNK,

LEFT GASTRIC,

SPLenic,

COMMON HEPATIC,

SUPERIOR MESENTERIC,

RENAL,

TESTICULAR / OVARIAN,

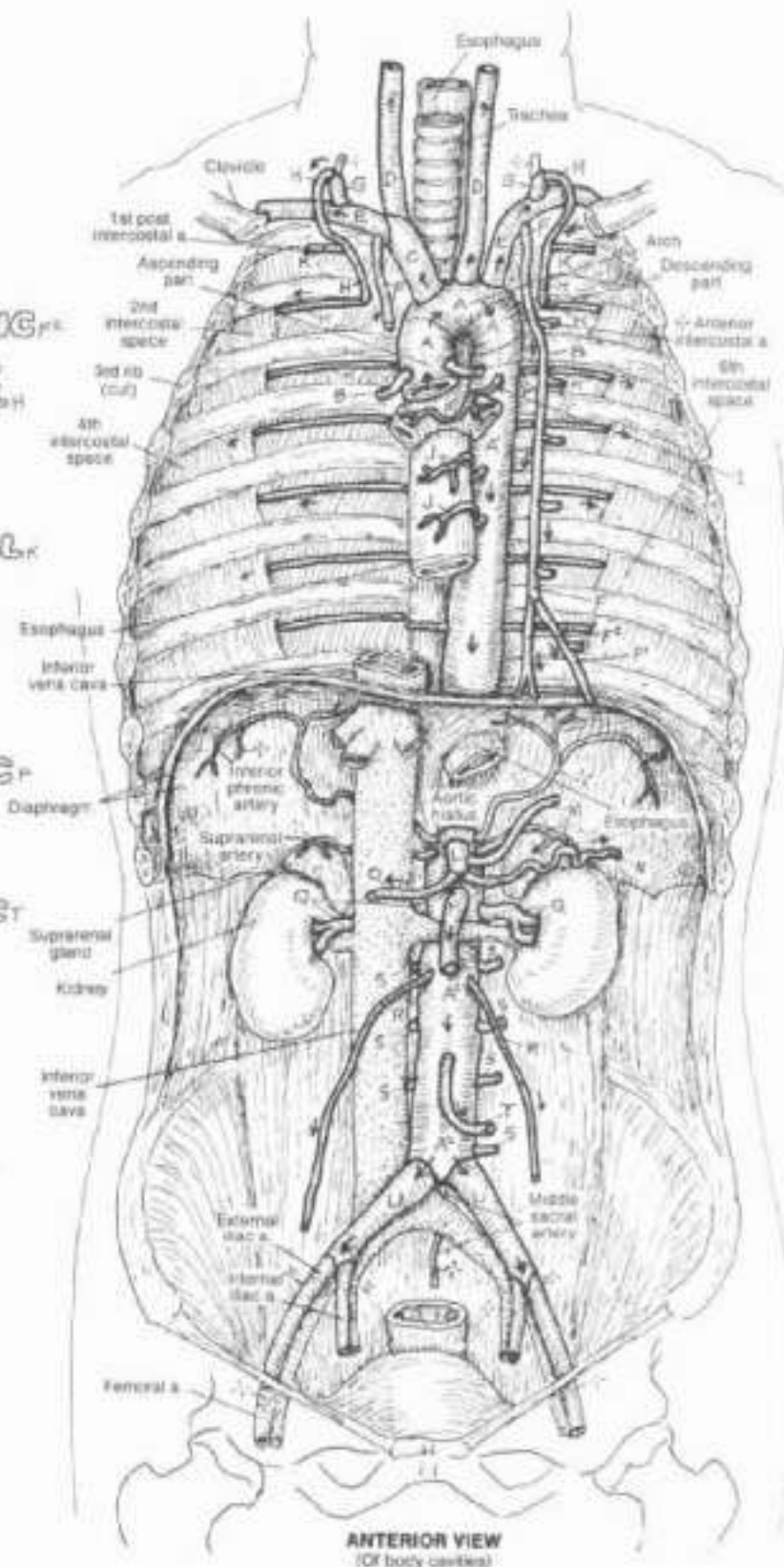
LUMBAR,

INFERIOR MESENTERIC,

COMMON ILIAC.

The branches of the aortic arch are unpaired except for the coronary arteries/arteries. The branches of the thoracic aorta are paired. The bronchial arteries supply the lung tissues with oxygenated blood. Branches of the abdominal aorta are usually described as visceral and parietal. The visceral arteries are both single and paired; note the vessels to the gastrointestinal tract are unpaired. Parietal branches of the abdominal aorta (lumbar arteries) are segmental and bilateral, in register with the segmental and bilateral posterior intercostals and subcostals of the thoracic aorta.

There are 9 intercostal spaces anteriorly (not shown), and 11 posteriorly (due to the floating ribs 11 and 12, not shown). These spaces are supplied by both anterior and posterior intercostal arteries. The posterior intercostals for spaces 1 and 2 are branches of the highest (supreme, superior) intercostal artery from the costocervical trunk. The posterior intercostals for spaces 3-11 come directly off the thoracic aorta. The subcostal arteries (not shown) run inferiorly to the 12th rib, posterior to the diaphragm. The paired first lumbar arteries (not shown) leave the abdominal aorta immediately below the diaphragm. The anterior intercostals arise from the internal thoracic artery for the first 6 intercostal spaces, then the latter artery bifurcates into superior epigastric and musculophrenic branches. The musculophrenic artery supplies the lower 3 intercostal spaces.



## VI. CARDIOVASCULAR SYSTEM

74  
See 129

### ARTERIES TO GASTROINTESTINAL TRACT & RELATED ORGANS

CA: Use red for A, and use the same colors for celiac trunk (E), superior mesenteric artery (L), and inferior mesenteric artery (Q) that you used for those structures on Plate 72, where they had different subscripts.

(1) Begin with the large illustration. Note that the two pancreaticoduodenal arteries (H, H') receive the same color. (2) Color the upper illustration which summarizes the 3 sources of blood supply to the digestive system.

#### AORTA:

#### CELIAC TRUNK:

HEPATIC: COMMON / LEFT / RIGHT:

RIGHT GASTRIC:

GASTRODUODENAL:

R. GASTROEPIPLOIC:

L. GASTROEPIPLOIC:

PANCREATICO-DUODENAL (SUP.)

CYSTIC:

LEFT GASTRIC:

SPLenic:

The celiac trunk, the first single visceral artery off the abdominal aorta, is a very short vessel that divides immediately into arteries to the liver, spleen, and stomach. Only the major branches of these three arteries are shown here. Note the anastomotic pattern of arteries to the stomach. The blood supply to the pancreas can be better appreciated in Plate 129.

#### SUPERIOR MESENTERIC:

PANCREATICO-DUODENAL (INF.)

MIDDLE COLIC:

RIGHT COLIC:

ILEO-COLIC:

BRANCHES TO SMALL INTESTINE:

The superior mesenteric artery supplies most of the small intestine, head of the pancreas, cecum, ascending colon, and part of the transverse colon. It travels in the common mesentery. Notice the collateral circulation between the celiac and superior mesenteric arteries in the curve of the duodenum. The superior and inferior mesenteric arteries also interconnect via a marginal artery that runs along the length of the large intestine and is fed by both these arteries. The arteries to the ileum/jejunum (cut short) run in the common mesentery.

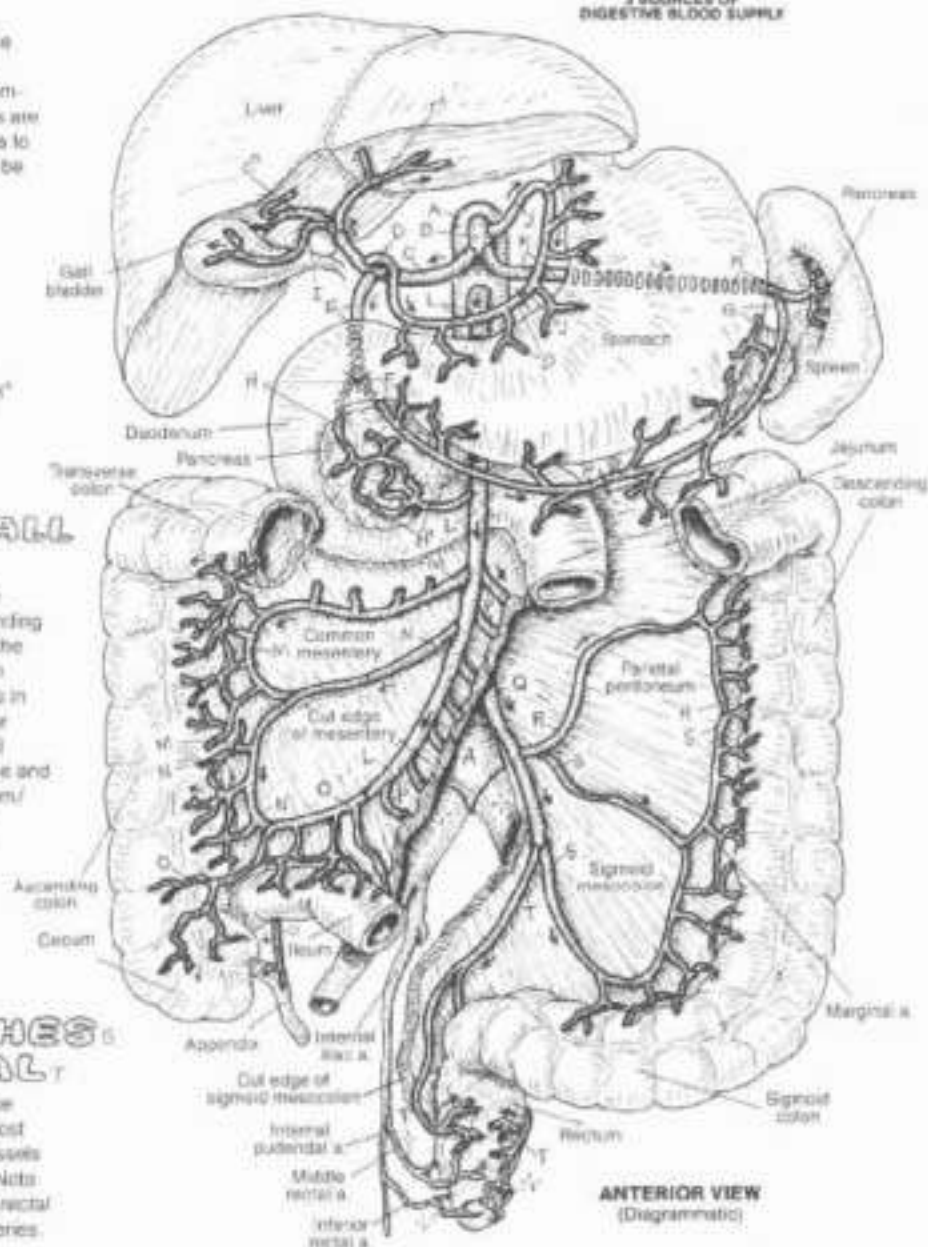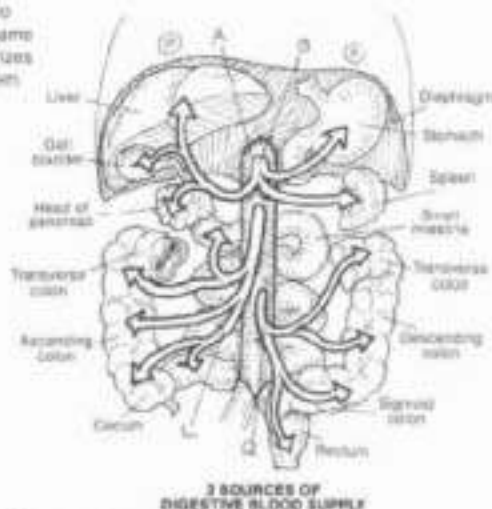
#### INFERIOR MESENTERIC:

LEFT COLIC:

SIGMOID BRANCHES:

SUPERIOR RECTAL:

The inferior mesenteric artery supplies the transverse colon down to the rectum. Its branches lie, for the most part, behind the peritoneum (retroperitoneal); the vessels to the sigmoid colon run in the sigmoid mesocolon. Note the anastomoses between branches of the superior rectal artery and those of the middle and inferior rectal arteries.





# VI. CARDIOVASCULAR SYSTEM

## ARTERIES OF THE PELVIS & PERINEUM

CH. Use a light color for A. (1) Color the medial views of both pelvises simultaneously. Only the disposition of reproductive organs and their vessels varies in these two views. (2) Color both halves of the dissected perineum seen from below. The names of the main vessels can be seen in the medial view.

### PELVIS:

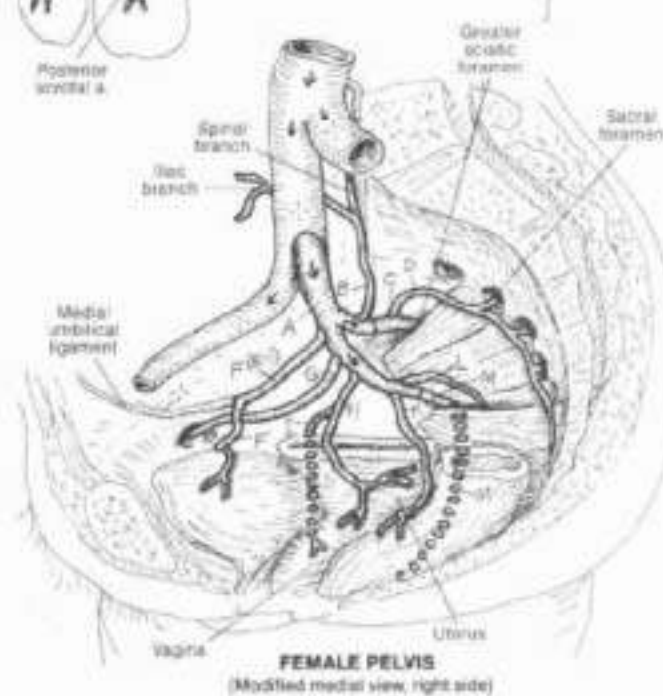
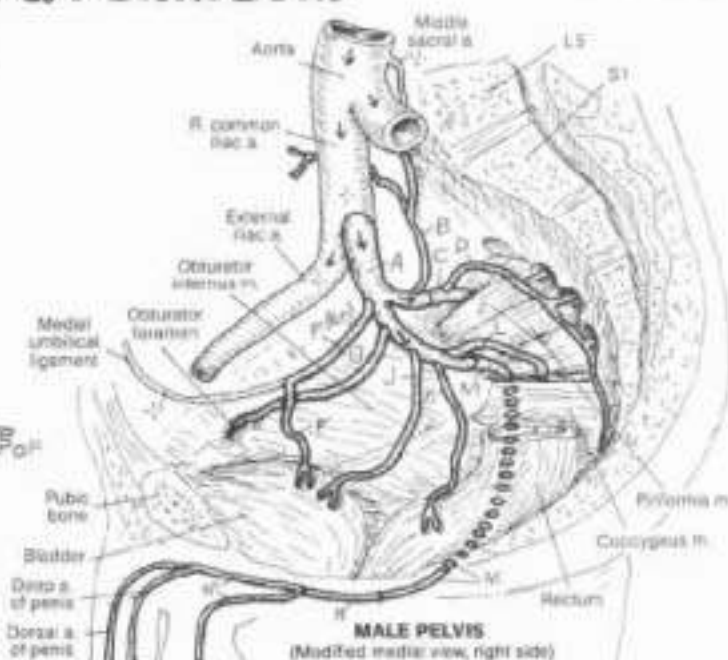
#### INTERNAL ILIAC

##### POSTERIOR TRUNK:

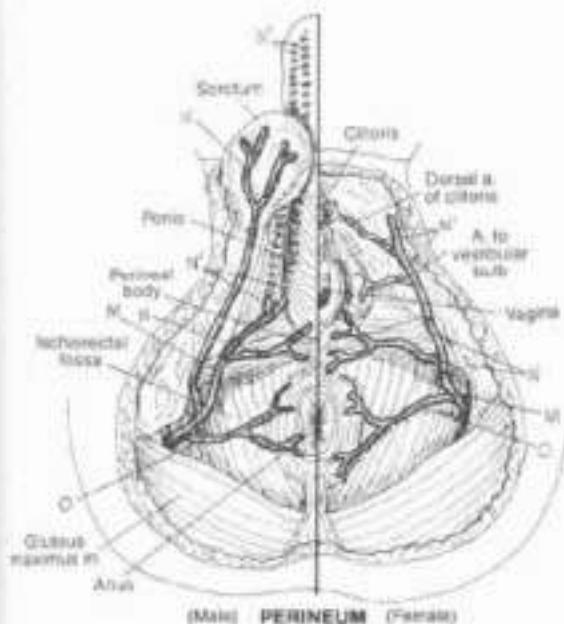
- ILIO LUMBAR,
- SUPERIOR GLUTEAL,
- LATERAL SACRAL,

##### ANTERIOR TRUNK:

- UMBILICAL (FETAL),
- SUP. VESICAL / A. TO VAS DEF.,
- OSTURATOR,
- UTERINE,
- VAGINAL,
- INFERIOR VESICAL,
- MIDDLE RECTAL,
- INFERIOR GLUTEAL.



The internal iliac artery supplies the pelvis and perineum, with some collaterals from the inferior mesenteric and femoral arteries. Its branches are usually organized into posterior (parietal) and anterior (visceral) divisions. The vascular pattern here is variable; the one shown is characteristic. From the posterior trunk, the superior gluteal passes through the greater sciatic foramen above piriformis. The inferior gluteal and pudendal arteries, from the anterior trunk, depart the pelvis through the lesser sciatic foramen below piriformis. Proximal to the formation of these latter two vessels, the anterior trunk of the internal iliac gives off four branches in both male and female: the first is the superior vesical (arising from the proximal part of the fetal umbilical artery; when the umbilical cord is cut, the distal part of the artery atrophies, forming the medial umbilical ligament, the remaining umbilical artery becomes the superior vesical artery, supplying the upper bladder and ductus deferens). The second is the obturator artery to the medial thigh region. The third is the uterine artery, in the male, it is the inferior vesical artery. The vaginal artery comes off the uterine artery. The arteries to the prostate and seminal vesicles (not shown) come off the inferior vesical. The fourth is the middle rectal.



### PERINEUM:

- PUDENDAL,
- PERINEAL / BRANCHES,
- INFERIOR RECTAL.

The external genital structures are supplied by the internal pudendal arteries which pass through the pudendal (fascial) canal alongside the inferior pubic ramus. The arteries (and nerves of the same name) enter the perineum just medial to the ischial tuberosities. The perineal arteries are significant in that they provide the vascular basis for erection of the penis and clitoris in sexual stimulation.

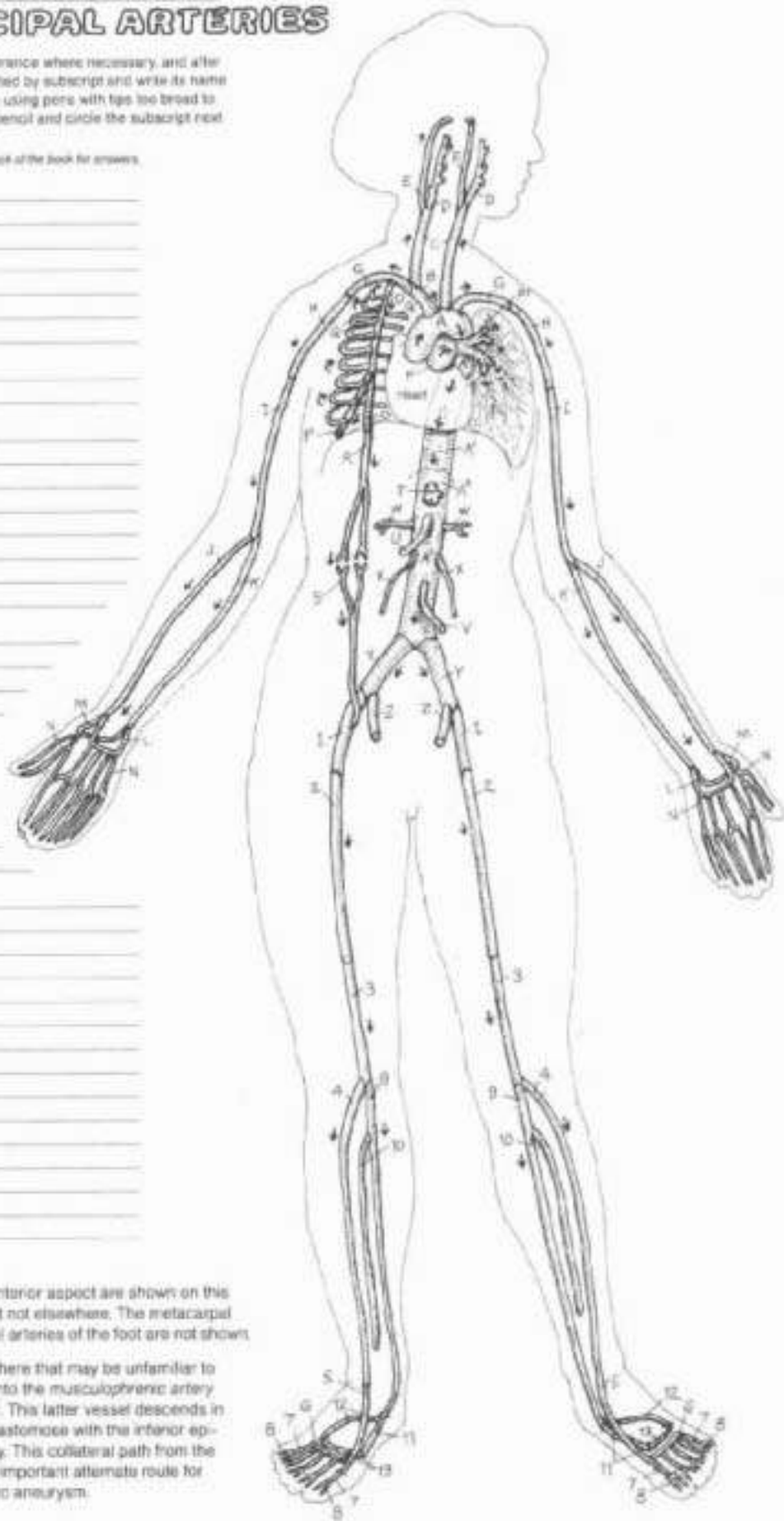
## VI. CARDIOVASCULAR SYSTEM

### REVIEW OF PRINCIPAL ARTERIES

CH. Use red for A. Using the preceding plates as reference where necessary, and after reading the text of this plate, color each artery identified by subscript and write its name in that color in the appropriate space at left. If you are using pens with tips too broad to permit legible writing, write the name of the artery in pencil and circle the subscript next to it with the related color.

See glossary in the back of the book for answers.

- A \_\_\_\_\_  
 A' \_\_\_\_\_  
 A'' \_\_\_\_\_  
 B \_\_\_\_\_  
 C \_\_\_\_\_  
 D \_\_\_\_\_  
 E \_\_\_\_\_  
 F \_\_\_\_\_  
 F' \_\_\_\_\_  
 G \_\_\_\_\_  
 H \_\_\_\_\_  
 I \_\_\_\_\_  
 J \_\_\_\_\_  
 K \_\_\_\_\_  
 L \_\_\_\_\_  
 M \_\_\_\_\_  
 N \_\_\_\_\_  
 O \_\_\_\_\_  
 P \_\_\_\_\_  
 Q \_\_\_\_\_  
 R \_\_\_\_\_  
 S \_\_\_\_\_  
 T \_\_\_\_\_  
 U \_\_\_\_\_  
 V \_\_\_\_\_  
 W \_\_\_\_\_  
 X \_\_\_\_\_  
 Y \_\_\_\_\_  
 Z \_\_\_\_\_  
 1 \_\_\_\_\_  
 2 \_\_\_\_\_  
 3 \_\_\_\_\_  
 4 \_\_\_\_\_  
 5 \_\_\_\_\_  
 6 \_\_\_\_\_  
 7 \_\_\_\_\_  
 8 \_\_\_\_\_  
 9 \_\_\_\_\_  
 10 \_\_\_\_\_  
 11 \_\_\_\_\_  
 12 \_\_\_\_\_  
 13 \_\_\_\_\_

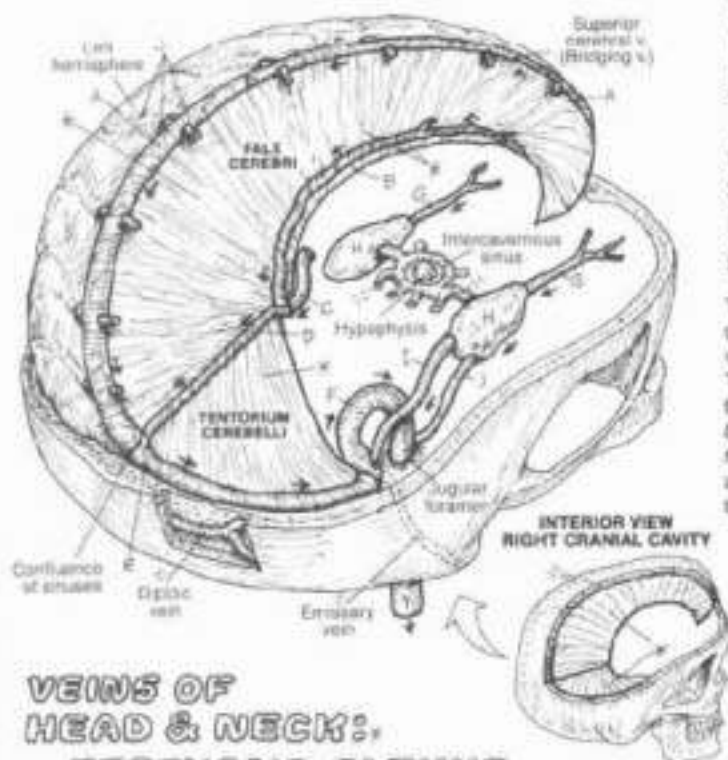


Only the major arteries clearly visible from the anterior aspect are shown on this plate. The arteries are duplicated in the limbs but not elsewhere. The metacarpal arteries, the plantar metatarsal and plantar digital arteries of the foot are not shown.

There is one pair of anastomotic vessels shown here that may be unfamiliar to you: note the *internal thoracic artery* bifurcates into the *musculophrenic artery* and the more medial *superficial epigastric artery*. This latter vessel descends in the sheath of the *rectus abdominis muscle* to anastomose with the *inferior epigastric artery*, a branch of the *external iliac artery*. This collateral path from the heart (indirectly) to the lower limb represents an important alternate route for blood in the event of a seriously obstructing aortic aneurysm.

## VI. CARDIOVASCULAR SYSTEM VEINS OF THE HEAD & NECK

**ON:** Note the order of flow and their indentations. We begin with lists of tributaries, entering them above the vein with which they merge or join. The order is in the direction of flow. It will hold for all parts of the veins. Use lighter colors for the sinuses (A-K), represented in the lateral view by broken lines. (1) Begin with the venous sinuses. When coloring the face and tentorium gray, color lightly over the vessels contained within (A, B, D, and E). Do not color the superior cerebral veins which join the superior sagittal sinus (A). The occipital sinus (K) is shown only in the lateral view.



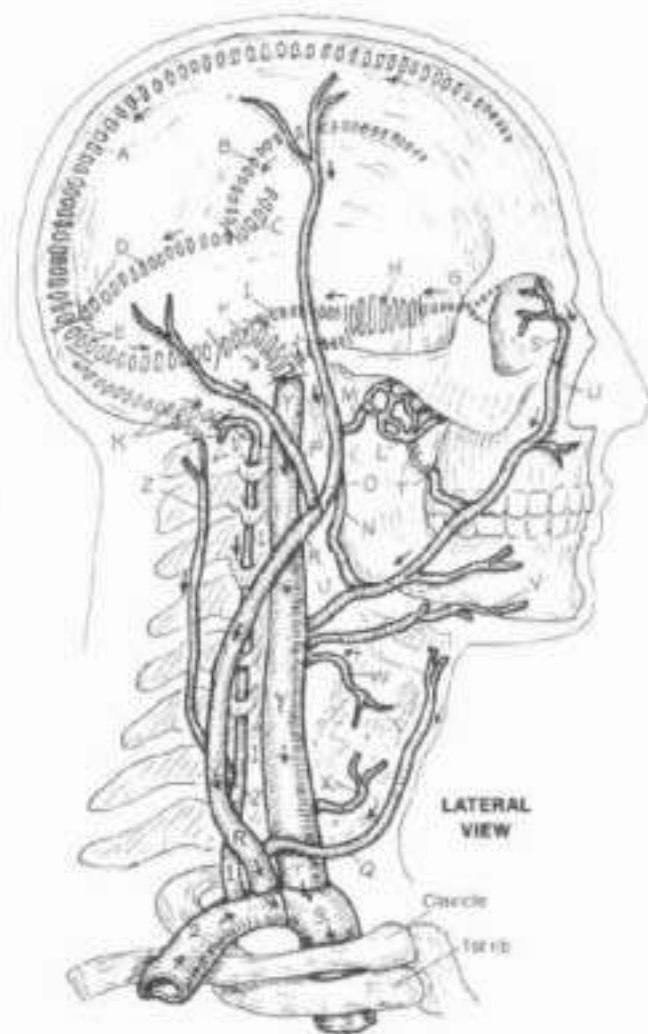
- SINUSES OF DURA MATER:**
- SUPERIOR SACGITTAL SINUS.**
  - INFERIOR SACGITTAL SINUS.**
  - GREAT CEREBRAL V.**
  - STRAIGHT SINUS.**
  - TRANSVERSE SINUS.**
  - SIGMOID SINUS.**
  - SUPERIOR OPHTHALMIC V.**
  - CAVERNOUS SINUS.**
  - SUPERIOR PETROSAL SINUS.**
  - INFERIOR PETROSAL SINUS.**
  - OCCIPITAL SINUS.**

The veins draining the brain are tributaries of large venous channels (cranial dural venous sinuses) in the dura mater. The external cerebral ("bridging") veins drain the cerebral surface and merge with the superior sagittal sinus. They are known to rupture when excessive inertial loads are imposed on the brain (subdural hematoma). Two internal cerebral veins form the great cerebral vein; these drain the deeper hemispheres (subcortical areas). The confluence of merging sinuses (occipital, straight, and superior sagittal) is variable. The cavernous sinus offers significant collateral drainage of blood from the brain. Other collateral veins include the diploic and emissary veins.

### VEINS OF HEAD & NECK:

- PTERYGOID PLEXUS.**
- MAXILLARY.**
- RETROMANDIBULAR.**
- SUPERFICIAL TEMPORAL.**
- POSTERIOR AURICULAR.**
- ANTERIOR JUGULAR.**
- EXTERNAL JUGULAR.**
- ANGULAR.**
- DEEP FACIAL.**
- FACIAL.**
- LINGUAL.**
- SUPERIOR THYROID.**
- MIDDLE THYROID.**
- INTERNAL JUGULAR.**
- DEEP CERVICAL.**
- VERTEBRAL.**
- RIGHT SUBCLAVIAN.**
- RIGHT BRACHIOCEPHALIC.**

The internal jugular veins are the principal vessels draining the venous sinuses, angular veins (draining the superior ophthalmic veins) and the pterygoid plexuses assist. The tributaries of the internal/external jugular veins are variable. The internal jugular vein travels with the common/internal carotid arteries and the vagus nerve, while the external jugular vein can often be seen in the superficial fascia at the side of the neck.





# VI. CARDIOVASCULAR SYSTEM

## CAVAL & AZYGOS SYSTEMS

CV. Use blue for the superior and inferior vena cavae (H, H'). Note that a large segment of the latter has been deleted to reveal the azygos vein (A). Use bright colors for the first posterior intercostal (D) and internal thoracic (F) veins, both of which drain into the brachiocephalic.

### SUPERIOR VENA CAVAL SYSTEM:

- SUPERIOR THYROID,
- MIDDLE THYROID,
- INTERNAL JUGULAR,
- 1ST POSTERIOR INTERCOSTAL,
- INFERIOR THYROID,
- INTERNAL THORACIC,
- R. & L. BRACHIOCEPHALIC,
- SUPERIOR VENA CAVA

### AZYGOS SYSTEM:

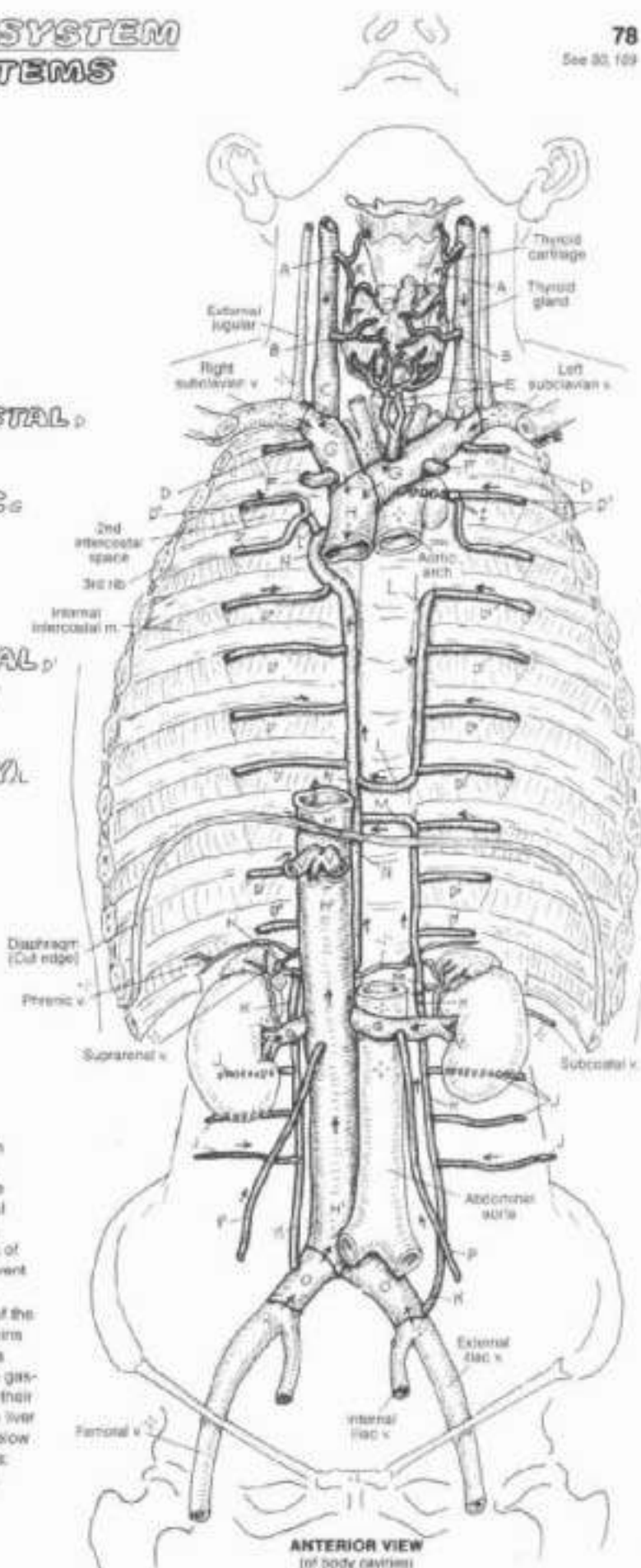
- POSTERIOR INTERCOSTAL,
- SUPERIOR INTERCOSTAL,
- LUMBAR,
- ASCENDING LUMBAR,
- HEMIAZYGOS (ACCESSORY),
- HEMIAZYGOS,
- AZYGOS,

### INFERIOR VENA CAVAL SYSTEM:

- COMMON ILIAC,
- TESTICULAR / OVARIAN,
- RENAL,
- HEPATIC,
- INFERIOR VENA CAVA

The superior vena cava drains the head, neck, and upper limbs. In addition, it drains the intercostal and lumbar regions by way of a remarkable but irregular and variable collection of veins called the azygos system. In conjunction with the veins of the vertebral canal (vertebral venous plexus, not shown), the azygos system (azygos, accessory hemiazygos, and hemiazygos veins) provides a means of returning blood to the heart from the lower limb and trunk in the event of obstruction of the inferior vena cava.

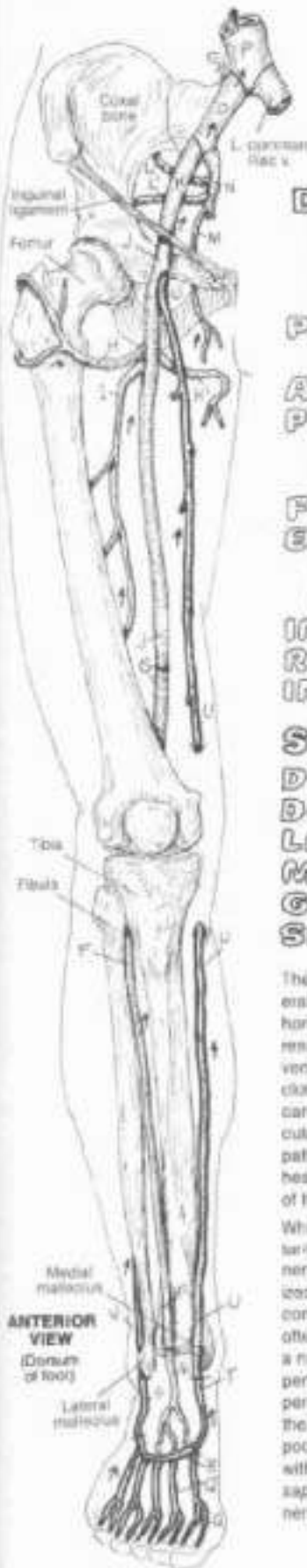The azygos and hemiazygos veins are derived from the merging of the ascending lumbar and subcostal veins. The anterior intercostal veins (not shown) drain into the internal thoracic veins. The inferior vena cava (and azygos) systems have no major tributaries draining the gastrointestinal tract, gall bladder, and pancreas. These viscera have their own venous (portal) system (see Plate 80). However, note that the liver is drained by hepatic veins into the inferior vena cava (IVC) just below the diaphragm. The renal veins enter the vena cava at right angles; note that the left testicular/ovarian veins merge with the left renal vein and that such is not the case on the right.



ANTERIOR VIEW  
(of body cavities)

# VI. CARDIOVASCULAR SYSTEM

## VEINS OF THE LOWER LIMB

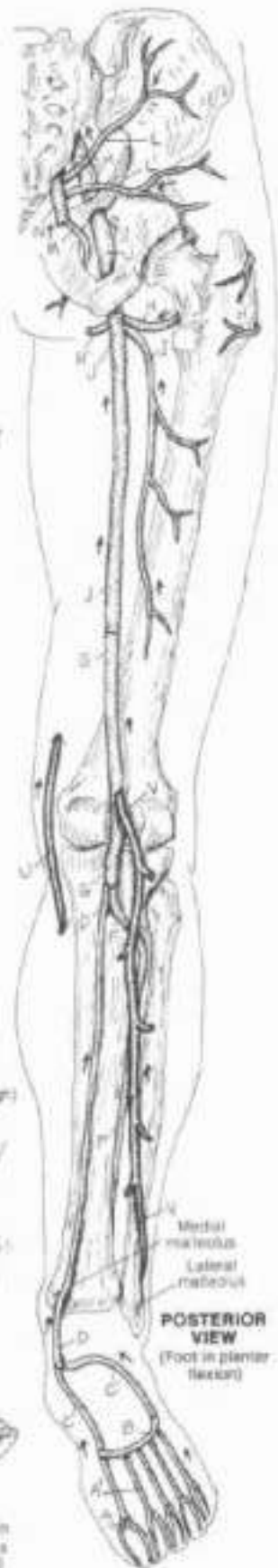
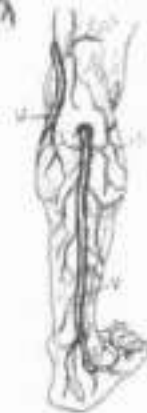
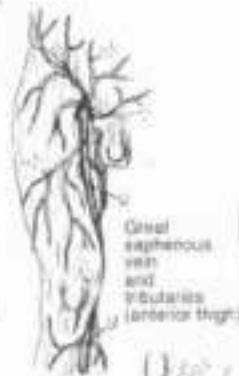ON: Use blue for P and light colors for A-C, the deep veins. Use dark colors for the superficial veins (D-V). (1) Begin with the deep veins and work both views simultaneously. (2) After completing the superficial veins, color the main trunks in each of the small illustrations, but not the fine lines representing their tributaries.

- DEEP VEINS:**  
 PLANTAR DIGITAL / METATARSAL  
 DEEP PLANTAR VENOUS ARCH  
 MED. / LAT. PLANTAR  
 POSTERIOR TIBIAL  
 DORSAL  
 ANTERIOR TIBIAL  
 POPLITEAL  
 LAT. / MED. CIRCUMFLEX FEMORAL  
 PROFUNDA FEMORIS  
 FEMORAL  
 EXTERNAL ILIAC  
 SUPERIOR / INFERIOR GLUTEAL  
 OBTURATOR  
 INTERNAL ILIAC  
 RIGHT COMMON ILIAC  
 INFERIOR VENA CAVA
- SUPERFICIAL VEINS:**  
 DIGITAL / METATARSAL  
 DORSAL VENOUS ARCH  
 LATERAL MARGINAL  
 MEDIAL MARGINAL  
 GREAT SAPHENOUS  
 SMALL SAPHENOUS

The flow of blood in the deep veins of the lower limb is generally an uphill course. In concert with gravity, prolonged horizontal positioning of the legs (and other conditions) can result in slowed flow (stasis) in the deep veins resulting in venous distention and inflammation (phlebitis). Formation of clots in these veins (thrombophlebitis, deep vein thrombosis) can result in clotted fragments being released into the circulation (emboli). These emboli continue up the venous pathway of ever-increasing size, easily pass into the right heart, and are pumped into the progressively smaller vessels of the lung and become stuck (pulmonary embolism).

While deep veins generally follow the arteries (venae comitantes), superficial veins do not. They travel with cutaneous nerves in the superficial fascia and many are easily visualized in the limbs. The blood in these long veins has to overcome gravity for a considerable distance, and their valves often come under weightbearing stress. Happily, there exist a number of communicating vessels (perforating veins, or perforators, not shown) between superficial and deep veins, permitting runoff into the deep veins, significantly offsetting the effect of incompetent valves. Incompetent valves lead to pooling of blood and swelling in the lower superficial veins, with potential inflammation. In the chronic condition, the saphenous veins and their tributaries can become permanently deformed and dysfunctional (varicosities).





# VI. CARDIOVASCULAR SYSTEM

## HEPATIC PORTAL SYSTEM

CA: Use blue for V and a dark color for A. (1) Color the veins draining the intestines, pancreas, gall bladder, and spleen. Note that there are both left and right gastro-epiploic (G, D) and gastric (G, G') veins. Color the darkly outlined directional arrows adjacent to blood vessels the color of the blood vessel. (2) After coloring the inferior vena cava, its tributaries, the tributaries of the superior vena cava, and descending aorta gray, color the three large arrows identifying anastomotic sites (include the esophageal veins passing posterior to the heart).

### HEPATIC PORTAL SYSTEM:

SUPERIOR RECTAL  
INFERIOR MESENTERIC

PANCREATIC  
L. GASTRO-EPIPLOIC

SPLenic

R. GASTRO-EPIPLOIC

SUPERIOR MESENTERIC

R. GASTRIC

L. GASTRIC

CYSTIC

### PORTAL:

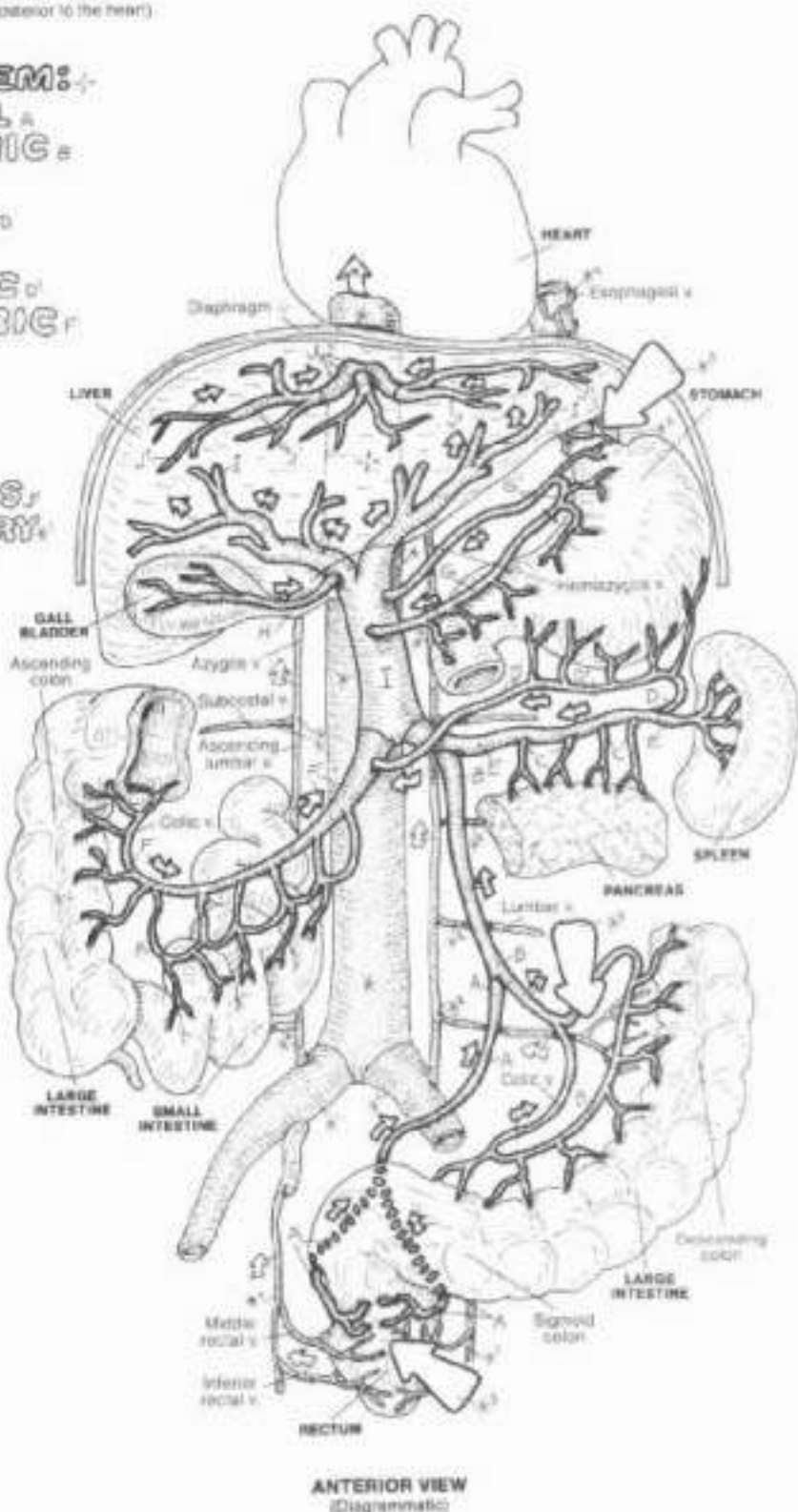
HEPATIC V. & TRIBUTARIES  
INF. VENA CAVA / TRIBUTARY  
SUP. VENA CAVA / TRIB.

### ANASTOMOSES SITE

Organs of the gastrointestinal tract, the gall bladder, pancreas, and spleen are drained by tributaries of the hepatic portal vein. Within the liver, branches of this vein (like those of an artery) discharge blood into capillaries (sinusoids) surrounded by liver cells. These cells remove digested (molecular) lipids, carbohydrates, amino acids, vitamins, iron, etc. from the sinusoids and store them, alter their structure, and/or distribute them to the body tissues (and in the case of unnecessary molecules or degraded remains of toxic substances, the kidneys). The distribution process begins with the selective release of molecular substances from the liver cells into the small tributaries of the three hepatic veins. The hepatic veins join the inferior vena cava (IVC) immediately below the diaphragm.

The portal system of veins is so-called because it transports nutrients and other molecules from the first capillary network in the intestines directly to the second capillary network (sinusoids) of the liver (without going through the heart first). Consequently blood in the portal system passes through two capillary networks instead of one.

In certain diseases of the liver, the formation of scar tissue blocks flow through the sinusoids. As a result, blood begins to back up in the portal system. In the chronic condition, the veins enlarge significantly. The blood, seeking the path of least resistance, finds collateral routes to the heart, enlarging them (varices). These routes (noted by arrows here) occur by way of anastomoses between veins of the portal system and veins of the inferior caval, superior caval, azygos, and vertebral venous systems. Other anastomoses exist via a number of retroperitoneal veins and the umbilical vein (not shown). In the latter vessel, irregular varicose veins can appear on the surface of the abdominal wall (capit Medusae; see glossary).



ANTERIOR VIEW  
(Diagrammatic)



# VI. CARDIOVASCULAR SYSTEM

## REVIEW OF PRINCIPAL VEINS

CV. Use blue for the superior and inferior vena cavae (K and K'). (1) Using preceding plates of the venous system for reference, color each vein and write its name in the appropriate lettered/numbered space with the same color, or write it in pencil (not pen—you may change your mind) and circle the letter/number with the color used for the vessel. (2) Note that the figure is in the anatomical position, palms facing for-

ward. (3) The superficial veins of the limbs are displayed on the figure's right side, the deep veins on the left side. On the right, the broken lines represent superficial veins on the posterior side. In both upper and lower limbs, the palmar/plantar veins are drained by deep veins. (4) Note in the thorax, the systemic veins are shown only on the figure's right side. The internal thoracic and anterior intercostal veins are not shown.

See glossary in the back of the book for answers.

A \_\_\_\_\_

B \_\_\_\_\_ B'

C \_\_\_\_\_

D \_\_\_\_\_

E \_\_\_\_\_

F \_\_\_\_\_

G \_\_\_\_\_

H \_\_\_\_\_

I \_\_\_\_\_

J \_\_\_\_\_

K \_\_\_\_\_

L \_\_\_\_\_

M \_\_\_\_\_

N \_\_\_\_\_

O \_\_\_\_\_

P \_\_\_\_\_

Q \_\_\_\_\_

R \_\_\_\_\_

S \_\_\_\_\_

T \_\_\_\_\_

U \_\_\_\_\_

V \_\_\_\_\_

W \_\_\_\_\_

X \_\_\_\_\_

Y \_\_\_\_\_

Z \_\_\_\_\_ Z'

1 \_\_\_\_\_

2 \_\_\_\_\_

3 \_\_\_\_\_

4 \_\_\_\_\_

5 \_\_\_\_\_

6 \_\_\_\_\_

7 \_\_\_\_\_

8 \_\_\_\_\_

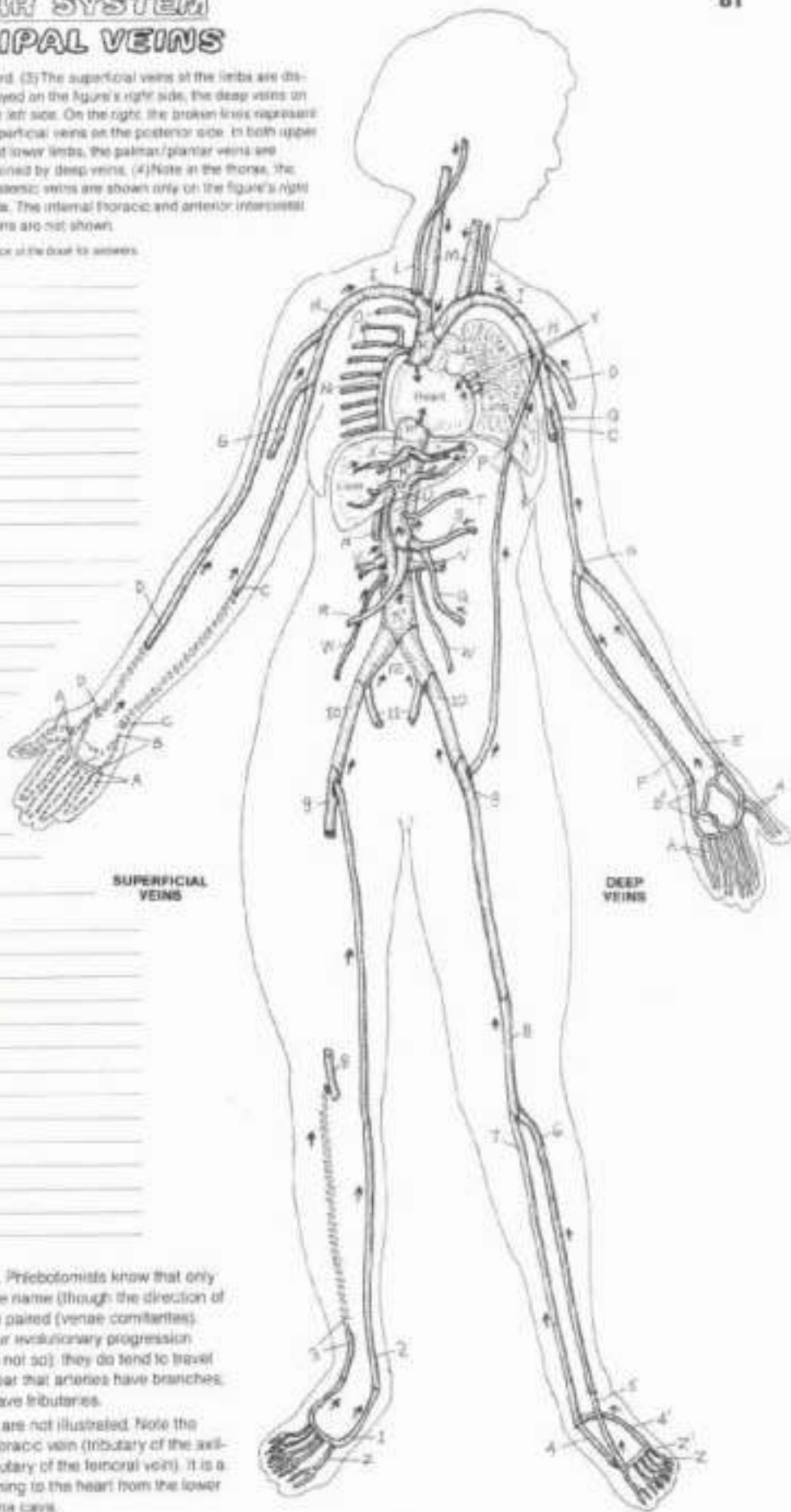
9 \_\_\_\_\_

10 \_\_\_\_\_

11 \_\_\_\_\_

12 \_\_\_\_\_

K' \_\_\_\_\_



Veins are extremely variable in size and location. Priebotomists know that only too well: Deep veins run with arteries of the same name (though the direction of flow is opposite); in the limbs, the veins are often paired (venae comitantes). Superficial veins have no companion arteries (our evolutionary progression would have been severely shortened if this were not so); they do tend to travel with cutaneous nerves. In review, it should be clear that arteries have branches; portal veins have branches, but all other veins have tributaries.

Note the internal thoracic vein and its tributaries are not illustrated. Note the thoracoepigastric vein (P) between the lateral thoracic vein (tributary of the axillary vein) and the superficial epigastric vein (tributary of the femoral vein). It is a significant route of collateral flow for blood returning to the heart from the lower limb in the presence of an obstructed inferior vena cava.

# VI. CARDIOVASCULAR SYSTEM

## PETAL CIRCULATION

### PLACENTA:

OXYGENATED BLOOD → B  
 UMBILICAL VEIN → B'

### DUCTUS VENOSUS:

DEOXYGENATED BLOOD → C  
 DEOXY. & OXY. BLOOD → C'

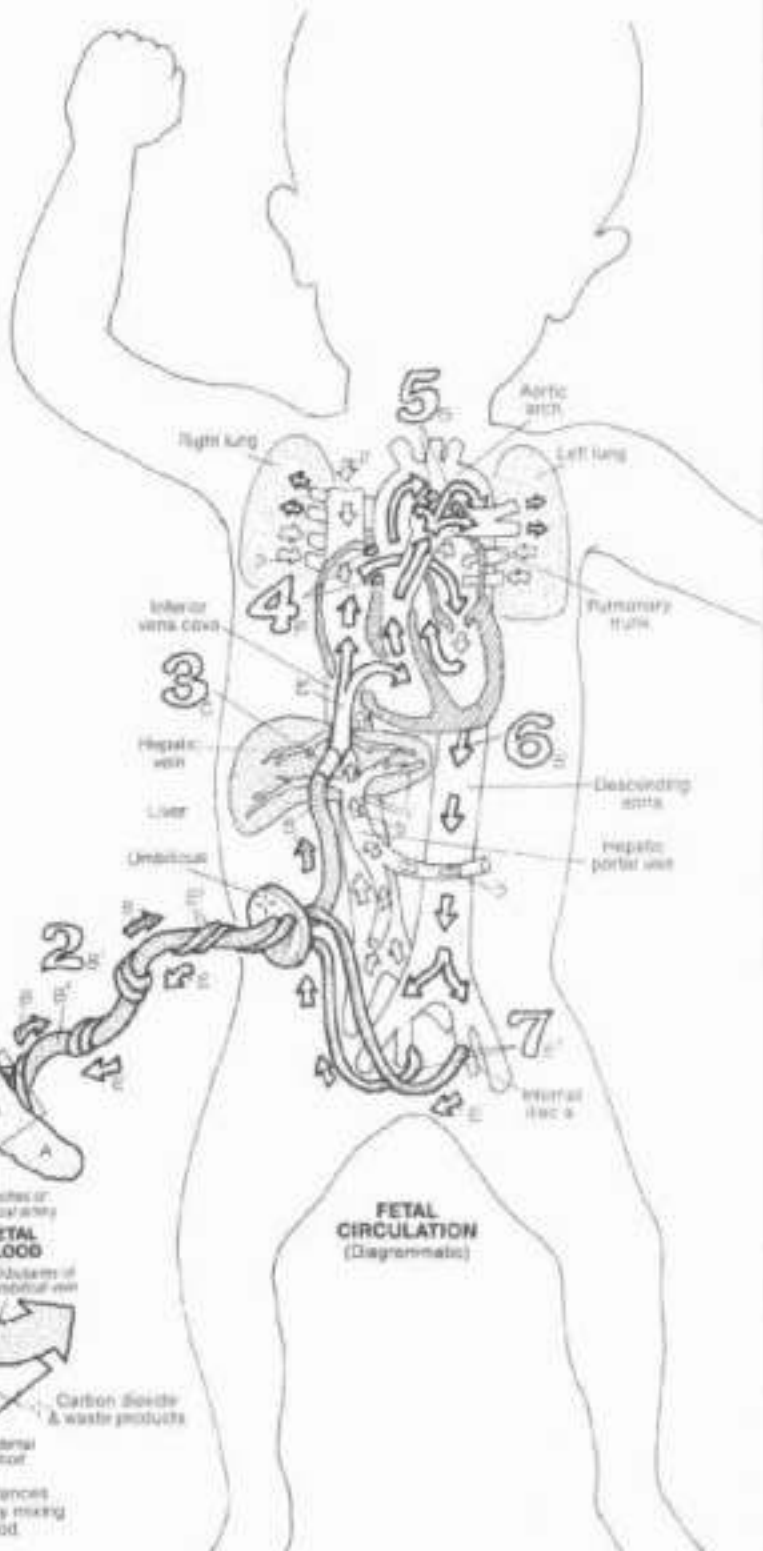
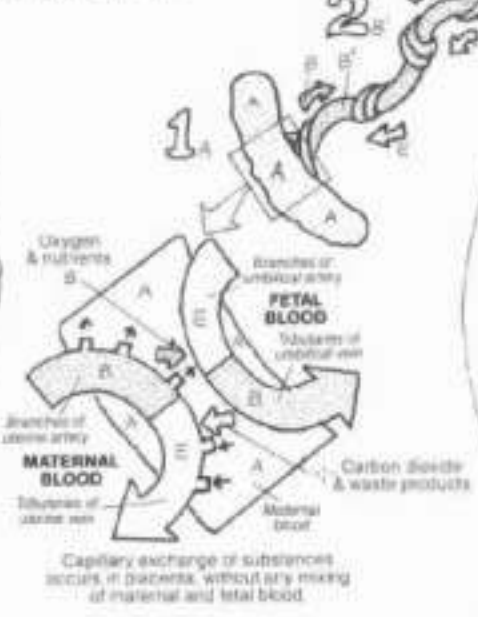
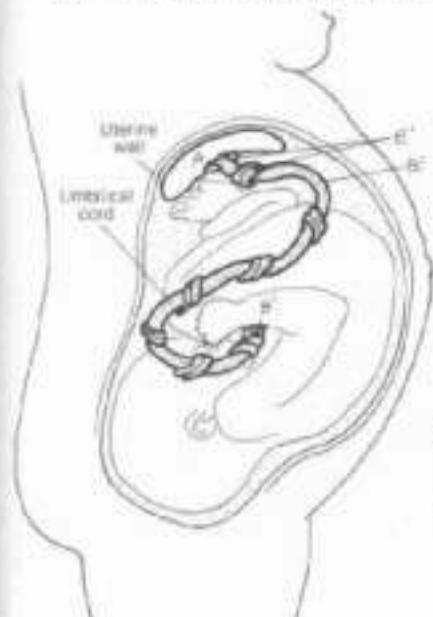
### FORAMEN OVALE:

### DUCTUS ARTERIOSUS:

### UMBILICAL ARTERY → E'

The fetus in the uterus does not breathe air; its lungs are deflated. This plate reveals how the fetus gets oxygenated blood to its system (in the absence of breathing air) and gets deoxygenated blood out of the body. The placenta (in utero 1) is an organ in the uterus of a pregnant woman that provides gaseous and nutritional support for the fetus. The placenta communicates with the fetus by an umbilical cord (2). The vessel taking oxygenated blood from the placenta to the fetus is the umbilical vein (2) which runs to the underside of the liver (3) to join the portal vein. Here the oxygen-rich blood of the former is mixed with the deoxygenated blood of the latter. A vein existing only in the fetus (ductus venosus) diverts the blood directly to the hepatic vein bypassing the liver sinusoids. The mixed blood then enters the inferior vena cava to the right heart. The blood is directed to the left (systemic) side of the heart by two means: an opening in the interatrial wall (foramen ovale; 4) and a short vessel between the pulmonary trunk and the descending part of the aortic arch (ductus arteriosus; 5). Only a fraction of mixed blood gets pumped to the non-functioning (but living) lungs. The mixed blood leaves the heart via the aorta (6) to reach the body tissues. The oxygen-carrying capacity of fetal hemoglobin is particularly great in comparison with that of the adult; the fetal tissues get sufficient oxygenation from mixed blood to permit remarkably rapid growth. Paired umbilical arteries, arising from the internal iliacs, return the deoxygenated blood from the fetus to the umbilical cord and placenta. After birth, due to altered hemodynamic patterns associated with breathing, the circulation in the fetal umbilical vessels and ducts of the newborn diminish significantly and the vessels soon thrombose. The umbilical vein atrophies to become the ligamentum teres in the falciiform ligament (Pl. 105); the umbilical arteries become the medial umbilical ligaments (Pl. 75); the ductus venosus becomes the ligamentum venosum; revised circulation to the lungs induces closure of the foramen ovale; flow through the ductus arteriosus trickles down, the vessel closes, and becomes a ligamentous strand (ligamentum arteriosum; Pl. 66).

CA: Use red for B (oxygenated blood, represented by a solid arrow) and B' (umbilical vein). Use blue for C (deoxygenated blood, represented by a light lined arrow). Use purple for C' (mixed deoxygenated and oxygenated blood, represented by a dash-lined arrow) and E' (umbilical artery). Use bright colors for C, F, and G. (1) Color the placenta and the large number 1, as well as the enlarged rectangular portion of the placenta magnified to show capillary exchange between fetal and maternal vessels. (2) Color the large numbers while coloring related structures and blood flow arrows. (3) Color the placenta and components of the umbilical cord in the uterus at lower left.



Capillary exchange of substances occurs in placenta, without any mixing of maternal and fetal blood.

## VII. LYMPHATIC SYSTEM

### LYMPHATIC DRAINAGE & LYMPHOCYTE CIRCULATION

DN: Use blue for H, red for L, purple for L, and green for M. (1) Color over the light lines representing peripheral (superficial) lymph vessels (A). (2) Color each large step number in the diagram below with the related titles. In the bottom diagram, do not color the lymphocytes circulating in and between the blood and lymph capillaries.

**SUPERFICIAL DRAINAGE:**  
**PERIPHERAL LYMPH VESSELS,**  
**CERVICAL, AXILLARY, & INGUINAL NODES,**

**DEEP DRAINAGE:**  
**LYMPHATIC TRUNK,**  
**CYSTERNA CHYLI,**  
**THORACIC DUCT,**  
**RIGHT LYMPH DUCT.**

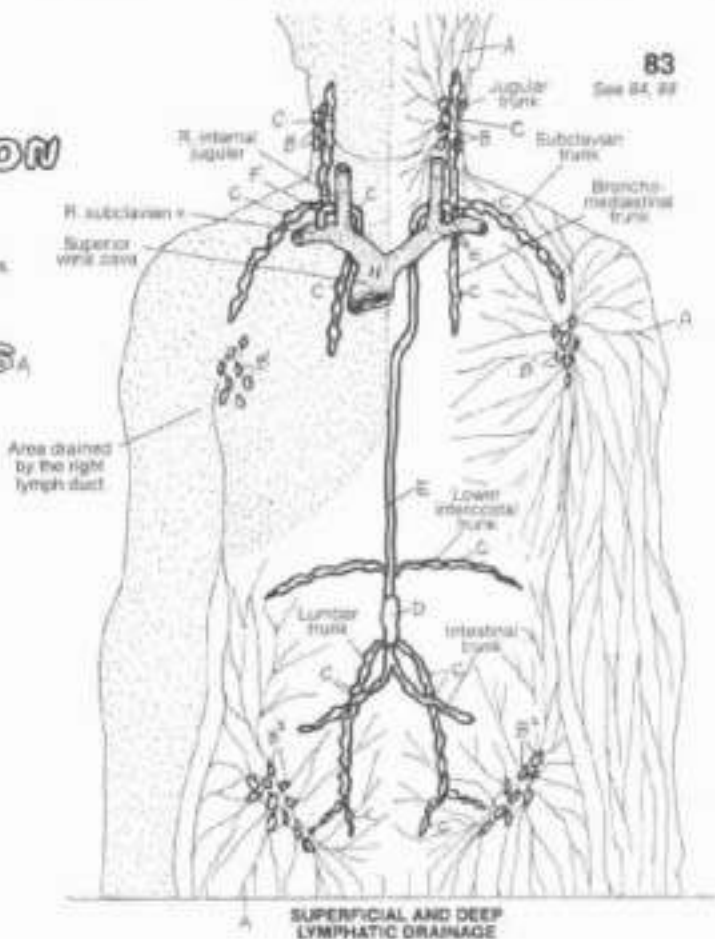
The body is about 60% fluid (by volume), filling cells, vessels, and spaces. Fluid requires circulation. Some of the fluid of the blood, as well as some lymphocytes, leave the circulatory system and enter the tissue spaces. Some of this fluid, lipids, and lymphocytes (lymph) are recovered by thin-walled vessels (lymphatic capillaries) that form in the loose connective tissue spaces. Unlike the closed-loop blood capillary networks, these tiny vessels are closed at one end. They merge to form progressively larger lymphatic vessels that drain into large veins in the neck. These vessels constitute the lymphatic system. Certain lymphatic vessels enter and leave lymph-filtering stations called lymph nodes.

Region-draining lymph trunks converge into a dilated lymph sac (cysterna chyli) lying deep to the abdominal aorta on the first lumbar vertebra. The thoracic duct begins at the upper end of the sac, ascends the anterior surface of the vertebral column, and drains into the left subclavian vein at its junction with the internal jugular vein. The right lymph duct terminates similarly on the opposite side. It drains the dotted area.

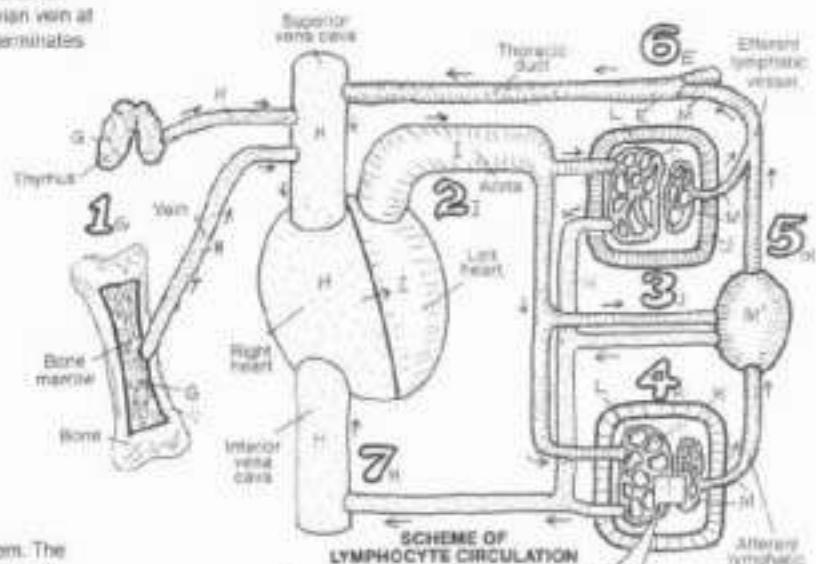
**LYMPHOCYTE CIRCULATION:**  
**GENERATIVE ORGAN:**  
**VENOUS BLOOD**  
**ARTERIAL BLOOD:**  
**LYMPHOID TISSUE,**  
**PERIPHERAL TISSUE,**  
**CAPILLARY NETWORK,**  
**LYMPH VESSELS,**  
**LYMPH NODE**

Lymphocytes are one of the principal cells of the immune system. The circulation scheme reveals the primary pathway for the dissemination of lymphocytes from their generative organs (bone marrow, thymus) into the lymphoid tissues and organs as well as organs and tissues in general (peripheral tissues). Such a circulation pattern provides for maximum exposure of lymphocytes to microorganisms and subsequent body defense operations (immune responses).

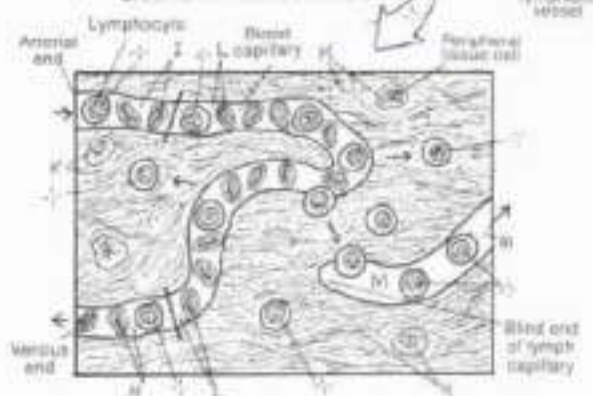Formed and developed in the bone marrow and thymus (1), lymphocytes leave with the venous blood to enter the circulation. By way of arterial blood (2), lymphocytes enter the capillary networks of the lymphoid tissues (3) and other peripheral tissues (4). The lymphocytes may remain in or migrate from the lymphoid organs/peripheral tissues, entering blood capillaries or lymph vessels. From lymph capillaries, the lymphocytes flow with the lymph fluid into regional lymph nodes (5). Here they may become resident or they may depart the node and merge with other lymph vessels to join the lymph ducts (6) that connect with the blood circulatory system.



SUPERFICIAL AND DEEP LYMPHATIC DRAINAGE



SCHEME OF LYMPHOCYTE CIRCULATION





# VIII. IMMUNE (LYMPHOID) SYSTEM INTRODUCTION

CM: Use green for D, the same colors for bone marrow (A) and thymus (B) used in Plate 83, and very light colors for H-L. (1) The structures depicting mucosal associated lymphoid tissue (E) are generalizations; more accurate representations can be seen on Plate 89. (2) The three lymphocyte types have identifying letters drawn into their nuclei. Color over the entire cell in all cases.

## PRIMARY ORGANS: BONE MARROW, THYMUS:

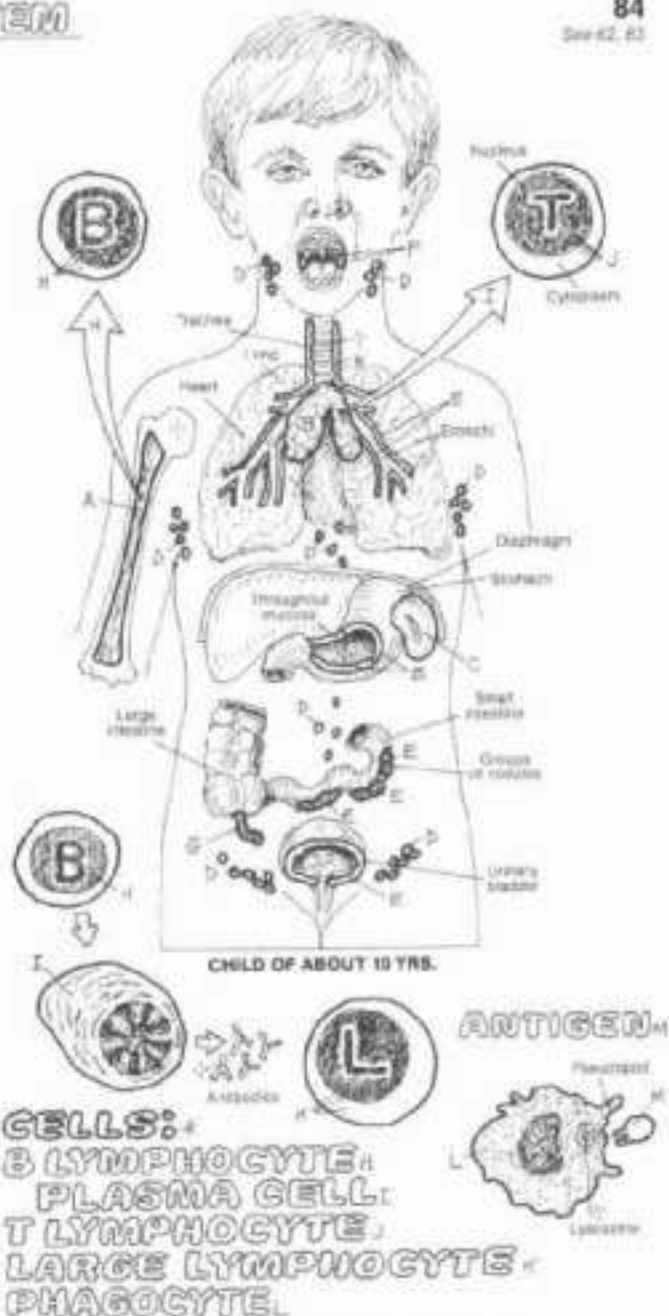
The lymphoid system is the anatomical component of the immune system, and functions in defense against microorganisms entering the body as well as the destruction of cells or cell parts no longer recognizable as "self." Lymphoid tissues and organs are predominantly collections of lymphocytes and related cells (see below) often supported by a meshwork of reticular fibers and cells.

The red bone marrow and thymus are primary lymphoid organs. The bone marrow contains the precursors of all lymphocytes and discharges lymphocytes into the circulation. It consists largely of great varieties of blood cells in various stages of maturation, phagocytes, reticular cells and fibers, and fat cells. Some of the lymphocytes mature and undergo structural and biochemical revision (differentiation) in the bone marrow to become B lymphocytes. Some undifferentiated lymphocytes migrate via the blood to the thymus to become T lymphocytes before re-entering the circulation. Others become large lymphocytes, enter the circulation, and migrate to secondary lymphoid organs.

The thymus is located in the superior and anterior (inferior) mediastinum. It receives uncommitted lymphocytes from the bone marrow. The thymus is actively engaged in T lymphocyte proliferation and differentiation during embryonic and fetal life as well as the first decade of extrasternal life. The thymus begins to undergo degeneration (involution) after puberty.

## SECONDARY ORGANS: SPLEEN, LYMPH NODE, MUCOSAL ASSOCIATED LYMPHOID TISSUE (M.A.L.T.): TONSILS/ADENOIDS, APPENDIX:

Secondary lymphoid organs are structures predominantly populated by lymphocytes that migrated from the primary lymphoid organs. The structural arrangement of these organs ranges from encapsulated, complex structures, like the spleen and lymph nodes, to a diffuse disposition of lymphocytes throughout the loose connective tissues (mucosal associated lymphoid tissue). These secondary organs represent satellite sites for lymphocyte activation when challenged by antigens. The spleen processes incoming blood. Its lymphocytes and phagocytes react rapidly to the presence of microorganisms and aged red blood corpuscles. Lymph nodes screen lymph from incoming (afferent) lymphatic vessels, much in the same manner as the spleen processes blood. Diffuse and nodular masses of lymphoid tissue in the mucosal lining of open cavities constitute mucosal associated lymphoid tissue (M.A.L.T.). Such tissue includes tonsils and adenoids situated close to the epithelial layer at portals of entry to certain open (nasal, oral, and pharyngeal) cavities. They are active in "marking" incoming microorganisms for subsequent destruction. Unencapsulated masses of lymphocytes and related cells occur in varying concentrations throughout the mucosa, forming distinct masses (diffuse lymphoid tissue). The vermiform appendix incorporates multiple lymphoid follicles in its mucosa. The density of these cell collections varies with the degree of immune responsiveness required.



## CELLS: B LYMPHOCYTE, PLASMA CELL, T LYMPHOCYTE, LARGE LYMPHOCYTE, PHAGOCYTE.

Activated B lymphocytes (B, bone marrow-derived) differentiate along specific lines, one of which is the transformation into plasma cells. Both cells secrete protein molecules, called antibodies, into the tissue fluids. Antibodies interact with and enhance the destruction of elements that induced their activation and synthesis. Such elements are called antigens. The term antigen is restricted to those elements (molecules, cells, microorganisms) that induce activation of lymphocytes (immune response). T lymphocytes (T, thymus-derived) differentiate, upon stimulation by antigen, into one of a number of different activated cells, one of which stimulates and regulates specific and non-specific body defense operations (helper function,  $T_H$  cells).

Large, granular lymphocytes (natural killer or NK cells) destroy tumor cells or cells infected with virus. They can be activated by T lymphocytes to lyse target cells, as in graft rejection. Mononuclear phagocytes are cells that destroy by phagocytosis antigen as well as parasites that do not induce an immune response. They present antigen to lymphocytes (antigen-presenting cells) for identification and destruction.

# VIII. IMMUNE (LYMPHOID) SYSTEM

## NATURAL & ACQUIRED IMMUNITY

Use pink for E and the same colors used on Page 84 for cells D, F, G, and H. Radial lines surrounding a cell indicate activation. All elements shown have been magnified and schematized for coloring. (1) Begin with the site microorganism in the upper right corner.

### NATURAL IMMUNITY:

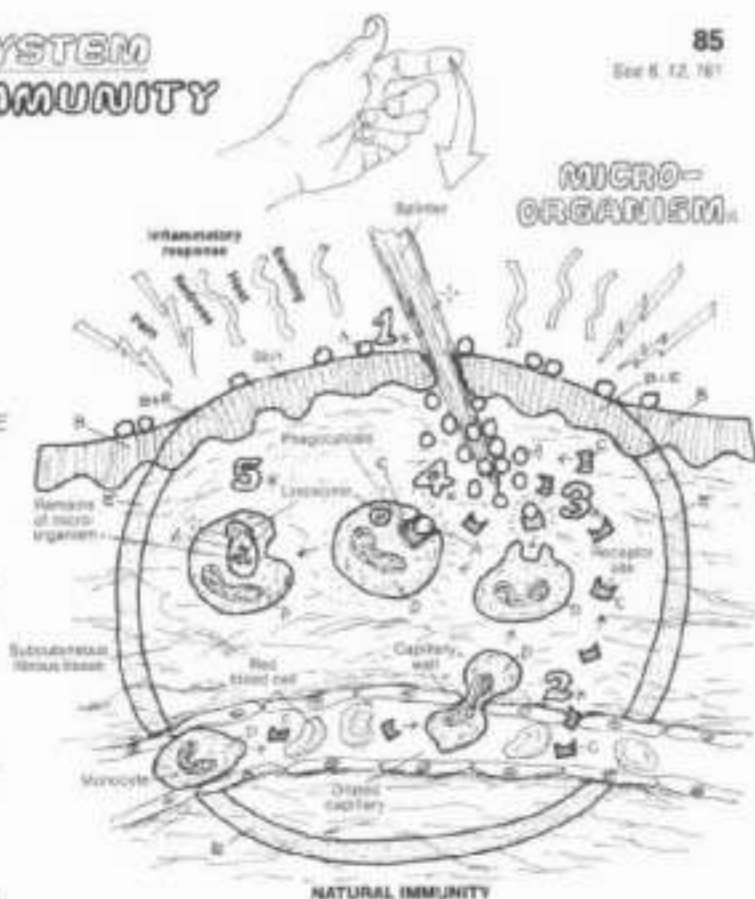
#### ANATOMIC BARRIER.

#### COMPLEMENT.

#### PHAGOCYTE.

#### INFLAMMATORY RESPONSE.

Immunity is an anatomic and physiologic state of security against disease. Natural immunity exists independent of any specific micro-organismal interaction with a lymphocyte. Shortly before birth and following, one progressively acquires a specific immunity following each lymphocyte's encounter with antigen and resulting activation. Phagocytes participate in both natural and acquired immunity, lymphocytes participate in acquired immunity and enhance natural immunity. Natural immunity operates indiscriminately against microorganisms and degenerated cells/cell parts. Anatomic barriers (1), such as skin or mucous membranes, physically resist microorganismal invasion. Phagocytes approach their prey from the blood (2) or connective tissues (3), engulf them (4, phagocytosis) and destroy them with lysosomal enzymes (5). Complement is the name given to several soluble proteins found in the body fluids which when activated attach to microorganisms, enhancing their phagocytosis. Tissue irritation, e.g., disruption by a splinter, induces an inflammatory response which involves both natural and acquired immunity.



### ACQUIRED IMMUNITY:

Acquired immunity involves diverse but specific lymphocyte responses to the presence of antigen. A specific lymphocytic reaction to antigens (immune response) is characterized by the activation and proliferation of lymphocytes followed by the destruction of antigens. Two kinds of acquired immunity are possible based on lymphocyte types: humoral immunity and cellular immunity. Inherent in both kinds of immunity are: specificity and diversity of response, retention of cellular memory of antigen, and the ability to recognize self from non-self among the body's proteins.

### HUMORAL IMMUNITY:

#### B LYMPHOCYTE.

#### PLASMA CELL.

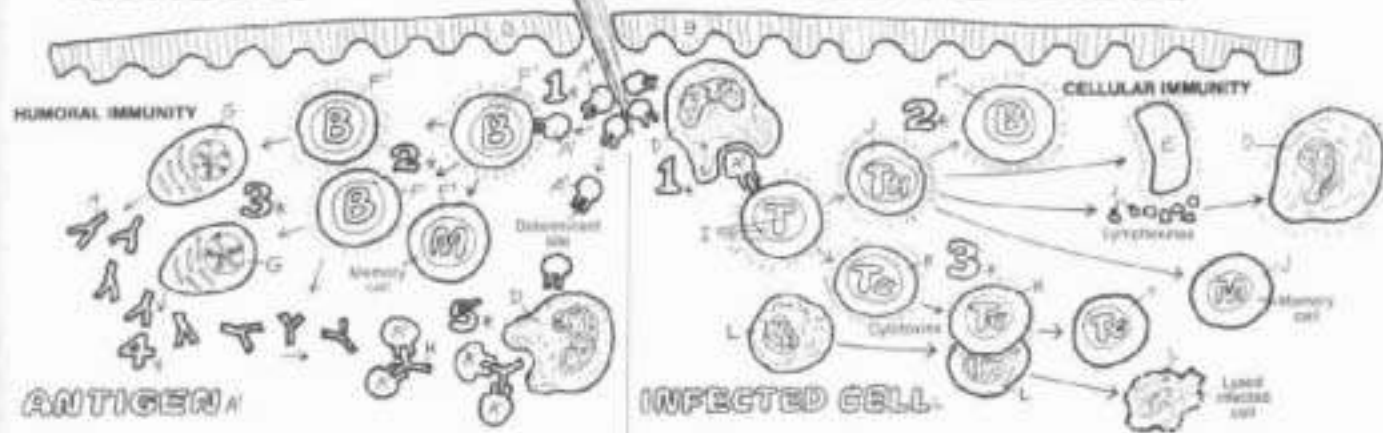
#### ANTIBODY.

### CELLULAR IMMUNITY:

#### T LYMPHOCYTE.

#### HELPER CELL (T<sub>H</sub>).

#### CYTOLYTIC CELL (T<sub>C</sub>).



Humoral (fluid-related) immunity is characterized by B lymphocytes being activated by antigen (1), proliferating, forming memory (M) cells, secreting antibody (2), and forming plasma cells (3) which secrete antibody (4). Antibodies are complex proteins formed in response to a specific antigen and attached to it at the antigenic determinant site (5), facilitating its phagocytosis.

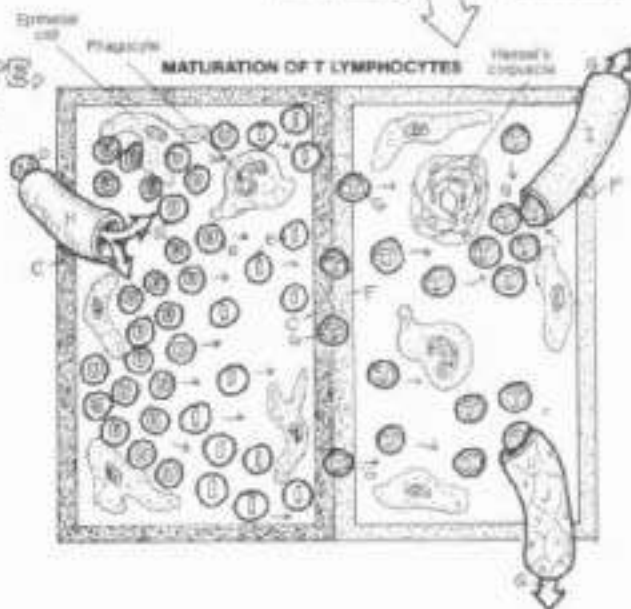
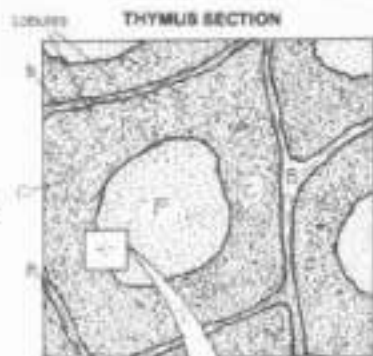
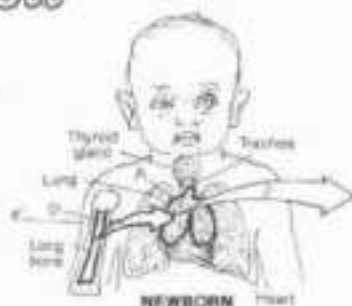Cellular immunity is characterized by T lymphocytes being activated by antigens attached to antigen presenting cells (phagocytes, 1). Activated

T cells differentiate into helper T lymphocytes (T<sub>H</sub>) and cytolytic T lymphocytes (T<sub>C</sub>, CTL). Helper T lymphocytes (2) enhance humoral immunity by activating B cells, augment the inflammatory response, activate phagocytes with stimulating factors (lymphokines), and form memory (M) cells. Cytolytic T lymphocytes (3) bind to and destroy infected cells, and form memory cells. Memory cells recognize specific structural characteristics of the antigens encountered ("memory") and facilitate rapid immune responses on subsequent exposure to those antigens.

# VIII. IMMUNE (LYMPHOID) SYSTEM

## THYMUS & RED MARROW

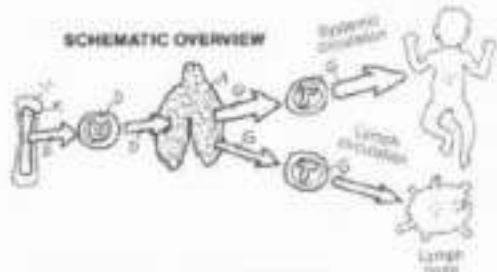
Ch: Use red for H, blue for I, green for J, and the same color as used in preceding plates for mature T lymphocytes (G). (1) Color the material on red marrow at the bottom of the plate. Then color the red marrow (K) portion of the newborn's arm bone. Color the thymus section and the diagrammatic description of lymphocyte maturation in the thymus. Note that the borders of the diagram represent the cortex and medulla of the thymus. Then color the schematic overview of thymic function. (2) Color the lowest drawing associated with red marrow.



**THYMUS:**  
**FIBROUS SEPTA:**  
**CORTEX:**  
 UNDIFFERENTIATED LYMPHOCYTE,  
 IMMATURE T LYMPHOCYTE,  
**MEDULLA:**  
 MATURE T LYMPHOCYTE,  
**ARTERIAL VESSEL:**  
**VENOUS VESSEL:**  
**LYMPH VESSEL.**

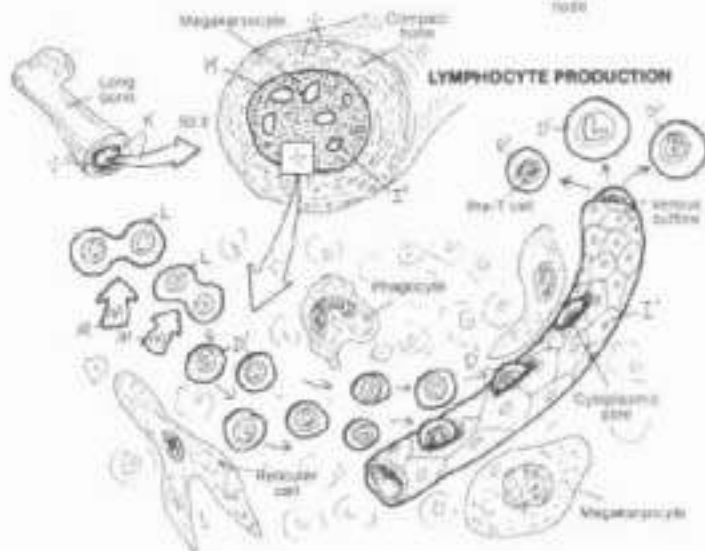
The thymus seeds the entire body with T lymphocytes, the protagonists of cellular immunity. It consists of two lobes of glandular tissue in the anterior and superior mediastinum. The thymus is functional and relatively large in the late fetus/newborn (15 gms), continues to grow and function during the pre-teen years, and declines in size and activity in the following years.

The functional thymus consists of microscopic lobules partitioned by fibrous septa containing blood vessels. Each lobule has an outer cortex dense with lymphocytes and a much less dense, central medulla. The epithelial cells of the lobule form a structurally supporting "reticular" network. Distinctive concentric rings of keratinized epithelial cells (Hassall's corpuscles) are seen in the medulla, although associated with degenerative signs in aging, they may support lymphocyte differentiation. Arterial vessels bring undifferentiated lymphocytes into the cortex. The cells migrate into the medulla, showing signs of differentiating into T cells. In the inner cortex, the cells are largely immature (but committed) T cells. The medulla contains largely mature T cells. These cells leave the thymus by venules (venous vessels) to enter the systemic circulation. Some T lymphocytes enter lymph vessels destined for mediastinal lymph nodes and beyond. The thymus also produces a number of factors (hormones) stimulating lymphocyte differentiation.



**RED MARROW:**  
 LYMPHOCYTE PRECURSOR,  
 GROWTH FACTOR,  
 LYMPHOCYTE,  
 SINUSOID.

Red marrow (recall Plate 17) is densely populated with a great variety of blood cells in various stages of development. The supporting framework of marrow is reticular fibers and cells. Fed by arteries from the nutrient artery of the bone, the capillaries within the marrow are enlarged to the extent of being small sinuses (sinusoids). They reveal transient cytoplasmic "pores" for the immediate passage of cells into the circulation. Among the developing blood cells are lymphocyte precursors. These are stimulated to divide by certain growth factors. The progeny of these cells are mostly small and some large lymphocytes. Presumably, B lymphocyte maturation occurs in the bone marrow, whereas T lymphocyte maturation occurs in the thymus. The lymphocytes (large, undifferentiated pre-T, and B) enter the sinusoids and the venous outflow to be distributed body-wide.





# VIII. IMMUNE (LYMPHOID) SYSTEM

## SPLEEN

CA: Use red for E, purple for F, blue for G, the same colors as previously used for H, I, K and L, the color used on Plate 85 for antigen (M), and very light colors for C and D. (1) When coloring the schematic representation of spleen structures, note the underlying brackets which designate the structures lying within the white pulp and red pulp regions.

### SPLEEN

CAPSULE:

TRABECULA:

WHITE PULP:

LYMPHOID FOLLICLE:

RED PULP:

### BLOOD VESSELS:

ARTERY:

ARTERIOLE:

VENOUS SINUSOID:

VENULE:

VEIN:

### CELLS:

T LYMPHOCYTE:

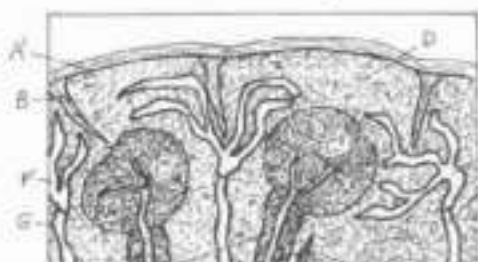
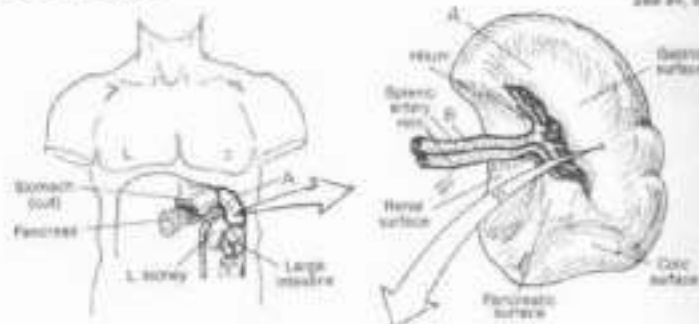
B LYMPHOCYTE:

MITOTIC

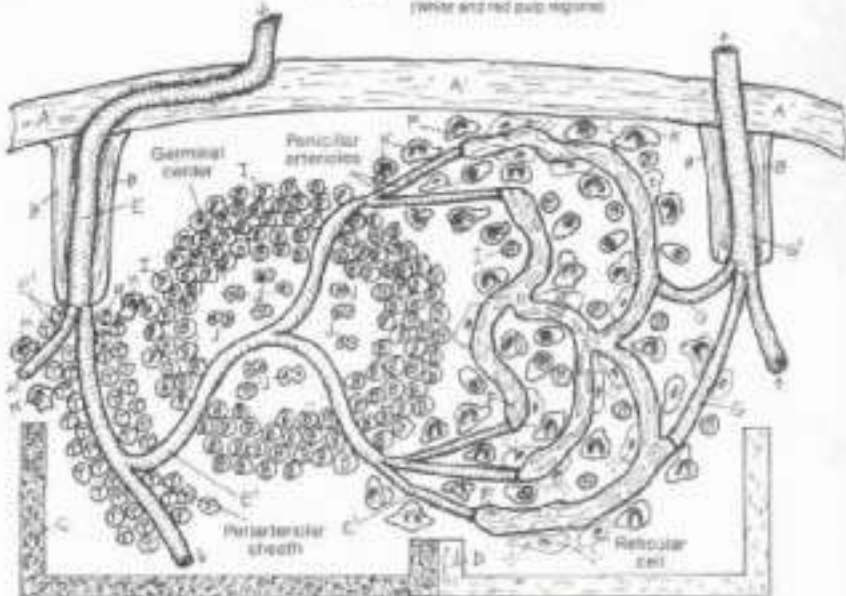
LYMPHOCYTE:

PHAGOCYTE:

PLASMA CELL:



SECTIONAL VIEW  
(white and red pulp regions)



SPLEEN STRUCTURES  
(Schematic)

The soft, blood-filled, dark purple spleen lies posteriorly in the upper left abdominal quadrant, just above the left kidney, at about the level of the 11th and 12th ribs. It is generally about the size of your closed fist. The capsule of the spleen projects inward extensions (trabeculae) that support the organ and incoming/outgoing vessels. The microscopic view of the spleen is complicated by the endless sea of lymphocytes and phagocytes, and in this organ, red blood cells.

Small, downstream branches of the splenic artery travel in the fibrous trabeculae; branching arterioles become enveloped in lymphocytes (periaarterial sheath) and branch among lymphoid follicles. These follicles, the arterioles, and their cellular sheaths constitute the white pulp. These follicles enlarge with antigenic stimulation; large mitotic lymphocytes (in various stages of cell division) begin to appear in the central part of each follicle (germinal center) following stimulation, creating a zone less dense than the surrounding, cell-packed area. As the straight (penicillar) arterioles leave the white pulp, they become lined with phagocytes and dilate to form venous sinusoids (closed theory, illustrated). An alternate "open theory" holds that the vessels open into large spaces drained by the sinusoids. Cells (reticular cells, plasma cells, phagocytes, and some B lymphocytes) form long, irregu-

lar cellular strands (splenic cords) amidst interconnected sinusoids; these are collectively called red pulp. The sinusoids drain into venules, forming tributaries of trabecular veins; these form the tributaries of the splenic vein.

As blood flows into the arterioles, antigens and old red blood cells are greeted by mononuclear phagocytes and myriad T lymphocytes, setting off cellular immune responses in the periaarterial sheaths. Snaking into the follicles of the white pulp, the vessels are surrounded by B lymphocytes; antibodies are formed and attach to antigens which are isolated from the circulation and phagocytosed (humoral immunity). The lumens of vessels in the red pulp are "strained" by the lining phagocytes; old red blood cells are sequestered and phagocytosed, and antigens are met by antibodies, and they are phagocytosed. Clearly, antibody production and phagocytosis are major activities of the spleen. Although antibody and complement enhance phagocytosis of red blood cells here, the splenic phagocytes are not dependent on T cells and antibody to function. Systemic infection markedly increases the output of lymphocytes, causing palpable splenic enlargement (splenomegaly). Removal of the spleen (splenectomy) is not a benign event, as the body absent a spleen may have reduced immune capabilities.

## LYMPH NODE

### LYMPH NODE A:

**CAPSULE A:**

**TRABECULA:**

**RETICULAR NETWORK:**

**CORTEX:**

**LYMPH FOLLICLE:**

**GERMINAL CENTER F:**

**MEDULLA:**

**PARACORTX:**

### LYMPH VESSELS:

**AFFERENT LYMPH VESSEL:**

**LYMPH SINUS:**

**EFFERENT LYMPH VESSEL:**

### BLOOD VESSELS:

**ARTERY:**

**VEIN V/ VENULE V'**

### LYMPHOID CELLS:

**PHAGOCYTE N:**

**T LYMPHOCYTE O:**

**B LYMPHOCYTE P:**

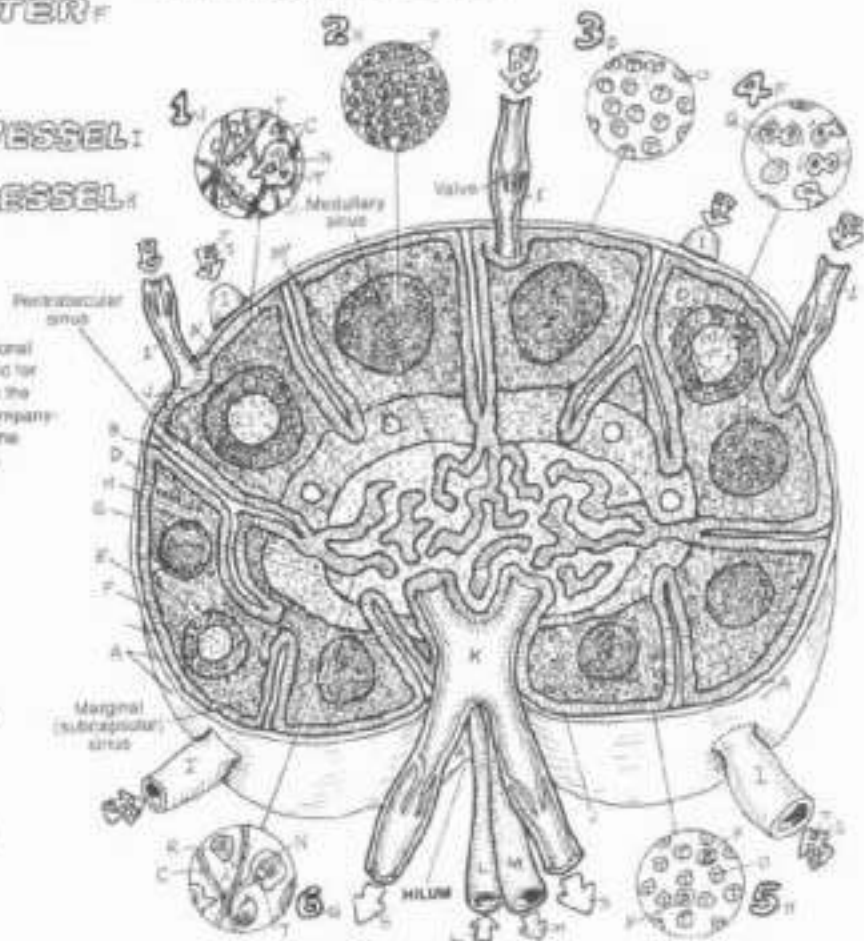
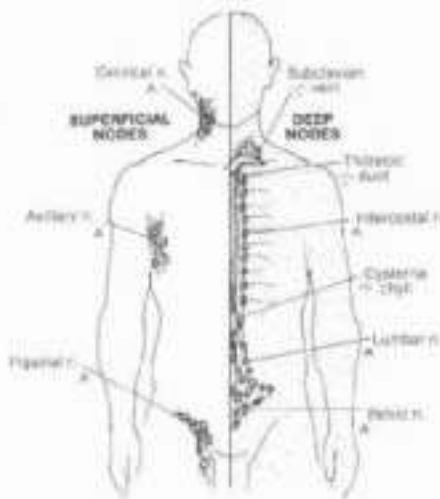
**MITOTIC LYMPHOCYTE Q:**

**PLASMA CELL R:**

**LYMPH:**

**ANTIGEN T:**

CN. Use red for L, blue for M, green for S (if you have additional greens, use them on I-K), the same colors as previously used for I-R, and light colors for D-H. (1) As you color the regions of the lymph node, use the same color on the large numerals accompanying the insets identifying the dominant cell in that region. In the paracortex, note the small circles representing venules (M').



SECTIONAL VIEW

The lymph node has a fibrous capsule from which trabeculae invade the organ, dividing it incompletely into compartments. Fine reticular fibers and cells spread out from the trabeculae to form a thicket of interwoven branches throughout the node (reticular network). This intricate weave of fibers supports the dense populations of lymphocytes throughout the node. Lymph percolates through parts of the reticular network called lymph sinuses (only the marginal sinuses appear to be endothelial-lined). The reticular fibers in these sinuses (1) form a spatial framework from which phagocytes can readily engage antigens in the lymph flow.

The node interior is characterized by an outer cortex and an inner medulla. The cortex reveals a group of particularly dense masses of B lymphocytes (2, lymphoid follicles) existing among a more sparse array of largely T lymphocytes in the interfollicular areas (3). In the presence of significant amounts of antigen, the follicles develop germinal centers; here are seen mitotic lymphocytes in varying degrees of mitosis (4). The outer part of the medulla (paracortex) has more diffuse arrangements of phagocytes, T cells, and some B cells (5). The endothelial cells of the venules in the paracortex are specialized and provide lymphocyte homing receptors that influence the localization of T and B cells within the node. The medulla contains a concentrated

array of interconnecting sinuses, with phagocytes and plasma cells in significant numbers (6).

Lymph enters the nodes by afferent vessels with valves controlling unidirectional traffic. As the lymph meanders through the throngs of reticular fibers in the sinuses, phagocytes pick off the antigens and present them to the T cells in the interfollicular areas. Activated B cells in the follicles, facilitated by helper (T<sub>H</sub>) cells, transform into plasma cells and memory cells. The plasma cells and B cells secrete antibody with receptors which bind a portion of the antigen (antigenic determinant). Binding of antibody to the antigen facilitates destruction of the antigen. Major stimulus promotes formation of the germinal centers. Further immune activity occurs in the paracortical and inner medullary areas. Lymph leaves the medullary sinuses and the node by way of the efferent vessels. Lymphocytes also enter the node by small arteries; these cells can migrate into the sinuses from the venules while the remaining blood leaves the node by veins.

In summary, the lymph node is the site of both humoral-mediated (B cell) and cell-mediated (T cell) immune responses to antigens in the lymph. Palpable enlargement of cervical lymph nodes during an upper respiratory infection, for example, gives testimony to the existence of such mechanisms operative in the face of microorganismal invasion.

# VIII. IMMUNE (LYMPHOID) SYSTEM

## MUCOSAL ASSOCIATED LYMPHOID TISSUE (M.A.L.T.)

CH: Use green for C, the same colors as previously used for E-J, and use light colors for A and B. (1) Begin with the representations of normal and inflamed tonsils, using pink and red colors, respectively. Include the capsular masts, identifying the dominant cells within the follicle and germinal center. Color the antigens (F) activating the follicle at center right, and related follicle parts, including masts. (2) Color the lower illustrations.

- PRIMARY FOLLICLE.
- GERMINAL CENTER.
- EFFERENT LYMPH VESSEL.
- LYMPHOID CELLS:
- MITOTIC LYMPHOCYTE.
- PHAGOCYTE.
- B LYMPHOCYTE.
- T LYMPHOCYTE.
- PLASMA CELL.

Uncapsulated lymphoid tissue, consisting of lymphocytes, plasma cells, and phagocytes (often termed "inflammatory cells"), not bound by fibrous capsules and ranging throughout the loose connective tissues of the mucosae in variable densities, is called mucosal associated lymphoid tissue (M.A.L.T.) or diffuse lymphoid tissue. The cells of this tissue are a mobile lot, and can increase in numbers rapidly in response to the presence of microorganisms. Often, in the setting of chronic antigen exposure, well organized follicles (also called nodules), similar to those seen in lymph nodes and the spleen, may form. Some examples of M.A.L.T. are shown here.

### TONSIL / INFLAMED TONSIL

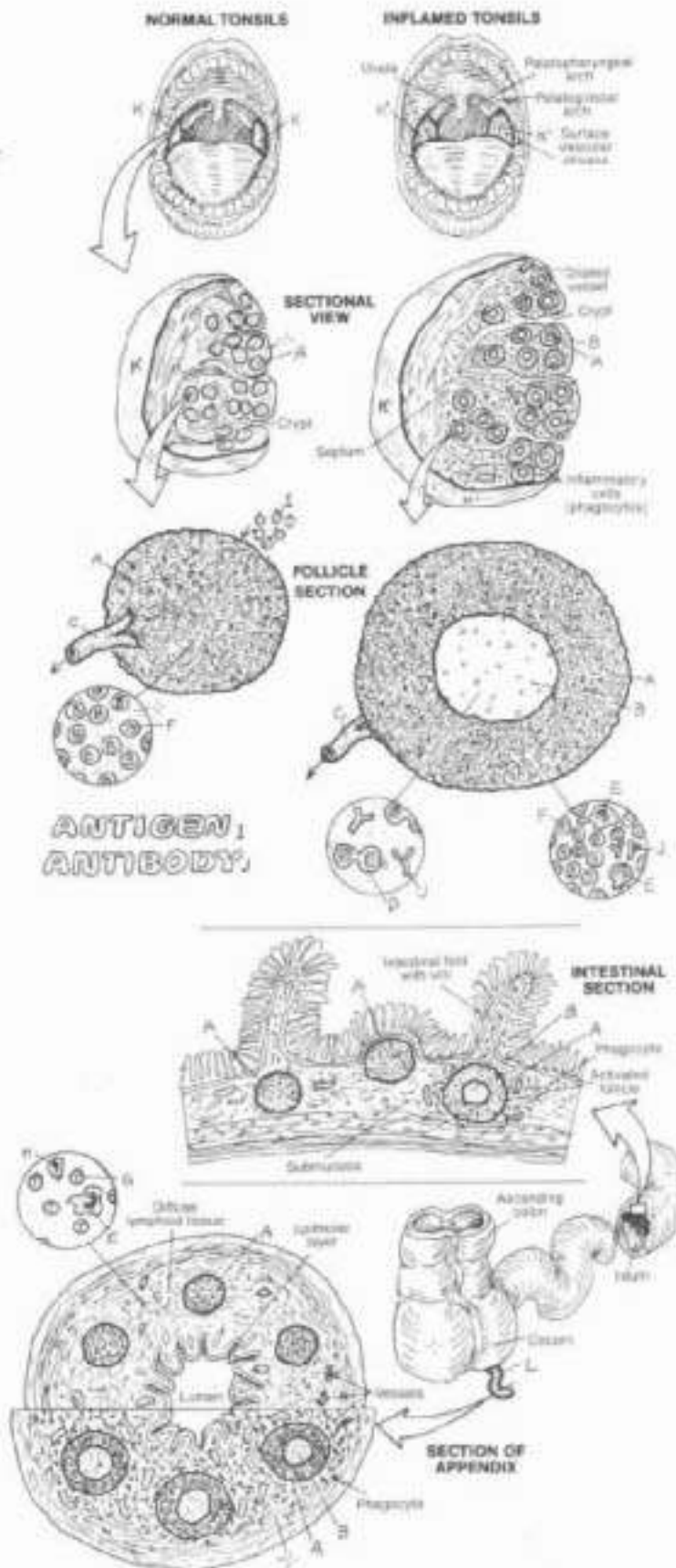
Masses of primary lymphoid follicles surrounding infoldings of the pharyngeal mucosa are called tonsils. Tonsils have no definitive lymph sinuses; however, lymph capillaries can be seen draining into efferent lymphatic vessels. With antigenic stimulation, inflammation of the tonsil occurs (tonsillitis). A common event, an inflamed tonsil is swollen, red (often with streaks of vessels ranging across the mucosal surface), and painful. As the follicles are activated, germinal centers are formed, numbers of B and T lymphocytes increase, phagocytes and plasma cells appear, and antibody is produced. Considered a culturally accepted "rite of passage" in the past, tonsillectomies are accomplished now only for good cause (obstructed airways, chronic infections). These organs respond quickly to the presence of microorganisms.

### PEYER'S PATCHES.

Aggregates of lymphoid follicles in the submucosa of the distal ileum are called Peyer's patches. Seen sporadically throughout the intestine, lymphoid follicles are more concentrated here. With antigenic stimulation, these follicles increase in much the same manner as tonsils.

### VERMIFORM APPENDIX.

The vermiform appendix is a thin, tubular extension of the cecum (large intestine). It contains a number of lymphoid follicles which extend from the submucosa up to the epithelial lining of the mucosa. The mucosa of the appendix experiences fairly frequent insults (tomato and chia seeds, popcorn kernels, and ingested foreign matter) and inflammatory events are fairly common (appendicitis). The structure swells, reddens, and is often quite painful. Classical immune responses occur (formation of germinal centers, and so on). Due to the thin walls of the appendix, inflammations induced by acute infections can rupture through to the peritoneum (peritonitis). Surgical removal of the appendix (appendectomy) is common. There is no evidence that depressed immune activity occurs following appendectomy; neighboring intestinal lymphoid tissues can apparently fill any defense voids created by appendectomy.







# IX. RESPIRATORY SYSTEM OVERVIEW

ON Use red for L and light colors throughout. (1) Begin with the structures of the respiratory system. (2) Color the cross section of the trachea (D), including the respiratory mucosa (E). (3) Color the enlargement of the mucosa in the lowest view.

- NASAL CAVITY
- PHARYNX:
- LARYNX:
- TRACHEA:
- PRIMARY BRONCHI:
- BRONCHIAL TREE:
- R. LUNG, L. LUNG:
- DIAPHRAGM:

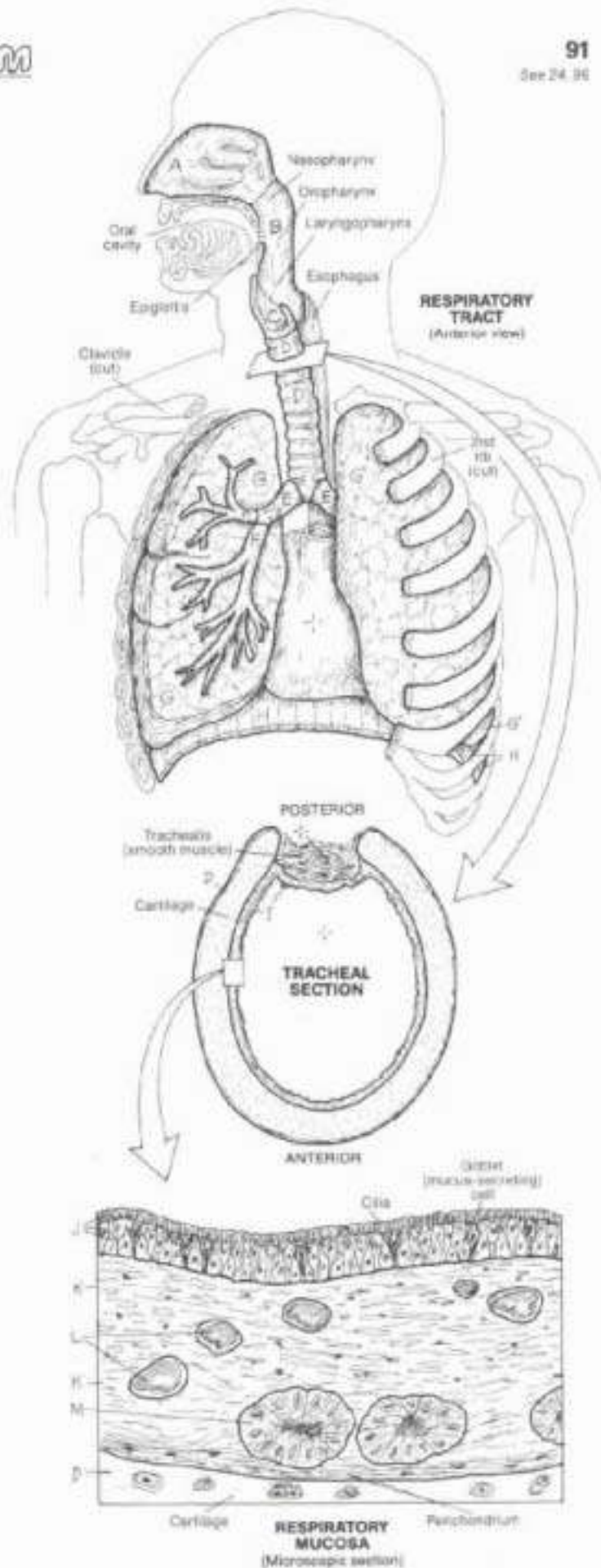
The respiratory tract conducts air to the respiratory units of the lungs where it can readily be absorbed by the blood, and it removes carbon dioxide-laden air from the air cells and exhausts it to the external atmosphere. It develops and refines sounds into potentially intelligible vocalization, and helps maintain acid-base balance of the blood by blowing off excess acid in the form of carbon dioxide. Nowhere in the body does the outside world, with all its creatures of microscopic dimension, have such easy access to the protected interior cavities of the body as it does at the air/blood interfaces of the lung. The respiratory tract has both air-conducting and respiratory (gas exchange) parts.

The air conduction tract includes an upper (nasal cavity, pharynx, larynx) and lower tract (trachea, primary bronchi and bronchial tree). The upper tract is lined with respiratory mucosa except in the lower pharynx where it has a stratified squamous epithelial surface. Except for the nose and pharynx, the skeleton of the respiratory tract is cartilaginous down to the smallest airways (bronchioles) where the cartilage is replaced by smooth muscle. Those parts associated with gaseous exchange are the smallest bronchioles and alveoli (respiratory units) and take up much of the lung's volume.

The muscular diaphragm provides much of the force necessary for inspiration and expiration of air. One quarter of that force is generated by the intercostal muscles moving the ribs.

- RESPIRATORY MUCOSA:
- PSEUDOSTRATIFIED
- COLUMNAR EPITHELIUM,
- LAMINA PROPRIA:
- BLOOD VESSEL,
- GLAND

The mucosa of the respiratory tract is largely pseudostratified columnar and (in the bronchioles) cuboidal epithelia with mucus-secreting goblet (unicellular gland) cells and cilia. Here excreted mucus traps foreign particulate matter, inhaled air is hydrated (mixed with water) putting oxygen in solution, and the air is heated from underlying vessels. These epithelial cells are supported by a loose fibrous, granular, vascular lamina propria, replete with fibroblasts and cells of the lymphoid system. Deep to this connective tissue layer is the supporting tissue (bone in nasal cavity, muscle in the pharynx, hyaline cartilage in the trachea, larynx, and bronchi, smooth muscle in the bronchioles, and thin fibers supporting the air cells).





## IX. RESPIRATORY SYSTEM

### EXTERNAL NOSE, NASAL SEPTUM, & NASAL CAVITY

CA: Use very light colors for R and L. (1) Begin with the upper illustration. (2) Color the nasal septum and its structure in the nasal cavity diagram. (3) Color the elements of the lateral wall of the nasal cavity and relations in the lowest illustration.

#### EXTERNAL NOSE:

NASAL BONE,  
CARTILAGE OF NASAL SEPTUM,  
LATERAL NASAL CARTILAGE,  
ALAR CARTILAGE,  
FIBRO-FATTY TISSUE.

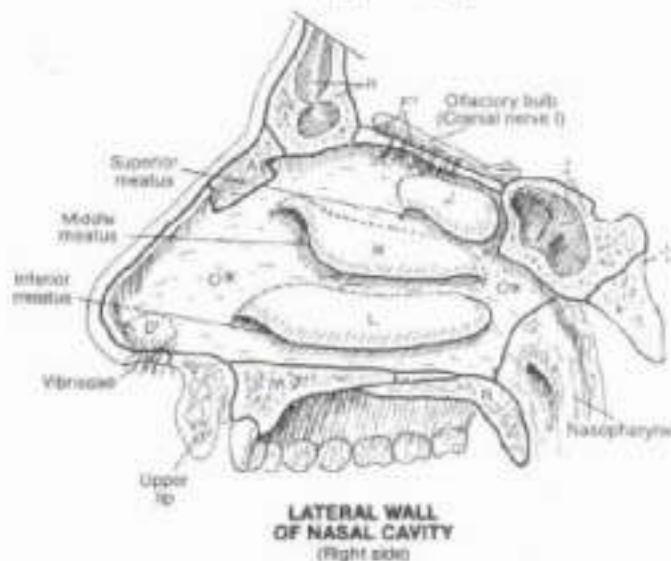
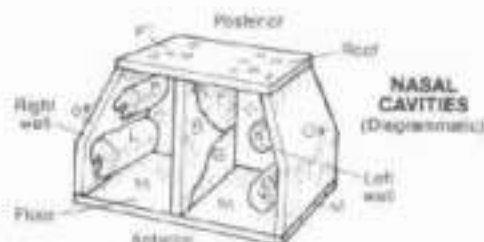
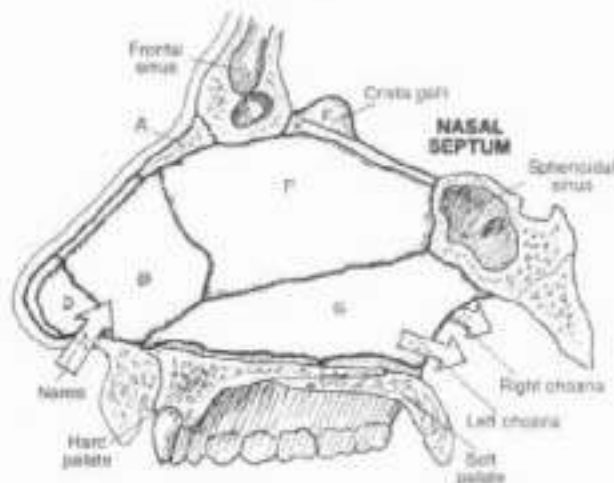
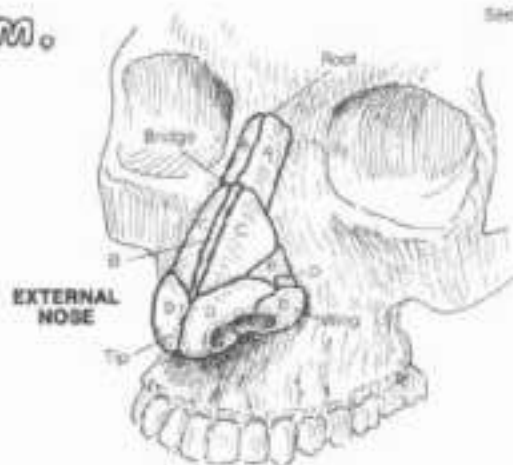
#### NASAL SEPTUM:

CARTILAGE OF NASAL SEPTUM,  
ALAR CARTILAGE,  
PERPENDICULAR PLATE  
OF ETHMOID BONE,  
VOMER BONE.

#### NASAL CAVITY & RELATIONS:

NASAL BONE,  
FRONTAL BONE,  
SPHENOID BONE,  
GRIDIRIFORM PLATE OF ETHMOID,  
VESTIBULE OF NOSE,  
SUPERIOR CONCHA,  
MIDDLE CONCHA,  
INFERIOR CONCHA,  
HARD PALATE,  
SOFT PALATE,  
LATERAL WALL.

The nose is a largely cartilaginous affair external to the skull proper. Its orifices (nares, or nostrils) open into the nasal cavity of the skull which is a bony tunnel divided by a partly cartilaginous nasal septum. The nasal cavity opens into the muscular pharynx through two bony-walled posterior apertures called choanae. The nose, situated as it is in front of the face, often receives the brunt of a facial impact. In such event, it is not unusual for the cartilage of the nasal septum (septal cartilage) to break off from the perpendicular plate of the ethmoid. This "deviated septum" may obstruct air flow through the narrowed half of the cavity. The skin-lined vestibule of the nose has long hairs (vibrissae) that serve to discourage entrance of foreign bodies. The nasal cavity is carpeted with a mucosal lining characterized by ciliated epithelial cells that secrete mucus and whose cilia sweep small particulate matter down into the nasopharynx. The bony conchae (so called because of their resemblance, in frontal section, to the conch shell) increase the surface area of the nasal cavity, significantly boosting the local temperature and moisture content. The inferior concha on each side is attached to the ethmoid bone by an immovable joint (suture); the superior and middle conchae are part of the ethmoid bone. The spaces under the conchae (meatuses) are open to paranasal sinuses (air-filled cavities), the subject of the next plate. Note the roof of the nasal cavity (cribriform plate) transmits the olfactory nerve fibers; resting on or near this plate are the frontal lobes of the brain. Note that the floor of the nasal cavity is the palate which is also the roof of the oral cavity. The soft palate is a muscular extension of the bony palate, and plays a role in swallowing.





# IX. RESPIRATORY SYSTEM

## PARANASAL AIR SINUSES

GN. Use the same colors for the bones A and B, and conchae F, G, and H, that were used for those structures on Plate 92. (1) Color the sinus drainage sites in the lateral wall of the nasal cavity. Include the edges of the conchae which have been cut away to reveal the meatuses and related drainage sites. (2) Color the coronal section. Note that it is a composite view, showing openings into the nasal cavity that do not appear in any one single coronal plane. Even so, this view cannot show the relations of the sphenoid sinus and opening, nor the mastoid air cells and the auditory tube. (3) Color the lower drawings. Note that nasolacrimal duct and the duct of the frontal sinus are shown on one side only.

### AIR SINUSES:

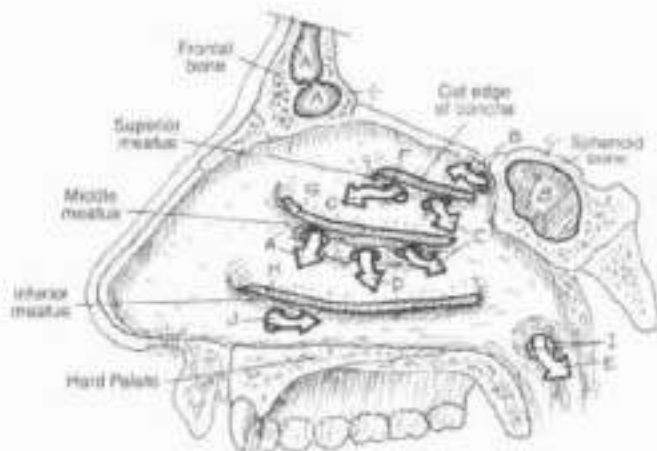
- FRONTAL<sup>A</sup>
- SPHENOID<sup>B</sup>
- ETHMOID<sup>C</sup>
- MAXILLARY<sup>D</sup>
- MASTOID<sup>E</sup>

### NASAL CONCHAE:

- SUPERIOR<sup>F</sup>
- MIDDLE<sup>G</sup>
- INFERIOR<sup>H</sup>

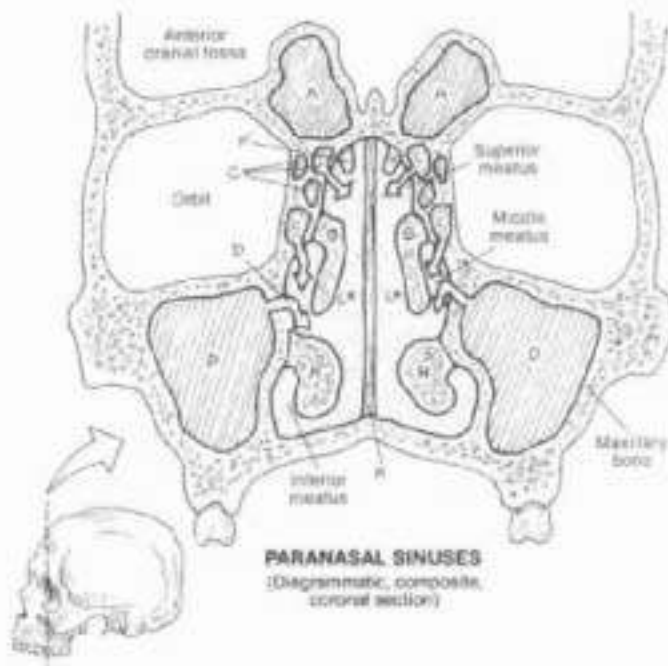
- OPENING OF AUDITORY TUBE<sup>I</sup>
- NASOLACRIMAL DUCT<sup>J</sup>
- NASAL SEPTUM<sup>K</sup>
- NASAL CAVITY<sup>L</sup>

The skull has a number of cavities in it. You are familiar with some of them (mouth, nose, external ear, orbits), but perhaps not so familiar with others. The frontal, sphenoid, maxillary, ethmoid, and temporal bones have variably sized cavities, all of which directly or indirectly communicate with the nasal cavity. These are the paranasal air sinuses, to be distinguished from the venous sinuses of the dura mater. These air sinuses serve to lighten the skull and they add timbre to the voice. They are lined with respiratory-type epithelium, which is continuous with the epithelium of the nasal cavity. The mucus secretions from these epithelial linings pass down canals and enter the nasal cavity just under the conchae (meatuses). Their specific drainage sites are indicated by the arrows. Should these passageways become blocked by inflammation and swelling, the pressure builds within the sinuses to a point where considerable pain can be experienced (sinusitis, sinus headache). Agents that constrict the blood vessels (decongestants) help to reduce the swelling and reestablish proper drainage. The mastoid air cells, in the mastoid process of the temporal bone, drain into the middle ear (tympanic) cavity, communicating by way of the auditory (pharyngotympanic) tube with the nasopharynx just posterior to the nasal cavity. The nasolacrimal duct receives secretions from the lacrimal gland which functions to keep the covering (conjunctiva) of the eye globe moist. These tears drain into sites at the medial aspect of the eyelids, which open into sacs that narrow into the nasolacrimal ducts. These ducts pass downward along the lateral walls of the nasal cavity and open into the meatus of the inferior concha on each side—and that explains how it is that one blows one's nose after one cries.



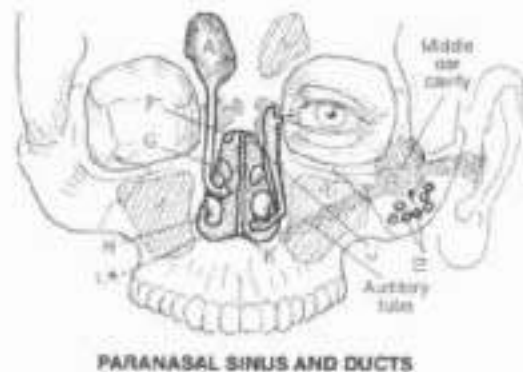
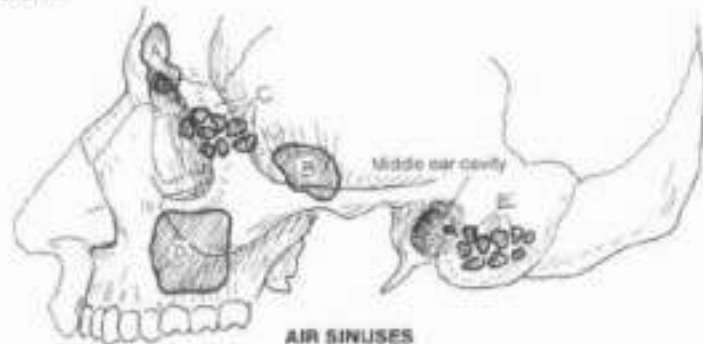
**SINUS DRAINAGE SITES**

(Right lateral wall of nasal cavity, nasal conchae removed)



**PARANASAL SINUSES**

(Diagrammatic, composite, coronal section)



# IX. RESPIRATORY SYSTEM

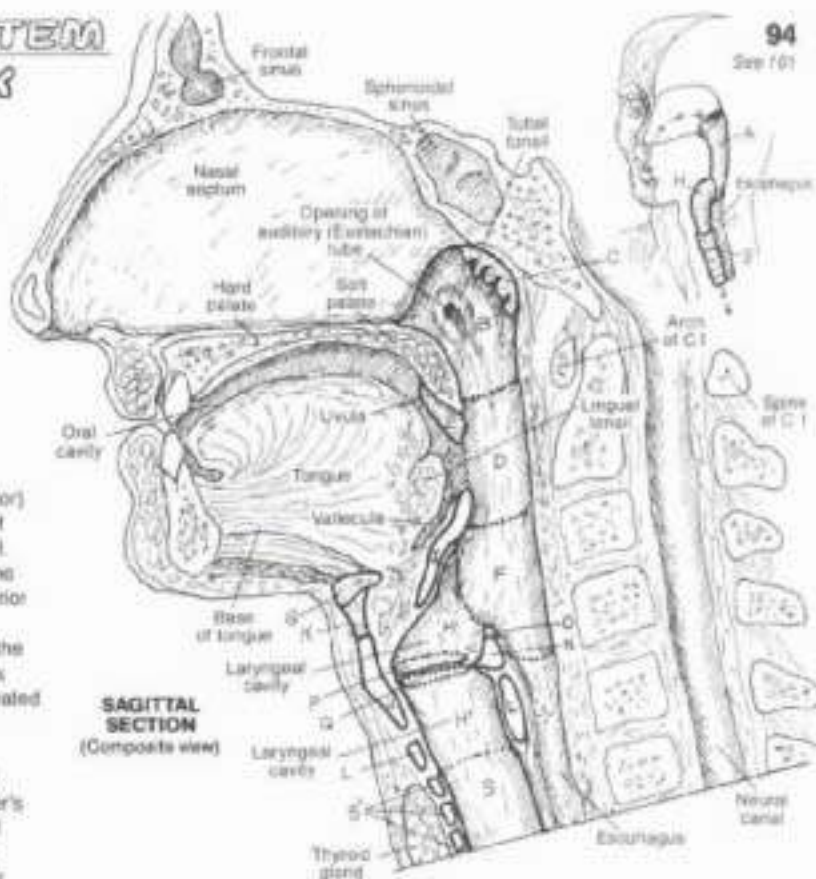
## PHARYNX & LARYNX

Ch. Use dark or light colors for N, D and G. (1) Begin with the overview diagram in the upper right corner. (2) Complete the large composite sagittal section. Take note of the surrounding structure as a frame of reference (not to be colored). (3) Color all six laryngeal views simultaneously. Note that the lobe for the laryngeal cavity (H') is at the lower right of the plate.

- PHARYNX:**  
**A NASOPHARYNX:**  
**B PHARYNGEAL TONSIL:**  
**C OROPHARYNX:**  
**D PALATINE TONSIL:**  
**E LARYNGOPHARYNX:**

The pharynx is an incomplete tube of mostly skeletal (constrictor) muscle and fibrous tissue, appearing to hang from the edges of the cranium (posterior nasal apertures) at the base of the skull. Posteriorly, it is supported by fascia in front of the sphenoid bone and the upper six cervical vertebrae. It is the posterior and inferior continuation of the nasal cavity; it is open to the oral cavity anteriorly; inferiorly, it continues as the esophagus behind and the larynx in front. Most of pharynx is lined with stratified squamous epithelium except the nasopharynx (respiratory lining). Coordinated muscular activity in the pharynx underlies the mechanism of swallowing (deglutition).

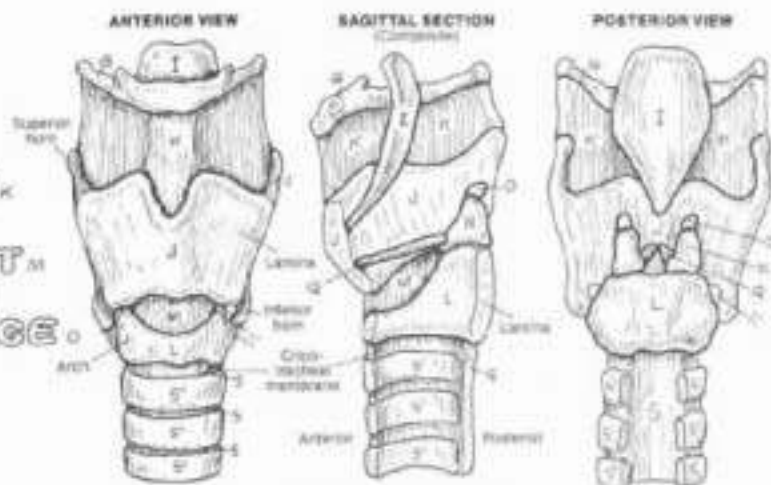
Masses of partially encapsulated lymphoid tissue incompletely encircle the nasal and oral openings into the pharynx (Waldeyer's ring), i.e., at the opening of the auditory tube (tubal tonsils), roof of the nasopharynx (adenoids), between the palatoglossal and palatopharyngeal pillars (palatine tonsils; see Plate 99), and the posterior tongue (lingual tonsils). See tonsil function in Plate 89.



**SAGITTAL SECTION**  
(Composite view)

### HYOID BONE:

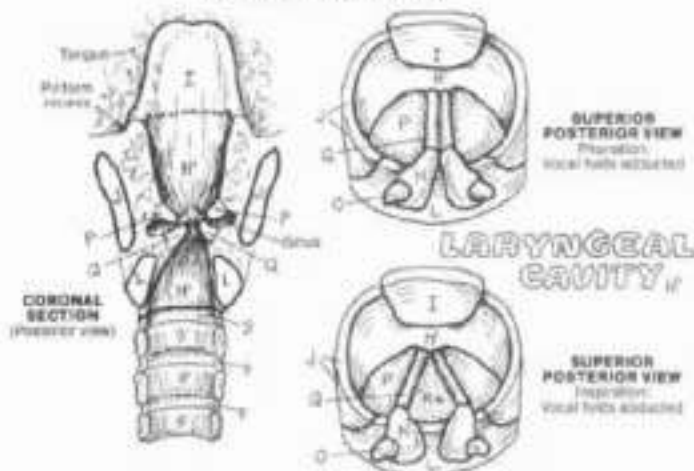
- LARYNX:**  
**H EPIGLOTTIS:**  
**I THYROID CARTILAGE:**  
**J THYROHYOID MEMBRANE:**  
**K CRICOID CARTILAGE:**  
**L CRICOTHYROID LIGAMENT:**  
**M ARYTENOID CARTILAGE:**  
**N CORNICULATE CARTILAGE:**  
**O VESTIBULAR FOLD:**  
**P VOCAL FOLD:**  
**Q RIMA GLOTTIS:**  
**R TRACHEA:**  
**S CARTILAGE:**



**VIEWS OF THE LARYNX**

The larynx provides a mechanism for sound production, manipulation of sound waves, and protection from inadvertent aspiration (inhaling) of solid matter. The larynx is supported by a framework of hyaline cartilage connected by ligaments. Although associated with the larynx, the hyoid bone is not a laryngeal structure.

The thyroid cartilage is composed of two laminae which together are V-shaped when looking at them from above. The arytenoid cartilages articulate with the top of the cricoid, pivoting on it. The vocal folds are mucosa-lined ligaments stretching between thyroid and arytenoid cartilages. They are abducted/adducted by the movement of the arytenoid cartilages. In breathing they are abducted; in coughing, they are momentarily fully adducted (closing the rima) permitting intrathoracic pressure to build, opened rapidly by abduction of the folds, the rima experiences hurricane-force winds from the depths of the respiratory airway (explosive cough). During phonation, the vocal folds are generally adducted, varying somewhat with pitch and volume. The vestibular folds (false vocal folds) are fibrous and move only passively.



**SUPERIOR POSTERIOR VIEW**  
Inspiration  
Vocal folds abducted

### LARYNGEAL CAVITY:

**SUPERIOR POSTERIOR VIEW**  
Expiration  
Vocal folds adducted



# IX. RESPIRATORY SYSTEM

## LOBES & PLEURAE OF THE LUNGS

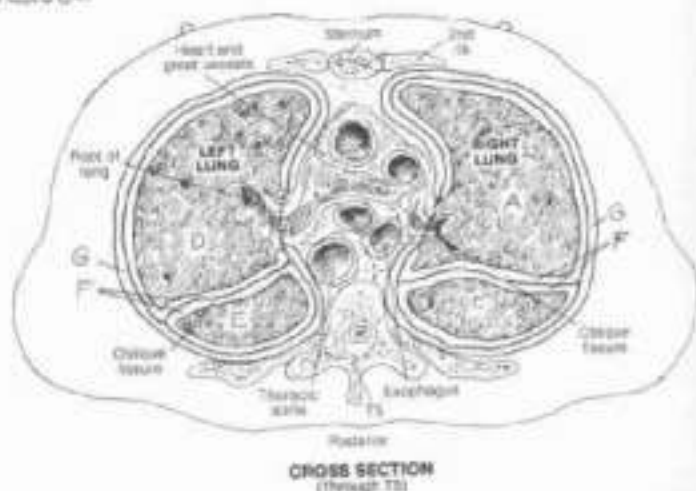
### LOBES:

R. UPPER, R. MIDDLE, R. LOWER.  
L. UPPER, L. LOWER.

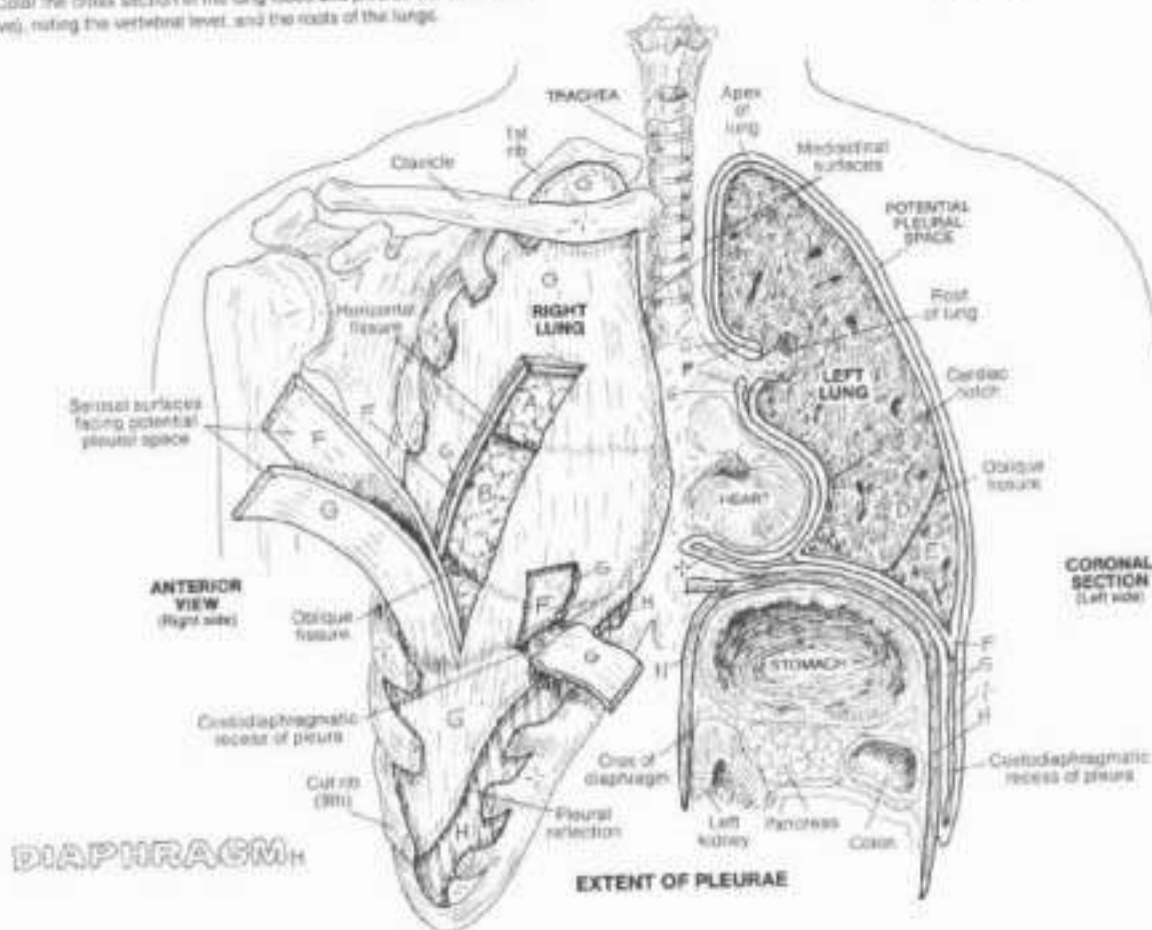
### PLEURAE:

VISCERAL PLEURA  
PLEURAL SPACE  
PARIETAL PLEURA

ON Lies bright colors for A-E, very light colors for F and G, and a reddish-brown color for H. In all of the illustrations the thickness of the pleurae (F and G) has been enlarged for coloring purposes. (1) Begin with the anterior view. Note that the ribs and intercostal muscles have been removed (see Plate 42). Sections of the pleurae have been stripped away and separated. The potential pleural space is between these layers, in the coronal and cross sections. This space is drawn as a dark line and not as a structure to be colored. Similarly, the title is also left uncolored. A small section of the parietal pleura has been cut and pulled away to reveal the underlying visceral pleura and a portion of the costodiaphragmatic recess below the lung superficial to the diaphragm. (2) Color the coronal view, noting the left crus of the diaphragm, and the cardiac notch of the left lung (3) Color the cross section of the lung lobes and pleurae (as seen from above), noting the vertebral level, and the roots of the lungs.



CROSS SECTION  
(Through T3)



EXTENT OF PLEURAE

The lobes of the lungs are largely enveloped in visceral pleura, a thin serous membrane which turns (reflects) off the lungs at their roots to become the parietal pleura which lines the inner surface of the chest wall, the lateral mediastinum, and much of the diaphragm. These serous membranes are in contact with each other, separated by a thin layer of serous (watery, glycoprotein) fluid. The interpace of these membranes is potentially a cavity or space (pleural space/cavity). With certain diseases, the space is capable of expanding to accommodate increasing amounts of fluid (pleural effusion) at the expense of the lung, resulting in a reduction of total

lung capacity. The serous fluid maintains surface tension between the pleural surfaces (resisting separation of visceral and parietal layers in contact with one another) and prevents frictional entanglement between moving pleural membranes. During quiet inspiration, the inferior and anterior margins of the visceral-pleura lined lungs do not quite reach the parietal pleura, leaving a narrow space or recess, i.e., the costomedastinal recess between the rib cage and the mediastinum (not shown), and the costodiaphragmatic recess between rib cage and diaphragm (see coronal section at lower right).

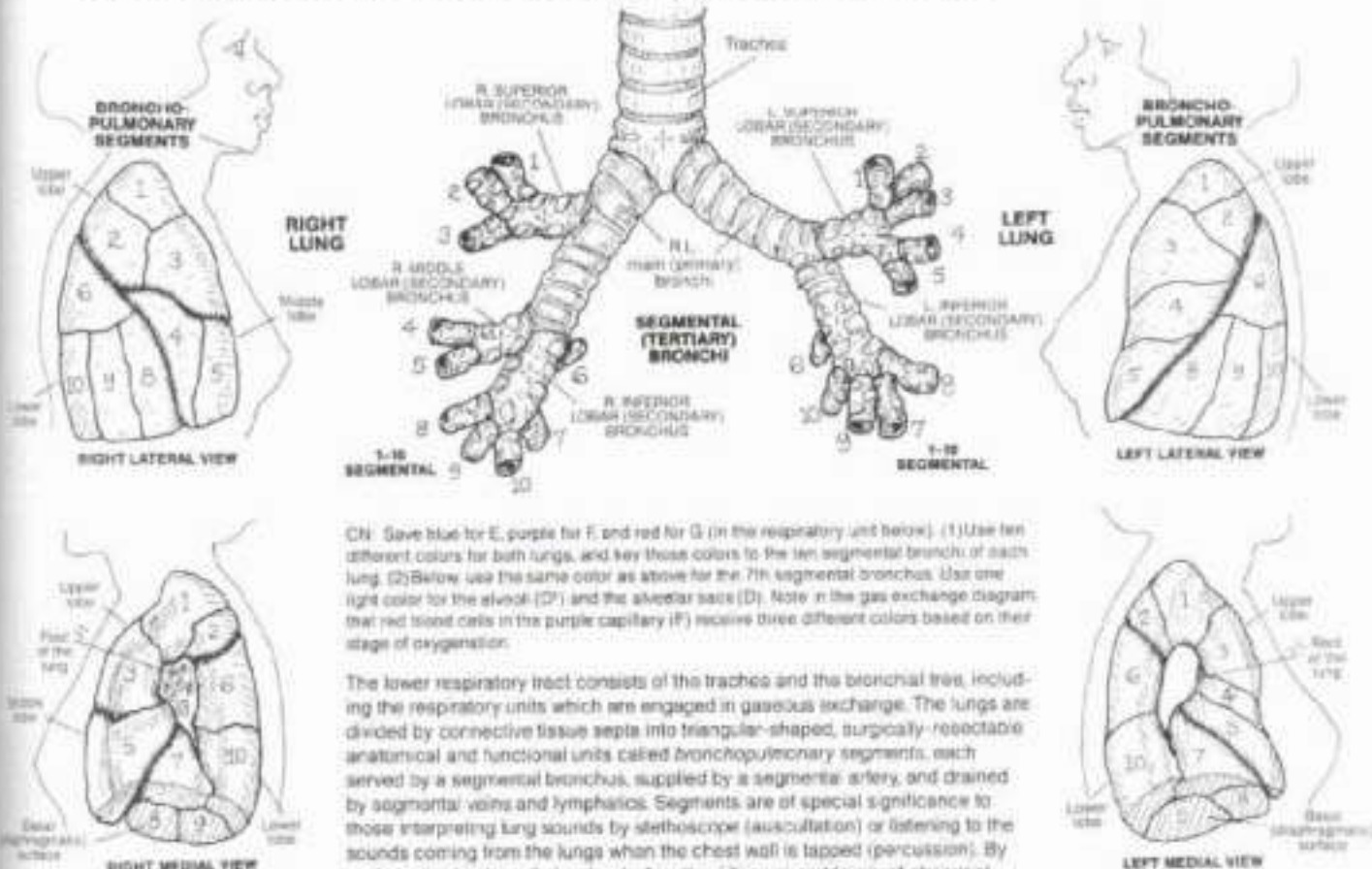


# IX. RESPIRATORY SYSTEM

## LOWER RESPIRATORY TRACT

### SEGMENTAL TERTIARY BRONCHI:

- 1 APICAL 2 POST. 3 ANT. 4 LAT. (R.L.) 6 SUP. (L.L.)  
5 MED. (R.L.) 5 INF. (L.L.) 6 SUP. 7 MED. BASAL  
8 ANT. BASAL 9 LAT. BASAL 10 POST. BASAL

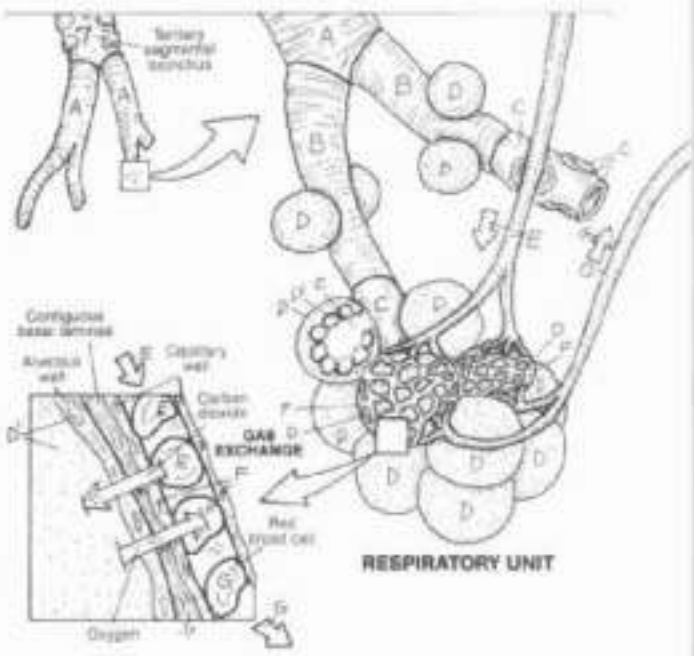


CN: Save blue for E, purple for F, and red for G (in the respiratory unit below). (1) Use ten different colors for both lungs, and key those colors to the ten segmental bronchi of each lung. (2) Below, use the same color as above for the 7th segmental bronchus. Use one light color for the alveoli (D) and the alveolar sacs (D). Note in the gas exchange diagram that red blood cells in the purple capillary (F) receive three different colors based on their stage of oxygenation.

The lower respiratory tract consists of the trachea and the bronchial tree, including the respiratory units which are engaged in gaseous exchange. The lungs are divided by connective tissue septa into triangular-shaped, surgically-resectable anatomical and functional units called bronchopulmonary segments, each served by a segmental bronchus, supplied by a segmental artery, and drained by segmental veins and lymphatics. Segments are of special significance to those interpreting lung sounds by stethoscope (auscultation) or listening to the sounds coming from the lungs when the chest wall is tapped (percussion). By such methods, sites of alveolar dysfunction/disease and levels of abnormal accumulations can often be determined.

### BRONCHIOLE, RESPIRATORY BRONCHIOLE, ALVEOLAR DUCT, ALVEOLAR SAC, & ALVEOLUS, PULMONARY ARTERIOLE, CAPILLARY NETWORK, PULMONARY VENULE.

Within each bronchopulmonary segment, a segmental bronchus branches into several bronchioles (less than 1 mm in diameter, supported by smooth muscle instead of cartilage). These bronchioles give off smaller terminal bronchioles, characterized by ciliated cuboidal cells without glands. The terminal bronchioles represent the end of the air-conducting pathway. Each terminal bronchiole divides into two or more respiratory bronchioles, characterized by occasional alveolar sacs on their walls. Each respiratory bronchiole supplies a respiratory unit which is a discrete group of air cells (alveoli), arranged in alveolar sacs, fed by alveolar ducts. Extending from its source bronchiole, each respiratory bronchiole has more and more alveolar sacs, terminating as an alveolar duct opening into alveolar sacs. The walls of the air cells, composed of simple squamous epithelia supported by thin interwoven layers of elastic and reticular fibers, are surrounded by capillaries which arise from pulmonary arterioles and become the tributaries of pulmonary venules. The walls of these capillaries are fused to and structurally similar to those of the alveoli. Oxygen and carbon dioxide rapidly diffuse, on the basis of pressure gradients, through these walls.



# IX. RESPIRATORY SYSTEM

## MECHANICS OF RESPIRATION

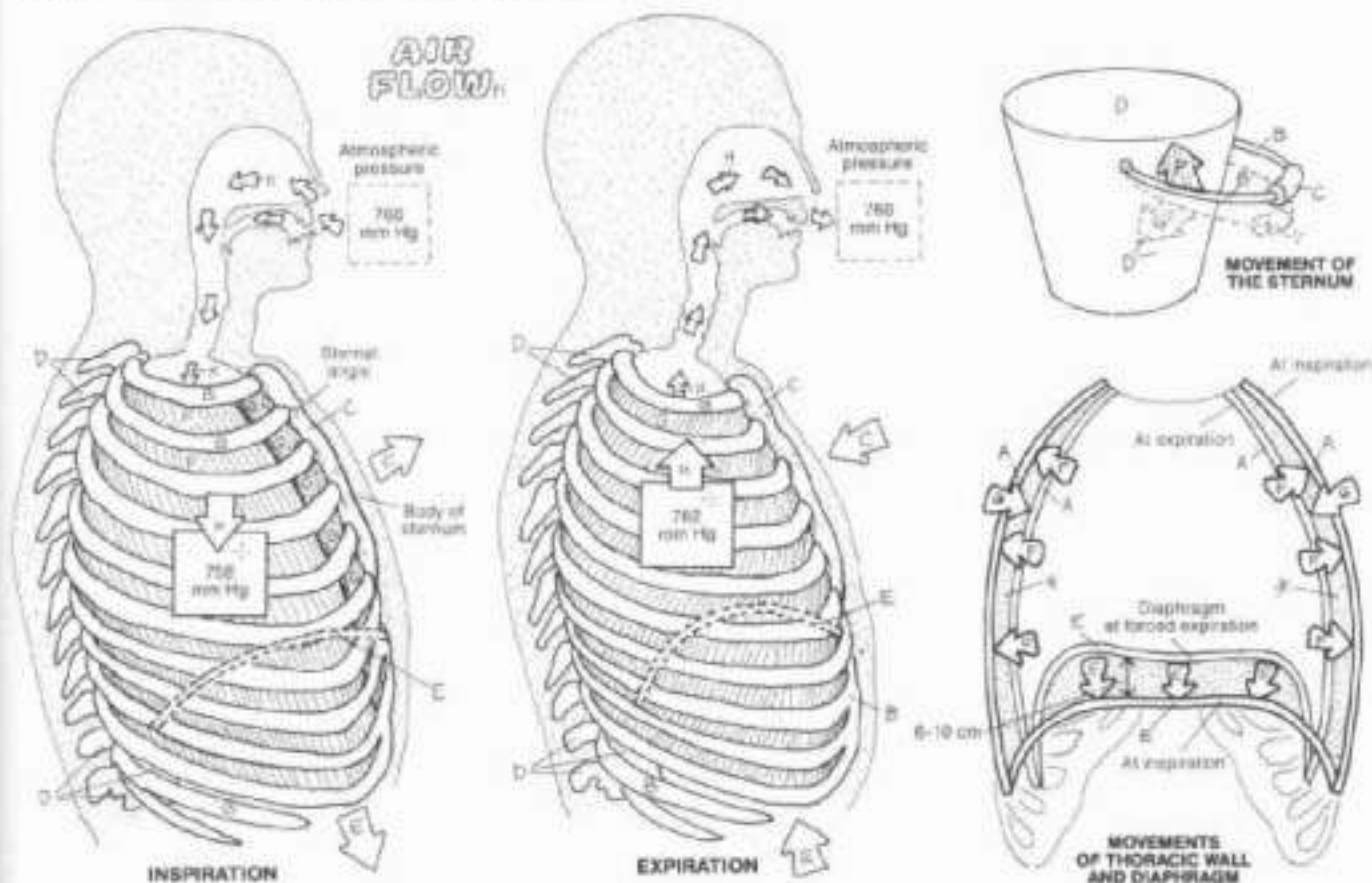
CH. Use light colors throughout, except for a bright or dark color for E. (1) Design with the illustration at far left (inspiration); note that the thoracic wall (A) is shown only in the far right

diagram. Color the diaphragm, its location represented by broken lines. (2) Color the expiration illustration and the bucket handle analogy (3) Finish with the illustration at far right.

**THORACIC WALL:**  
**RIB & COSTAL CARTILAGE:**  
**STERNUM:**  
**THORACIC VERTEBRAE:**

**MUSCLES OF INSPIRATION:**  
**DIAPHRAGM**  
**EXTERNAL INTERCOSTAL**

**MUSCLE OF EXPIRATION:**  
**INTERNAL INTERCOSTAL**



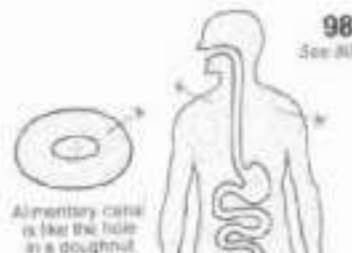
The mechanism of respiration makes possible breathing which consists of inhalation (inspiration) and exhalation (expiration) phases. The physical principle underlying air movement in/out of the thorax is the inverse relationship of pressure and volume (as one goes up, the other goes down). Volume changes within the thorax alter the intrathoracic pressure 1-2 mm Hg above/below atmospheric pressure (outside the body) in quiet breathing enough of a change to move about 500 ml of air with each breath. The thoracic diaphragm accomplishes about 75% of the inspiratory effort, the external intercostals 25%. Expiration is largely diaphragm and external intercostal relaxation/stretch, and lung elasticity, with some help from the internal intercostals. In inspiration, contraction of the diaphragm flattens the muscle and lowers the floor of the thorax, increasing the vertical dimension of the thoracic cavity. Contraction of the external intercostals

elevates the ribs, swinging the sternal body slightly outward at the sternal angle. This increases the transverse and anteroposterior dimensions of the thoracic cavity. These actions collectively increase the intrathoracic volume, momentarily lowering the pressure within. Given the relatively higher atmospheric pressure outside the head, air is induced to enter the respiratory tract to find lower pressure. The action of the bucket handle demonstrates the hinge action at the sternal angle and related rib elevation. In expiration, the relaxed diaphragm forms "domes" over the underlying liver and stomach, decreasing the vertical dimension of the thorax. Recoil/descent of the ribs decreases the transverse and anteroposterior dimensions. The thoracic volume is thus decreased, momentarily increasing the intrathoracic pressure above atmospheric. Air escapes to the outside, aided by the natural elastic recoil of the lungs.

# X. DIGESTIVE SYSTEM

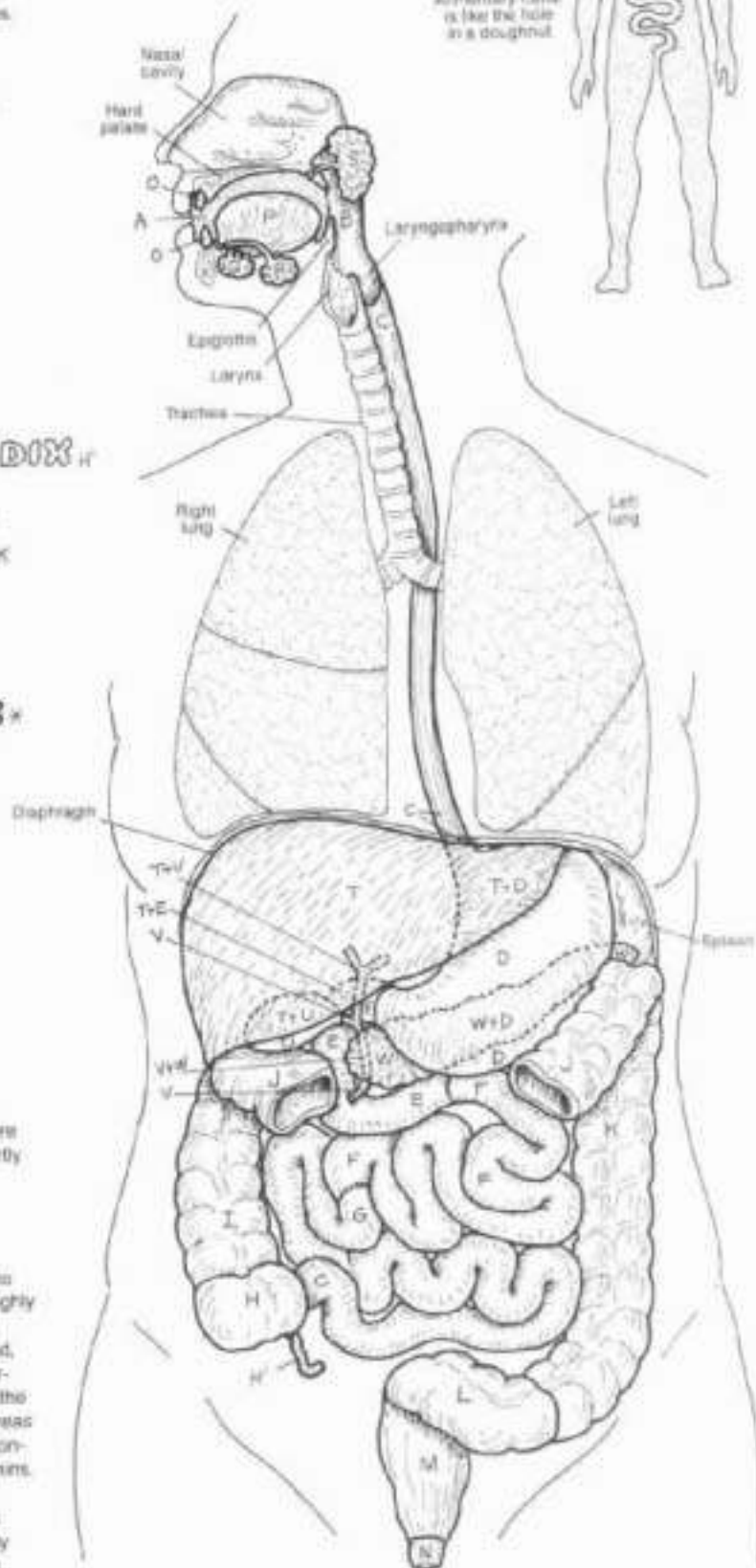
## OVERVIEW OF THE SYSTEM

DN. When coloring the organs that overlap each other, use your lightest colors for D, E, T, V, and W. Each overlapping portion receives the color of both structures. (1) After coloring the alimentary canal, review the structures before completing the accessory organs. The central section of the transverse colon (L) has been removed to show deeper structures.



- ALIMENTARY CANAL:**
- ORAL CAVITY<sup>A</sup>
  - PHARYNX<sup>B</sup>
  - ESOPHAGUS<sup>C</sup>
  - STOMACH<sup>D</sup>
  - SMALL INTESTINE:
    - DUODENUM<sup>E</sup>
    - JEJUNUM<sup>F</sup>
    - ILEUM<sup>G</sup>  - LARGE INTESTINE:
    - CECUM<sup>H</sup>
    - VERMIFORM APPENDIX<sup>I</sup>
    - ASCENDING COLON<sup>J</sup>
    - TRANSVERSE COLON<sup>K</sup>
    - DESCENDING COLON<sup>L</sup>
    - SIGMOID COLON<sup>M</sup>
    - RECTUM<sup>N</sup>
    - ANAL CANAL<sup>O</sup>

- ACCESSORY ORGANS:**
- TEETH<sup>A</sup>
  - TONGUE<sup>B</sup>
  - SALIVARY GLANDS:
    - SUBLINGUAL<sup>C</sup>
    - SUBMANDIBULAR<sup>D</sup>
    - PAROTID<sup>E</sup>  - LIVER<sup>F</sup>
  - GALL BLADDER<sup>G</sup>
  - BILE DUCTS<sup>H</sup>
  - PANCREAS<sup>I</sup>



The digestive system consists of an alimentary canal with accessory organs. The canal begins with the oral cavity. Here the teeth pulverize ingested food while it is softened and partly digested by salivary gland secretions. The tongue aids in mechanical manipulation of the food, and iterarily flips the food into the fibromuscular pharynx during swallowing.

The esophagus moves the bolus along to the stomach by peristaltic muscular contractions. Here the bolus is treated to mechanical and chemical digestion, then passed into the tightly coiled small intestine for more enzymatic and mechanical digestive processes. Small molecular nutrients are extracted, absorbed by living cells, and transferred to capillaries. Liver-produced bile, stored in the gall bladder, is discharged into the duodenum by bile ducts. Digestive enzymes from the pancreas enter the duodenum as well. The large intestine is mainly concerned with absorption of water, minerals, and certain vitamins. The non-nutritive residue of the ingested bolus is moved through the rectum and anal canal to the outside. Nutrients absorbed throughout the tract are transported to the liver by the hepatic portal system for processing and distribution to the body's cells.



# X. DIGESTIVE SYSTEM

## ORAL CAVITY & TONGUE

Color the pink for K and very light colors for A, B, T, U, and V. Do not color the teeth. (1) When coloring the mouth, also color many of those structures that appear in the sagittal view. (2) It is not necessary to color all of the papillae of Q and R.

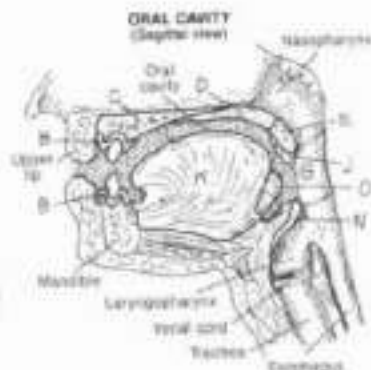
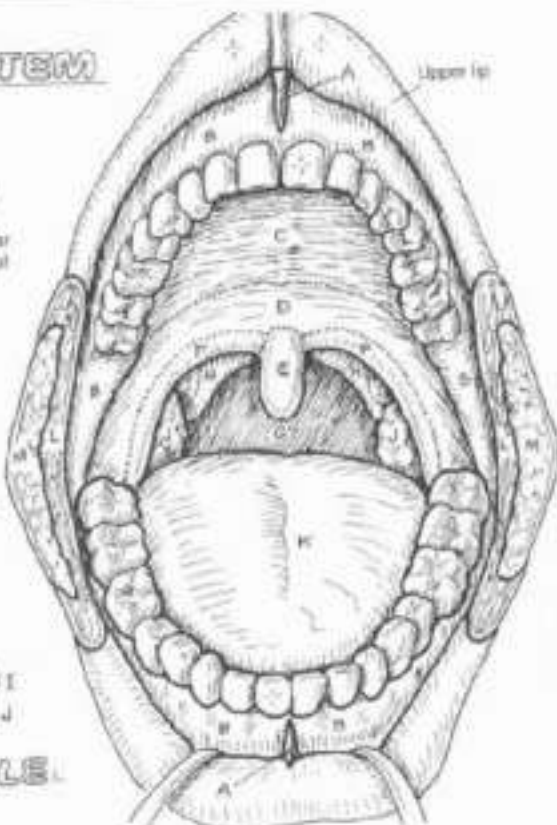
**FREQUULUM OF LIP,**  
**GINGIVA (GUM),**  
**HARD PALATE,**  
**SOFT PALATE,**

**UVULA,**  
**PALATOGLOSSAL**  
**ARCH,**

**OROPHARYNX,**  
**PALATOPHARYN-**  
**GEAL ARCH,**

**TONSILLAR FOSSA,**  
**PALATINE TONSIL,**

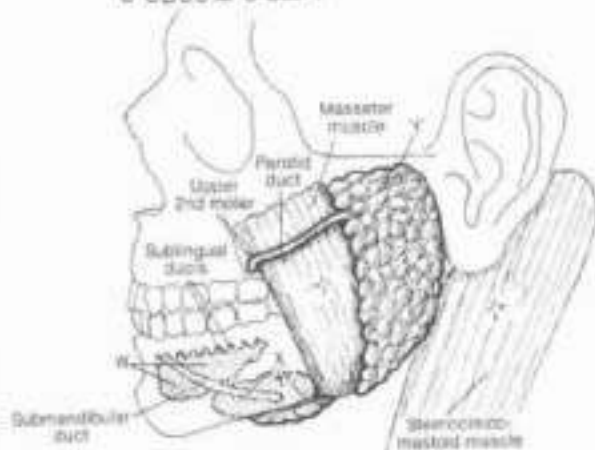
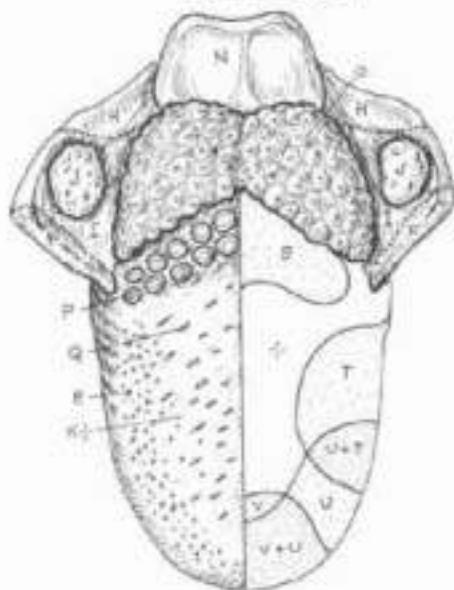
**TONGUE,**  
**BUCCINATOR MUSCLE,**  
**BUCCAL FAT,**



**EPIGLOTTIS,**  
**LINGUAL TONSIL,**  
**PAPILLAE:**  
**CIRCUMVALLATE,**  
**FILIFORM,**  
**FUNGIFORM,**  
**TASTE REGIONS:**  
**BITTER,**  
**SOUR +**  
**SALT,**  
**SWEET,**

The human mouth is concerned with vocalization as well as mastication and swallowing (deglutition). Its anterior half, including teeth, muscular tongue and related intrinsic muscles, salivary glands, hard (bony) palate, and buccinator muscle in the cheek wall, is concerned with wetting, macerating, and pulverizing ingested material. Thousands of mucous glands in the stratified squamous-lined mucosa of the mouth assist in these functions, as do the multiple, microscopically-lingering papillae on the surface of the tongue, the latter forming an abrasive surface for mechanical digestion. The temporomandibular joints permit a fairly wide range of lower jaw motion and mouth opening (35-50 mm interincisal range in the adult). The posterior half of the mouth, including soft (muscular) palate, tongue, and tonsils between the muscular arches, is concerned with immune defense and propelling the mechanically treated food into the pharynx. Sense receptors (taste buds) buried among the papillae on the tongue surface are responsive to chemical stimuli dissolved in the saliva. These receptors are arranged in a pattern reflecting specific sensitivity to molecular variations, i.e., bitter, sour, salt, and sweet tastes.

**SALIVARY GLANDS:**  
**SUBLINGUAL,**  
**SUBMANDIBULAR,**  
**PAROTID,**



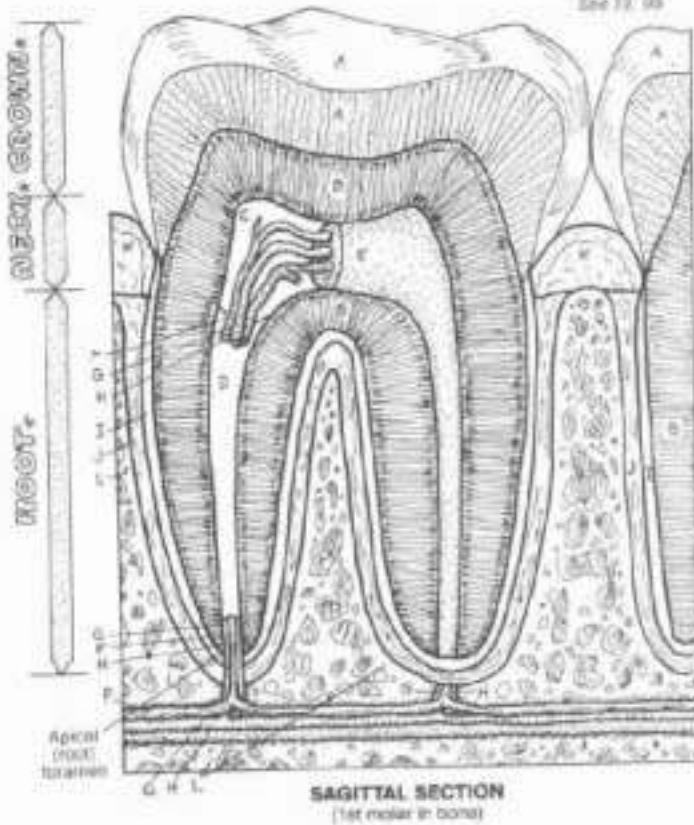
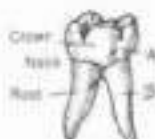Salivary glands secrete a mixed water/mucous, enzyme-containing fluid into the mouth during periods of eating (or anticipated eating). Specialized muscle (myoepithelial) cells at the base of the glands stimulate secretion into the ducts following stimulation by autonomic nerves. The sublingual glands are the smallest of the three paired glands. Their ducts open on to the floor of the mouth, as do the ducts of the submandibular gland. The parotid gland is the largest, sending its duct across the masseter muscle, through the cheek, and into the oral cavity opposite the upper 2nd molar tooth.

# X. DIGESTIVE SYSTEM

## ANATOMY OF A TOOTH

Clk Use yellow for E, red for G, blue for H, and light colors for A, B, and L.  
 (1) Begin with the anatomy of a tooth. Color gray the stripes and arrows/bands arranged vertically. (2) Use only light colors on the teeth below. You may repeat colors used on the upper illustration. Note that the identifying letter and number labels are those used by the dental profession.

- ENAMEL A
- DENTIN B
- PULP CAVITY: D
- ROOT CANAL: E
- PULP F
- NERVE-ARTERY-VEIN: G, H
- CEMENTUM: I
- PERIODONTAL MEMBRANE: J
- GINGIVA: K
- ALVEOLAR BONE: L



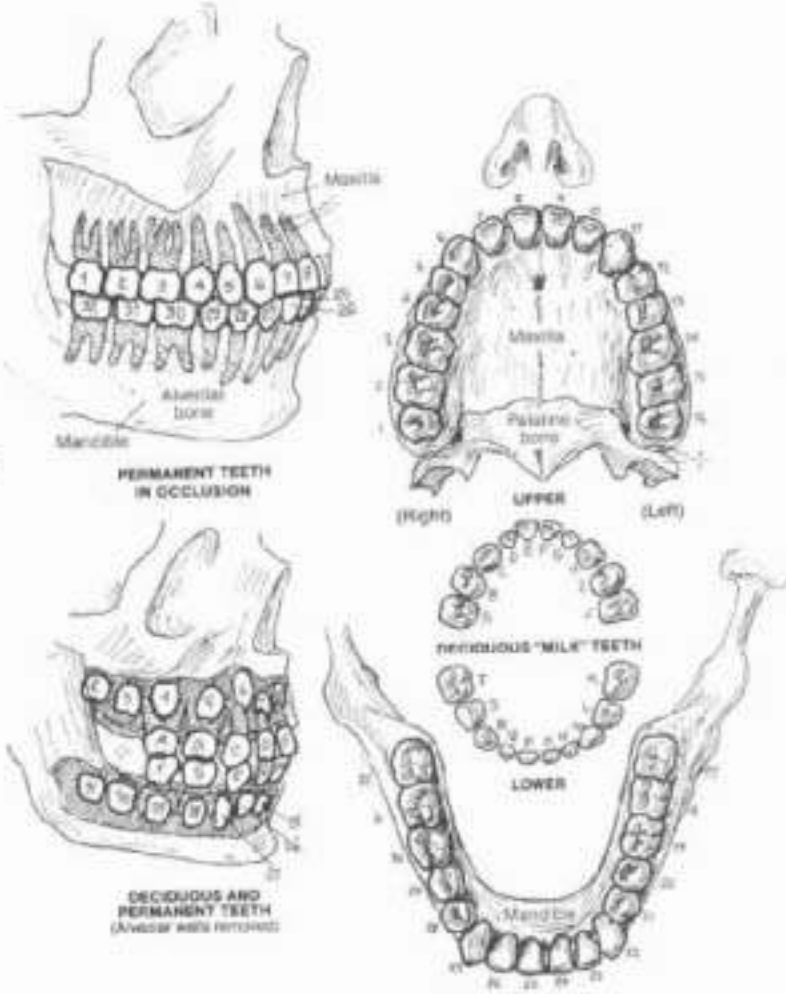
The tooth is a hollow core of sensitive, mineralized dentin filled with a loose fibrous, vascular pulp, capped with insensitive mineralized enamel projecting above the gingiva (gum), buried within the bony socket (alveolus) of the mandible/maxilla and secured to that periodontal-lined bone by cementum. The bulk of the tooth is rooted in bone, the neck of the tooth is at the gum line. The crown is dentin covered with 1-1.5 mm thick enamel. Enamel is the hardest substance in the body, weighing in at 99% mineral content. It consists of circular rods arranged in a wave pattern stuffed with hydroxyapatite (bone) mineral crystals. During development, non-mineralized enamel (it mineralizes later) is secreted by cells which are worn off the enamel surface when the tooth erupts and becomes exposed.

Dentin is a bone-like material (70% mineral by weight) secreted in tubular form by cells at the dentin-pulp junction. With aging, the pulp diminishes in volume, replaced by dentin. The pulp cavity is filled with an embryonic connective tissue supporting nerves, arteries, and veins that supply the tooth. Pulp passes through a root (or pulp) canal to reach the apical or root foramen. The pulp is continuous with the periodontal membrane, a dense fibrous tissue similar to periosteum. Cementum is like bone, mineralized with a significant content of collagen fibers. It serves as an intermediate tissue between dentin and the periodontal membrane, with many of its fibers buried in alveolar bone. The gingiva, lined with keratinized stratified squamous epithelium, is part of the mucous membrane of the mouth, and surrounds the neck of each tooth. The gingival epithelial cells are attached to the tooth surface. The gingiva is firmly anchored to the periosteum of the underlying alveolar bone.

### ADULT/CHILD DENTITION:

- CENTRAL INCISOR E, 5, 24, 25, F, F, C, P
- LATERAL INCISOR T, 10, 23, 26, D, S, N, Q
- CANINE C, 11, 22, 27, C, H, M, R
- 1ST PREMOLAR 5, 12, 21, 29
- 2ND PREMOLAR 4, 13, 20, 29
- 1ST MOLAR 2, 14, 19, 30, B, I, L, S
- 2ND MOLAR 3, 15, 18, 31, A, J, K, T
- 3RD MOLAR (WISDOM) 1, 14, 17, 32

Two sets of teeth develop within a lifetime. The first set are deciduous (milk teeth). There are 10 in each jaw. The incisors are usually the first to erupt at about 6 months, the rest follow within 36 months after birth. Pressure from the permanent teeth induce osteoclastic resorption of the milk teeth roots, and subsequently the remaining crowns dislodge and fall out without pain or bleeding. In the permanent set, the first molar or central incisor erupts first (at about 6 years). The second molar erupts around 11 years of age; the third molar generally emerges about 18 years ("wisdom tooth").



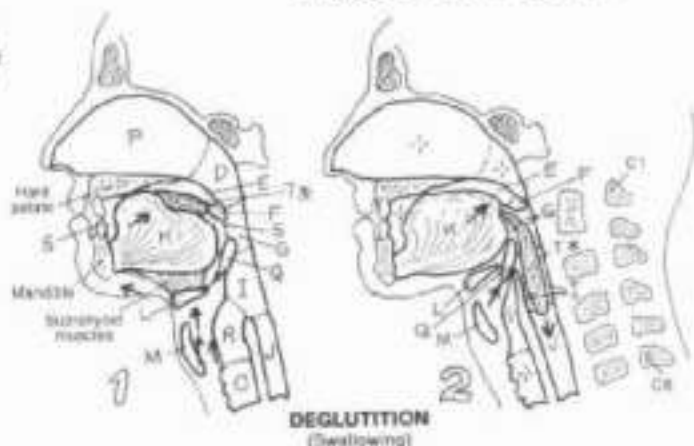
# X. DIGESTIVE SYSTEM

## PHARYNX & ESOPHAGUS

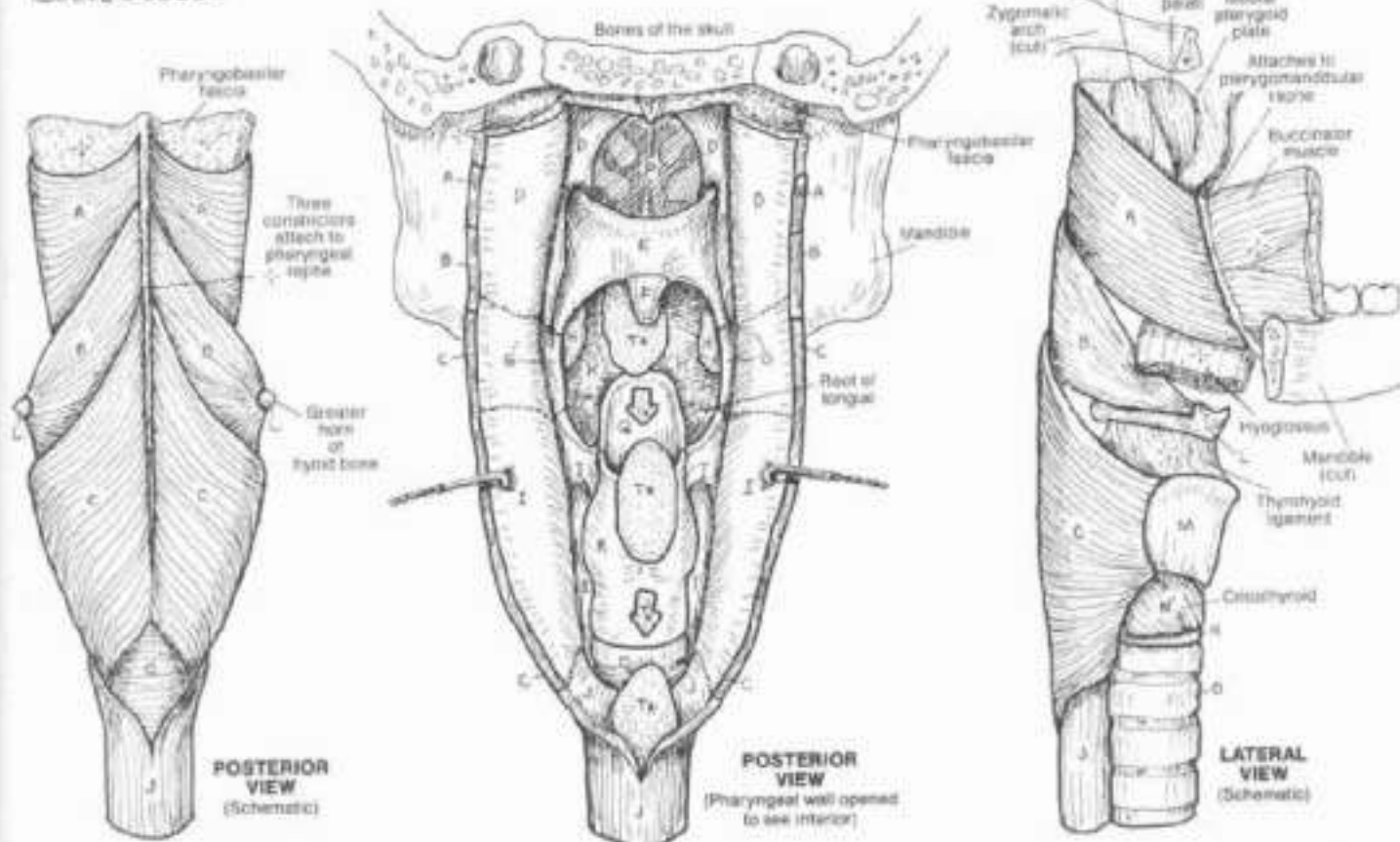
CN: Use pen for K. (1) Color the three lower illustrations simultaneously in the posterior view of the interior of the pharynx, the posterior pharyngeal wall is divided and abstracted so you can note the relationship of internal pharyngeal structure to the constrictor muscles (A, B, C) and the subdivisions of the pharynx (D, G, I). Color gray the boluses of food in both upper and middle lower views, and the files at upper right. (2) Follow the text when coloring the deglutition diagrams.

- MUSCULAR WALL OF PHARYNX:**
- SUPERIOR CONSTRICTOR,**
- MIDDLE CONSTRICTOR,**
- INFERIOR CONSTRICTOR:**
- INTERIOR OF PHARYNX:**
- NASOPHARYNX,**
- SOFT PALATE:**
- UVULA**
- OROPHARYNX:**
- PALATINE TONSIL**
- LARYNGOPHARYNX:**
- ESOPHAGUS,**
- RELATED STRUCTURES:**
- TONGUE**
- HYOID BONE,**
- THYROID CARTILAGE**
- CRICOID CART. & MUS.**
- TRACHEA,**
- NASAL CAVITY,**
- EPIGLOTTIS,**
- LARYNX:**

### ORAL CAVITY: BOLUS OF FOOD



The pharynx is a complex fibromuscular, mucosa-lined sac, open to the nasal cavity above, the oral cavity in front, and the larynx and esophagus below. Like three stacked pots, the constrictor muscles of the pharyngeal wall overlap one another posteriorly and posterolaterally. Several small muscles (not shown) reinforce the constrictor muscles structurally and functionally. The pharyngeal muscles are primarily concerned with deglutition. Swallowing begins with pushing the food bolus from the oral cavity into the oropharynx (1). This is done with the tongue assisted by the suprahyoid muscles pulling the hyoid bone and larynx upward. The soft palate (levator palati) then elevates and the superior constrictors contract, closing off the nasopharynx. Incarcerated in the oral pharynx, unable to return to the mouth or enter the nasal cavity, the bolus shoots into the laryngopharynx (2) with the aid of the middle and inferior constrictors, past the closed larynx (pinched off by the aryepiglottic folds) and into the esophagus.

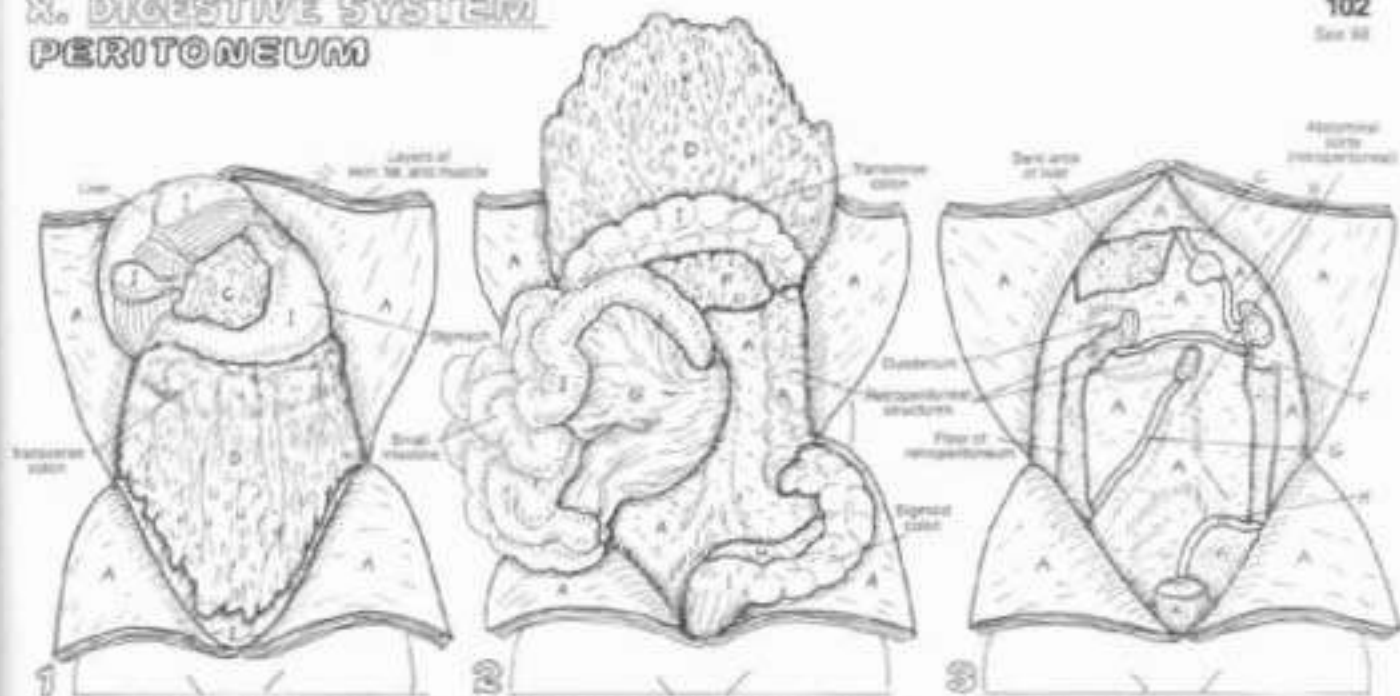




# X. DIGESTIVE SYSTEM

## PERITONEUM

102  
See 44



With the anterior abdominal wall opened through its diaphragm (parietal peritoneal) layer, the liver, stomach, and the fatty greater omentum are generally all that can be seen with the contents undisturbed. Lifting the liver exposes the lesser omentum, a double-peritoneal layer between stomach and liver. It is the anterior wall of the omental bursa (E). The greater omentum connects the transverse colon to the stomach.

With the greater omentum lifted, the double-layered transverse mesocolon between transverse colon and the parietal peritoneum can be seen. Retracting the intestines to one side reveals the common mesentery between most of the small intestine and the parietal peritoneum on the posterior body wall. The sigmoid colon has a mesentery (sigmoid mesocolon) as well. Additional structures posterior to these mesenteries/omenta are retroperitoneal.

The parietal peritoneum of the posterior body wall is seen when all structures except retroperitoneal (pancreas, inferior vena cava, kidneys, ureters, pancreas, duodenum, ascending/descending colon) are removed. Many nerves and vessels travel in this retroperitoneal space. As organs emerge from the peritoneum, they develop a mesentery to support them. The cut layers of several of them can be seen (C, D, F, G, and H).

ON Use a very light color for A and I. (1) Color the upper three diagrams in numerical order. Note that the digestive organs are covered with visceral peritoneum (I). (2) Color the sagittal view like a darker gray or black for the omental bursa (E). The space of the peritoneal cavity (G) has been greatly exaggerated for clarity of peritoneal membranes.

### PERITONEAL STRUCTURES:

**PARIETAL PERITONEUM:** A

**PERITONEAL CAVITY:** G

**LESSER OMENTUM:** C

**OMENTAL BURSA:** E

**GREATER OMENTUM:** D

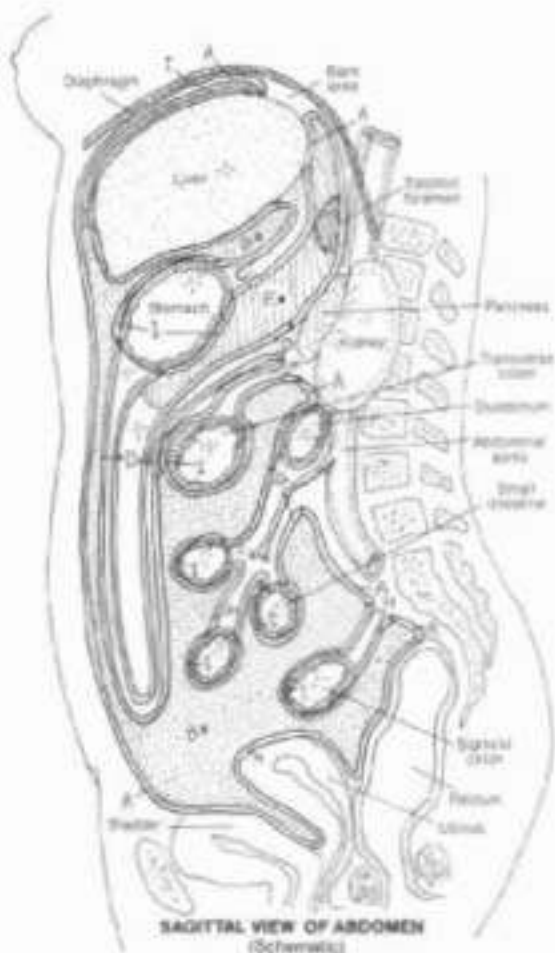
**TRANSVERSE MESOCOLON:** B

**COMMON MESENTERY:** F

**SIGMOID MESOCOLON:** H

**VISCERAL PERITONEUM:** I

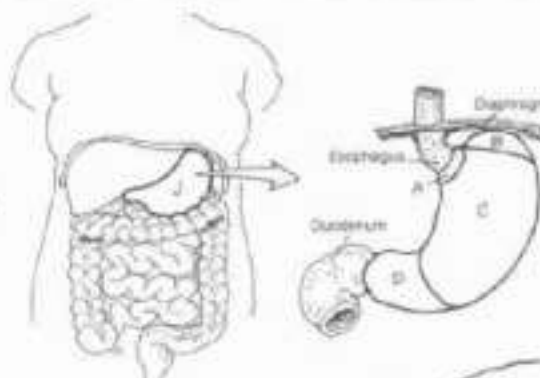
Peritoneum is a serosal membrane of the abdominal cavity. The disposition of the peritoneum is similar to that of the serosal layers around heart (pericardium) and lungs (pleurae): peritoneum attached to the body wall is parietal; peritoneum attached to the outer visceral wall is visceral. Structures deep to the posterior parietal peritoneum are retroperitoneal. Peritoneal layers suspending organs are called mesenteries; those suspending an organ from another organ are called omenta or ligaments. When coloring the sagittal view, the continuity of these peritoneal membranes can be appreciated. The cavity of the peritoneum is empty; it can fill with fluid in disease and trauma. The view at right shows intestines separated apart from one another; in life, they are as close together as strands of coiled wet rope. Vessels/nerves to the intestines and stomach travel in the mesenteries/omenta; they do not penetrate peritoneal layers. The source vessels are retroperitoneal. The omental bursa is a peritoneal-lined sac created by rotation of the stomach during fetal life. It is open on the right at the epiploic foramen between the lesser omentum and the parietal peritoneum. Here the omental bursa (lesser sac) communicates with the collapsed, empty peritoneal cavity (greater sac).



# X. DIGESTIVE SYSTEM

## STOMACH

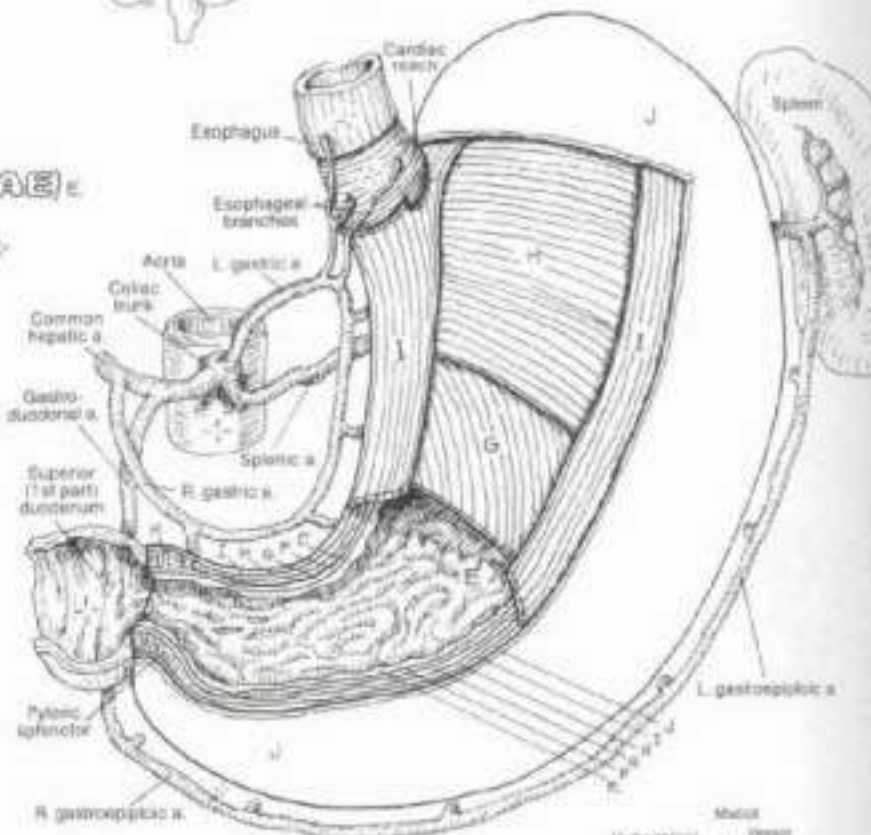
(1) Use light colors for E-I and G. (2) Color and articulate the large view of the stomach and the section of the stomach wall. The layers of the wall in the large view have been enlarged to facilitate coloring. Note the oblique muscle (G) does not reach the duodenum. (3) Color the lower diagrams.



### REGIONS:

- CARDIA
- FUNDUS
- BODY
- PYLORUS

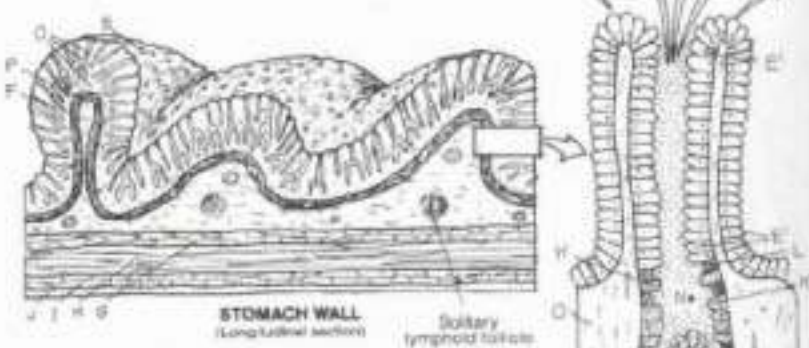
- ### STOMACH WALL:
- MUCOSAL SURFACE (RUGAE)
  - SUBMUCOSA
  - MUSCULARIS EXTERNA:
    - OBLIQUE M.
    - CIRCULAR M.
    - LONGITUDINAL M.
  - SEROSA



The stomach is the first part of the gastrointestinal tract. It acidifies ingested food to enhance protein digestion and kill microorganisms, secretes proteolytic enzymes (pepsin), mechanically manipulates digesting food, and induces secretion of bile and pancreatic enzymes. The cardia is the area of the gastroesophageal junction, though there is circular muscle here, it relaxes during swallowing. The pylorus is thickened with circular muscle near the duodenal junction (pyloric sphincter). Its regulatory function has been questioned.

While coloring note carefully the organization of the stomach wall, the mucosa is considered below. The fibrous, vascular submucosa provides some support for the larger vessels and nerves traveling in this layer. When the stomach is not full, the mucosa and submucosa are often thrown into a series of irregular folds (rugae). The different orientations of the muscularis externa layer provide complex and effective peristaltic movements during digestion.

The mucosa of the stomach, lined with simple columnar epithelial cells with microvilli, contains a sub-epithelial, vascular, loose, fibrous tissue layer (lamina propria) supporting the gastric glands. It contains numerous fibroblasts and particularly dense masses of lymphocytes (lymphoid follicles; see Plate 84). The fundus and body reveal tubular-shaped gastric glands that exhibit deep gastric pits, a neck (largely mucous cells) and a base containing mucous cells, parietal cells secreting hydrochloric acid, chief cells secreting the protein-lysing enzyme pepsin, and enteroendocrine cells secreting gastrointestinal regulatory hormones. The parietal cells also secrete intrinsic factor, a glycoprotein which binds with vitamin B<sub>12</sub> and permits the latter's absorption in the ileum of the small intestine. Malabsorption of intrinsic factor leads to vitamin B<sub>12</sub> deficiency which induces abnormal erythrocyte (RBC) development and subsequent pernicious anemia. The pylorus contains largely mucous glands as well as enteroendocrine cells secreting gastrin, a polypeptide. It stimulates secretion of pepsin and acid in the stomach, and augments gastric muscle contractions (increased motility). The smooth muscle fibers of the thin muscularis mucosae participate in the mechanical digestive process.



- ### MUCOSA:
- EPITHELIAL LAYER:
    - MUCOUS CELL
    - PARIETAL CELL
    - CHIEF CELL
    - ENTEROENDOCRINE CELL
  - GASTRIC PIT
  - LAMINA PROPRIA
  - MUSCULARIS MUCOSAE

GASTRIC PIT OF THE FUNUS (Diagrammatic)



# X. DIGESTIVE SYSTEM

## SMALL INTESTINE

### DUODENUM:

- SUPERIOR (1ST) PART;
- DESCENDING (2ND) PART;
- HORIZONTAL (3RD) PART;
- ASCENDING (4TH) PART.

### JEJUNUM:

### ILEUM:

### INTESTINAL WALL:

#### MUCOSA:

##### FLICA CIRCULARIS (FOLD):

##### VILLI:

##### LAMINA PROPRIA:

##### MUSCULARIS MUCOSAE:

##### LYMPHOID FOLLICLE:

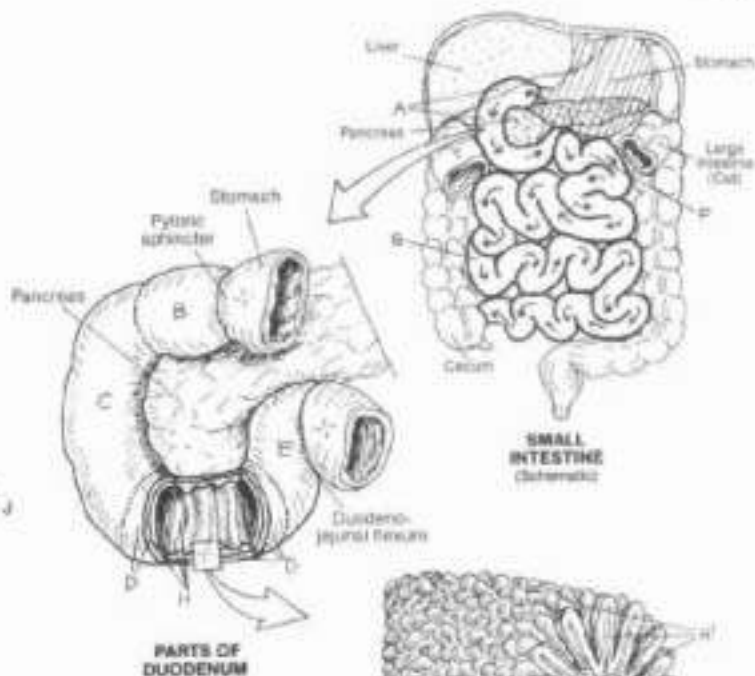
#### SUBMUCOSA:

#### MUSCULARIS EXTERNA:

##### CIRCULAR M.<sub>o</sub>M

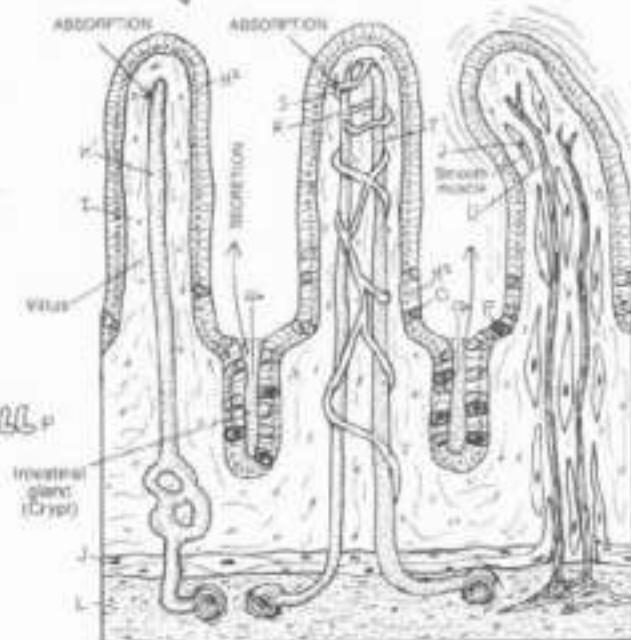
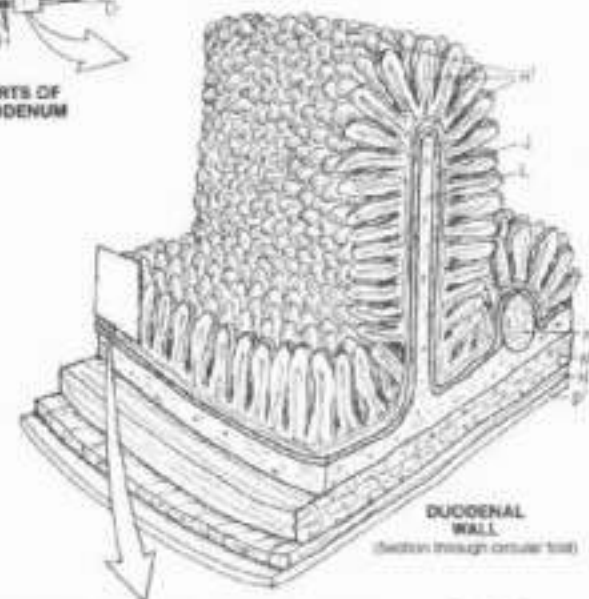
##### LONGITUDINAL M.<sub>o</sub>N

#### SEROSA:



Ch. Use green for K, red for R, purple for S, blue for T, yellow for U, and a very light color for H. (1) Begin with the three divisions of the small intestine. (2) Color the parts of the duodenum and the section of duodenal wall. The lamina propria (I) is identified and colored only in the enlarged view of the villi below.

The small intestine is a highly convoluted, thin-walled tube that undertakes much of the chemical and mechanical digestive process and almost the whole of the absorptive process of the entire gastrointestinal tract. The first part of the duodenum is suspended by the lesser omentum. The second and third parts are retroperitoneal. The fourth part emerges anteriorly to become embraced by the common mesentery, pulled upward/suspended by a band of smooth muscle at the duodenojejunal junction. The jejunum is highly coiled, suspended by the common mesentery between the peritoneal layers through which travel its blood and nerve supply and draining veins. The thinner but longer ileum is also suspended by the common mesentery. It opens into the cecum of the large intestine. The mucosal surface of the jejunum (and to a lesser extent the duodenum and ileum) is characterized by circular folds (plicae circulares). Myriads of conical, finger-shaped villi (leaf-shaped in the duodenum) project from the surface of the jejunum; these diminish in number in the ileum. Among the epithelia lining the villi are hormone-secreting enteroendocrine cells (see glossary). The loose, vascular, fibrous lamina propria support the villi and its contents, including lymphatic capillaries (lacteals) and muscle fibers from the muscularis mucosae. Lymphoid follicles exist in both lamina propria and submucosa; they increase in number in the ileum where they form aggregates (Peyer's patches). At the base of the villi are tubular intestinal glands, the ducts of which open into the intervillous spaces. The submucosa of the small intestine is fibrous and vascular, and contains ganglia of autonomic motor neurons, the axons of which supply the muscularis externa. In the duodenum only, mucus-secreting glands occupy the submucosa.



- ABSORPTIVE CELL +
- MUCOUS CELL
- ENTEROENDOCRINE CELL +
- GLANDULAR DUCT +
- ARTERY
- CAPILLARY
- VEIN +
- NERVE
- LACTEAL +

VILLI AND INTESTINAL GLANDS  
(Structures common to all villi are shown separately)



# X. DIGESTIVE SYSTEM

## LARGE INTESTINE

On: By using the same colors for the parts of the intestinal wall you used on the preceding plate, you can demonstrate the similarity between the structures of the two intestines. The epithelium/mucosa glands (N) should receive the same color as the villi (Y) of Plate 104, and the serosa in both plates should receive the same color. Use a very light color for S (1) (Begin with the section above).

### LARGE INTESTINE:

- CECUM A
- ILEOCECAL VALVE B
- VERMIFORM APPENDIX C
- ASCENDING COLON D
- TRANSVERSE COLON E
- DESCENDING COLON F
- SIGMOID PELVIC COLON G
- RECTUM H
- ANAL CANAL I
- INTERNAL SPHINCTER ANI J
- EXTERNAL SPHINCTER ANI K

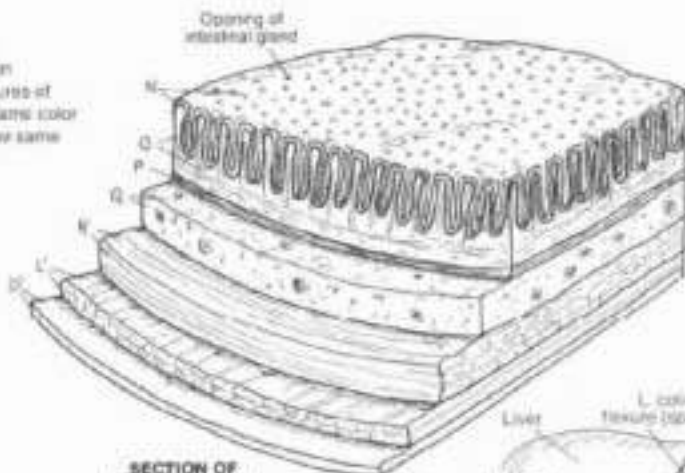
- TAENIA COLI L
- APPENDICES EPIPLOICA M

### INTESTINAL WALL:

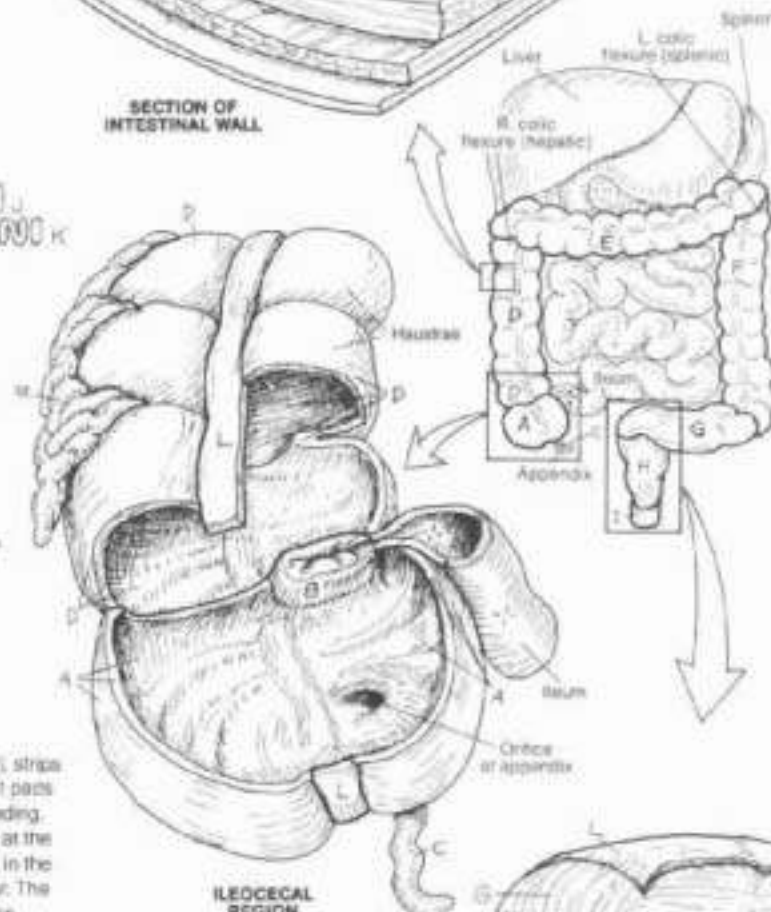
- MUCOSA:
  - EPITHELIUM/MUCUS GLANDS N
  - LAMINA PROPRIA O
  - MUSCULARIS MUCOSAE P
- SUBMUCOSA Q
- MUSCULARIS EXTERNA:
  - CIRCULAR M. R
  - LONGITUDINAL M. S
- SEROSA T

The large intestine is characterized by large sacculations (haustra), strips of longitudinal muscle in the muscularis externa (taenia coli), and fat pads (appendices epiploica) attached to the serosal surface of the ascending, transverse, and descending colon (only). The large intestine begins at the ileocecal valve with the cecum, usually suspended by a mesentery, in the right lower abdominal quadrant. The function of the valve is not clear. The vermiform appendix varies in length (2-20 cm); it may be anterior, posterior, or inferior to the cecum. The ascending and descending colons are retroperitoneal, the transverse colon is suspended by a mesentery (transverse mesocolon). Note the colic flexure and their relationships. At the pelvic inlet (not shown), the colon turns medially, gains a mesentery (sigmoid mesocolon), and is named the sigmoid colon. Variable in its extent and shape, it becomes the rectum at the level of the S3 vertebra. Here the haustra, the appendices epiploica, and the taenia are no longer seen. About 12 cm long, the rectum has a dilated lower part (ampulla). Feces entering the rectum stimulate the desire for defecation; thus, the rectum is not a long-term storage site. As the rectum narrows inferiorly, it becomes the anal canal surrounded by sphincter muscles.

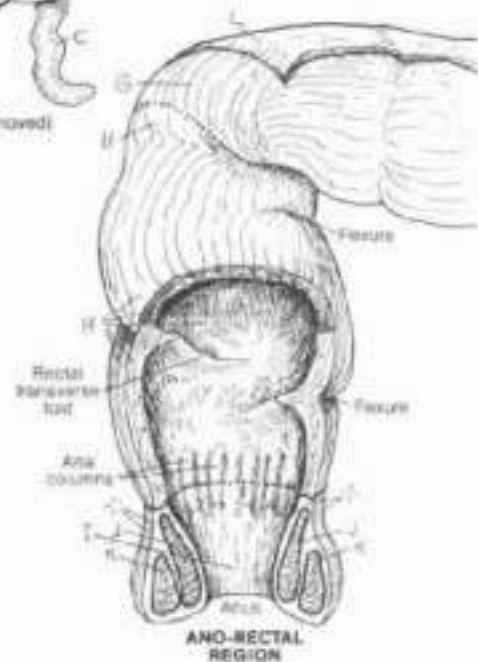
The intestinal wall of the large intestine is characteristic: mucosal surface without villi or plicae, underlying vascular submucosa, and two-layered muscularis externa lined with peritoneal serosa. The epithelial lining is simple columnar except in the anal canal where it becomes stratified squamous. The glands are tubular and mucus-secreting. Lymphoid follicles are seen in the lamina propria. At the anorectal junction, about 2 cm above the anus, a remarkably large number of veins can be seen in the lamina propria (not shown). Varicose dilations of these veins (rectal or hemorrhoidal plexus) are called hemorrhoids. The large intestine functions in absorption of water, vitamins, and minerals, and the secretion of mucus.



SECTION OF INTESTINAL WALL



ILEOCECAL REGION  
(Anterior portion of cecum removed)



ANO-RECTAL REGION

# K. DIGESTIVE SYSTEM

## LIVER

CH: Use blue for I, red for J, and yellow for K. Use very light colors for A, B, and L. (1) Color the two upper views simultaneously. (2) Color the group of lobules, and then the enlargement. Begin with the branches of the portal vein (F) at the bottom of the section. (3) Begin the overview of blood and bile with the arterial flow.

### LOBES:

**RIGHT LOBE A**

**LEFT LOBE B**

**QUADRATE LOBE C**

**CAUDATE LOBE D**

### LIGAMENTS:

**CORONARY L. E**

**TRIANGULAR L. F**

**LESSER OMENTUM G**

**FALCIFORM L. H**

### PORTA:

**PORTAL VEIN I**

**HEPATIC ARTERY J**

**BILE DUCT K**

### LIVER LOBULE:

#### TRIAD:

**BRANCH OF PORTAL V. I'**

**BRANCH OF HEPATIC A. J'**

**BILE DUCT K'**

#### SINUSOID:

**HEPATIC CELL L**

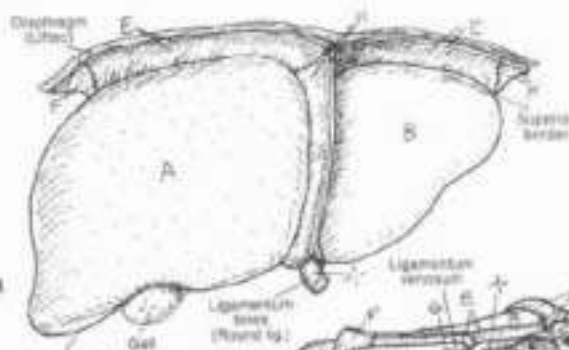
**CENTRAL VEIN I''**

**TRIBUTARY OF HEPATIC V. I'''**

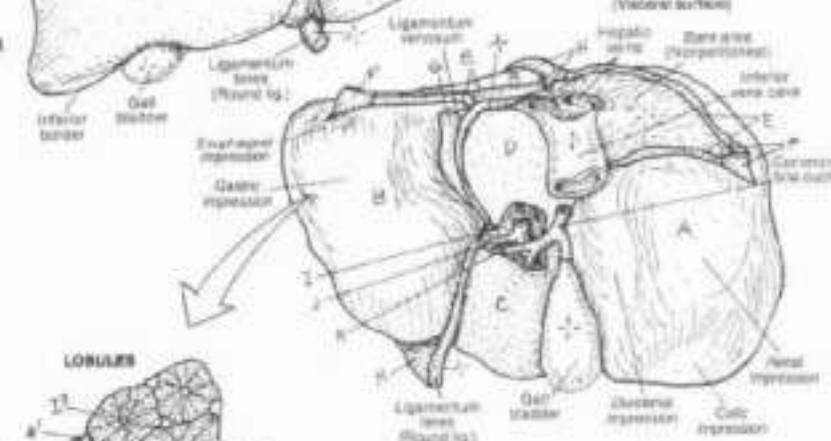
The liver is the largest gland in the body. Wedge-shaped (rounded upper border, the sharp inferior border) when seen from the side, the liver occupies the whole of the upper right quadrant of the abdominal cavity. Weighing about 1.5 kg in health, it can weigh over 10 kg when diseased (chronic cirrhosis). It is relatively huge in young children, hence the protuberance of the upper abdomen in such persons. The liver is enveloped in visceral peritoneum except for a part of the right posterior surface which is flush against the fascia covering the diaphragm (bare area). The visceral peritoneum around the bare area turns or reflects upward (coronary ligament) on to the diaphragm to become parietal peritoneum. The edges of the coronary ligaments are called the triangular ligaments. The two anterior leaves of the coronary ligaments join to become the falciform ligament; the two posterior leaves become the lesser omentum which encloses the porta of the liver. Here the hepatic portal vein and the hepatic artery approach the visceral surface of the liver and branch, and the common bile duct receives the common hepatic duct and cystic duct. The two-layered lesser omentum descends to support the pyloric end of the stomach and the first part of the duodenum. The falciform ligament is continuous with the parietal peritoneum of the anterior abdominal wall.

Connective tissue septa divide the liver cells/tissue (parenchyma) into irregular polyhedral lobules. Within each lobule, the cells form radially arranged cords; on two surfaces of these cords are sinusoids that converge onto a more or less central vein. At the corners of these lobules are the hepatic artery and portal vein branches, and bile ducts (called a triad). The portal vein branches feed into the sinusoids; the hepatic artery branches supply the cells; the bile ducts drain the bile ductules formed from tiny canaliculi (not shown) surrounding the cells. The liver cells discharge their products into the sinusoids (except bile), and absorb from these same sinusoids various nutrients and non-nutrients as well. Liver cells store and release proteins, carbohydrates, lipids, iron, and certain vitamins (A, D, E, K); they manufacture urea from amino acids, and bile from pigments and salts; they detoxify many harmful ingested substances. Bile is released from the cells into tributaries of bile ducts. The central veins are tributaries of larger veins which merge to form three hepatic veins at the posterior, superior aspect of the liver. These veins join the inferior vena cava just inferior to the diaphragm.

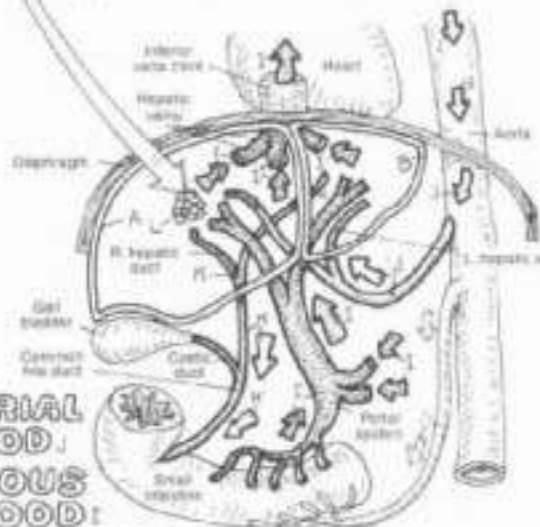
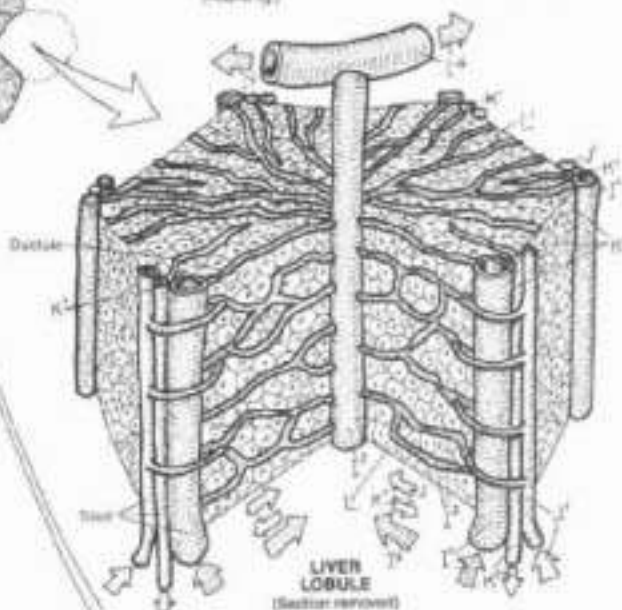
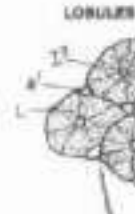ANTERIOR VIEW



POSTERIOR/INFERIOR VIEW (Visceral surface)



LOBULES



ARTERIAL BLOOD  
VENOUS BLOOD  
BILE FLOW

BLOOD AND BILE FLOW (Schematic)

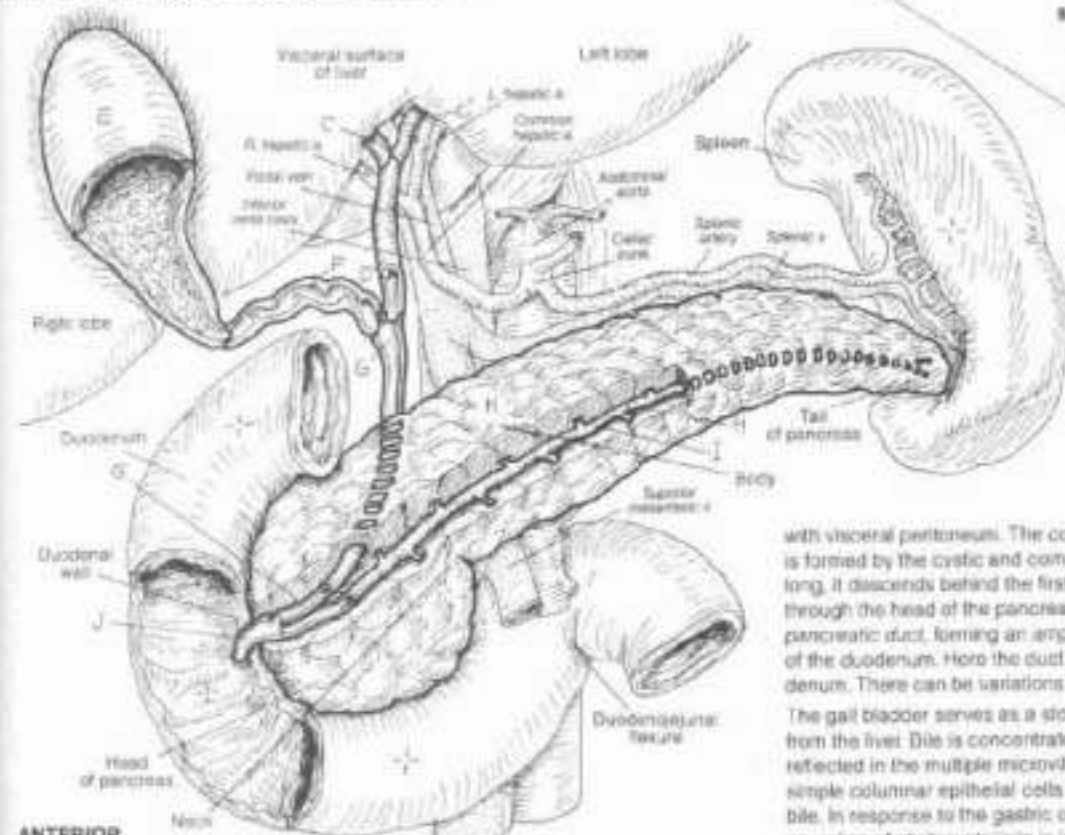
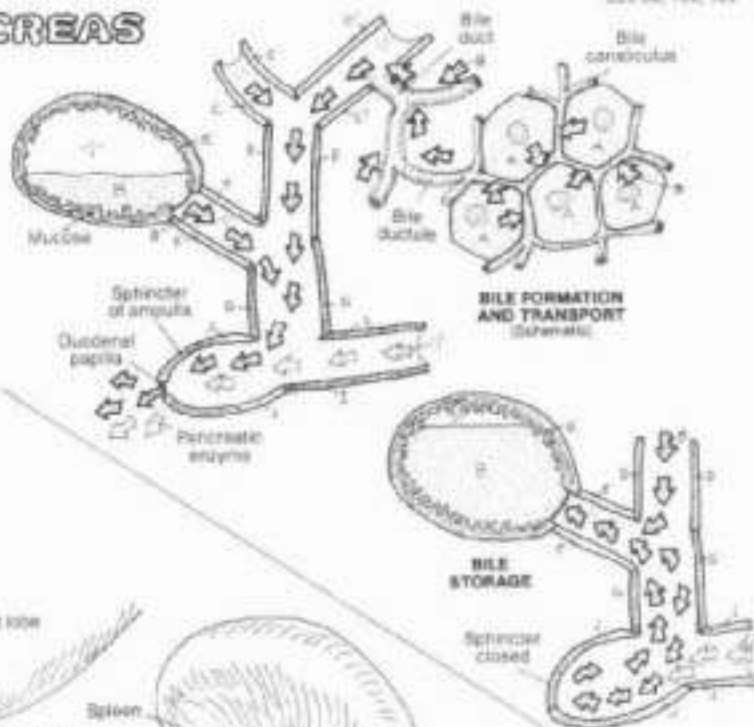

# X. DIGESTIVE SYSTEM

## BILIARY SYSTEM & PANCREAS

DN: Use the same colors as were used on the preceding plate for the hepatic cells and bile ducts, and a very light color for H. (1) Color simultaneously the diagram of bile formation/transport and the large central illustration. (2) Color the diagram describing bile storage.

- LIVER (HEPATIC CELL): BILE.
- R. & L. HEPATIC DUCT: COMMON HEPATIC DUCT.
- GALL BLADDER: CYSTIC DUCT.
- COMMON BILE DUCT.
- PANCREAS: PANCREATIC DUCT.
- DUODENAL AMPULLA.



**ANTERIOR VIEW**  
(Stomach removed)

The biliary system consists of an arrangement of ducts transporting bile from the liver cells that manufacture it in the gall bladder and to the second part of the duodenum. It is worth repeating: bile is formed in the liver (not the gall bladder). It is a fluid consisting largely of water (97%), and bile salts and pigments (from the breakdown products of hemoglobin in the spleen). Once formed, bile is discharged from liver cells into surrounding bile canaliculi. These small canals merge to form bile ductules that join the bile ducts which travel in company with the branches of the portal vein and hepatic artery. The bile is brought out of the liver by the right and left hepatic ducts which merge at the porta to form the common hepatic duct which descends between the layers of the lesser omentum and receives the 4 cm-long cystic duct from the gall bladder. The gall bladder is pressed against the visceral surface of the right lobe of the liver, covered

with visceral peritoneum. The common bile duct (or just bile duct) is formed by the cystic and common hepatic duct. About 8 cm long, it descends behind the first part of the duodenum, deep to or through the head of the pancreas. It usually joins with the main pancreatic duct, forming an ampulla in the wall of the second part of the duodenum. Here the duct opens into the lumen of the duodenum. There can be variations in the union of these two ducts. The gall bladder serves as a storage chamber for bile discharged from the liver. Bile is concentrated here several times, a fact reflected in the multiple microvilli on the luminal surface of the simple columnar epithelial cells that absorb water from the dilute bile. In response to the gastric or duodenal presence of fat, secretion of cholecystokinin is induced which stimulates the gall bladder to discharge its contents into the cystic duct. Peristaltic contractions of the duct musculature squirt bile into the duodenal lumen through the ampullary sphincter. Bile saponifies and emulsifies fats, making them water soluble and amenable to digestion by enzymes (lipases). The pancreas is a gland in the retroperitoneum, consisting of a head, neck, body, and tail. Most of the pancreas consists of exocrine glands that secrete enzymes into the pancreatic duct tributaries and on into the duodenum at a rate of about 2000 ml per 24 hour day. These enzymes are responsible for a major part of chemical digestion in the small intestine (lipases for fat, peptidases for protein, amylases for carbohydrates, and others). Pancreatic secretion is regulated by hormones (primarily cholecystokinin and secretin) from entero-endocrine cells and by the vagus nerves (acetylcholine). The endocrine portion of the pancreas is covered in Plate 129.



# XI. URINARY SYSTEM

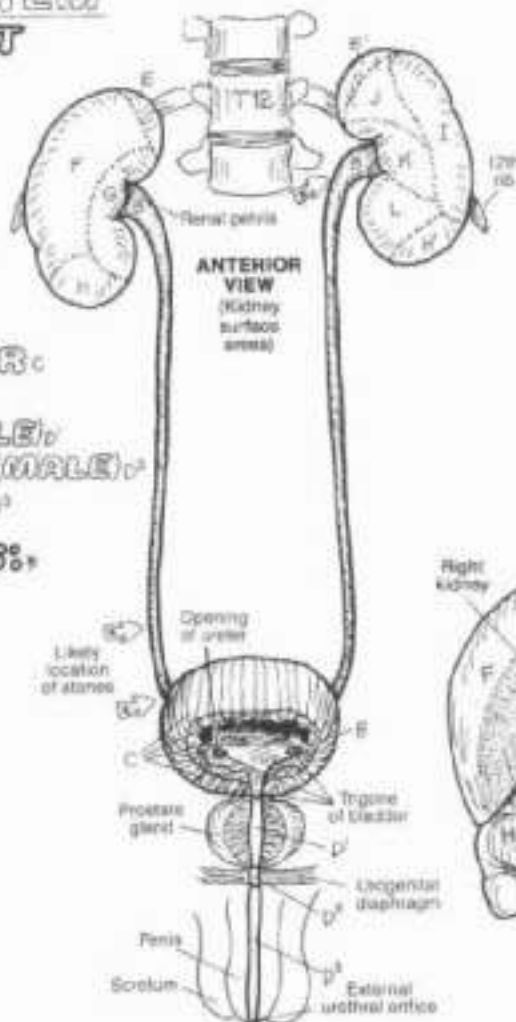
## URINARY TRACT

### URINARY TRACT:

- KIDNEY:**
- URETER:**
- URINARY BLADDER:**
- URETHRA:**
  - PROSTATIC U. (MALE):
  - MEMBRANOUS U. (MALE):
  - SPONGY U. (MALE):

### KIDNEY RELATIONS:

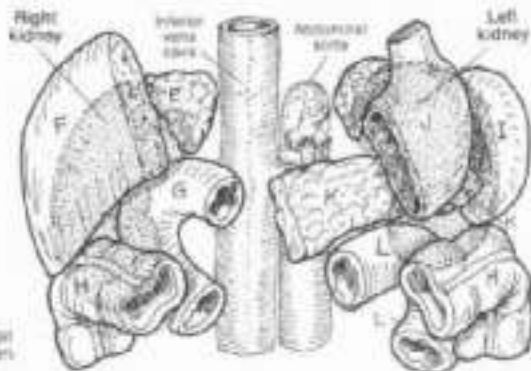
- SUPRARENAL GLAND:
- LIVER:
- DUODENUM:
- TRANSVERSE COLON:
- SPLEEN:
- STOMACH:
- PANCREAS:
- JEJUNUM:



Dir. Use very light colors for C and E-L.

(1) Color the three views of the urinary tract simultaneously. Note that the kidneys at the top of the page are to be colored according to areas which are in contact with other organs. Also note that the ureters penetrate the anterior wall of the urinary bladder, and that these openings receive a color. (2) Color the anterior relations of the kidneys which are shown as shaded silhouettes. Color gray the arrows marking sites of potential obstruction by "stones."

### ANTERIOR RELATIONS OF THE KIDNEYS



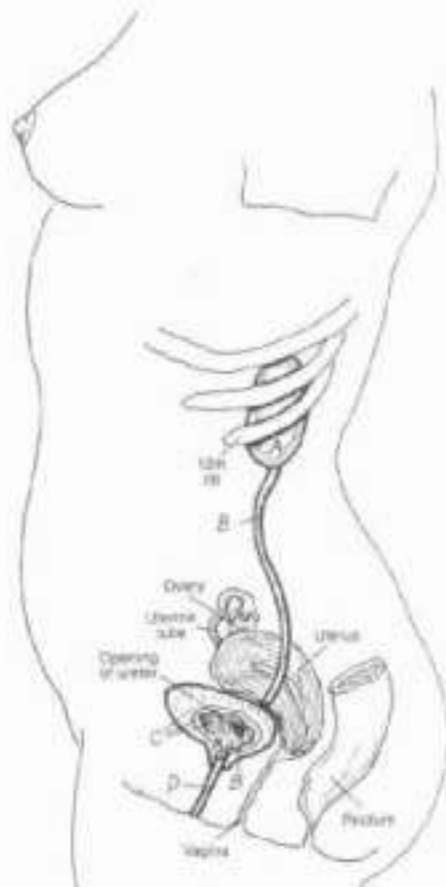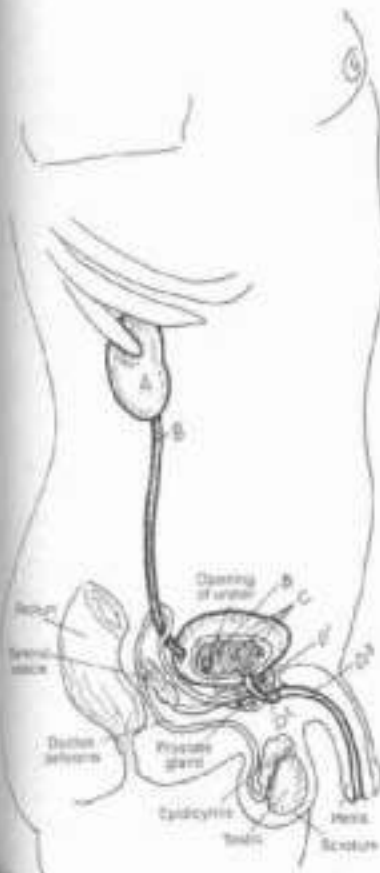The urinary tract consists of paired kidneys and ureters in the retroperitoneum, a single urinary bladder, and a urethra. The urinary tract represents a pathway for the elimination of metabolic by-products and toxic and other non-essential molecules all dissolved in a small volume of water (urine). The kidneys are not simply instruments of excretion; they function in the conservation of water and maintenance of acid-base balance in the blood. The process is a dynamic one, and what is excreted as waste in one second may be retained as precious in the next.

The ureters are fibromuscular tubes, lined by transitional epithelium. Three areas of the ureters are relatively narrow and are prone to being obstructed by mineralized concretions ("stones") from the kidney (see arrows).

The fibromuscular urinary bladder lies in the true pelvis, its superior surface covered with peritoneum. The mucosa is lined with transitional epithelium. The bladder can contain as little as 50 ml of urine and can hold as much as 700-1000 ml without injury, as it distends, it rises into the abdominal cavity and bulges posteriorly. The mucosal area between the two ureteral orifices and the urethral orifice is called the trigone.

The fibromuscular, glandular urethra, lined with transitional epithelium except near the skin, is larger in males (20 cm) than females (4 cm). Hence, urethritis is more common in men, cystitis is more common in women.

The urethra is described in three parts in the male (prostatic, membranous and spongy). The membranous urethra is vulnerable to rupture in the urogenital diaphragm with trauma to the low anterior pelvis.



# XI. URINARY SYSTEM KIDNEYS & RELATED RETROPERITONEAL STRUCTURES

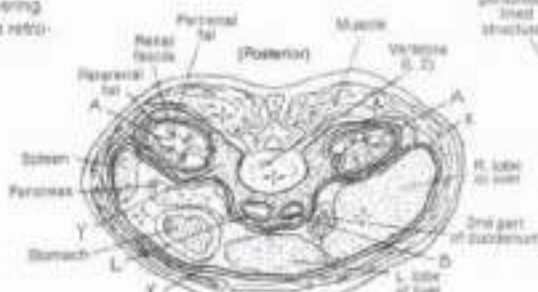
CH. Use red for R, blue for L, and a very light color for X (use a color, not gray). (1) Color the various structures in the abdominal cavity. Part of the peritoneum (X), whose site is among the upper diagrams, is shown covering much of the right side. (2) At the upper right, note the relationship of the retroperitoneum to the parietal peritoneum.

- KIDNEY,**  
**URETER,**  
**URINARY BLADDER** A'
- AORTA** •  
**& BRANCHES:**  
**CELIAC A. & BR.** • C  
**SUPRARENAL A.** •  
**SUP. MESENTERIC A.** • F  
**RENAL A.** • F  
**TESTICULAR A.** •  
**INF. MESENTERIC A.** • H  
**COMMON ILIAC A.** • I  
**INTERNAL ILIAC A.** • J  
**EXTERNAL ILIAC A.** • K
- INFERIOR VENA CAVA** •  
**& TRIBUTARIES:**  
**INTERNAL ILIAC V.** • M  
**EXTERNAL ILIAC V.** • N  
**COMMON ILIAC V.** •  
**TESTICULAR V.** • P  
**RENAL V.** •  
**SUPRARENAL V.** • R  
**HEPATIC VS.** •

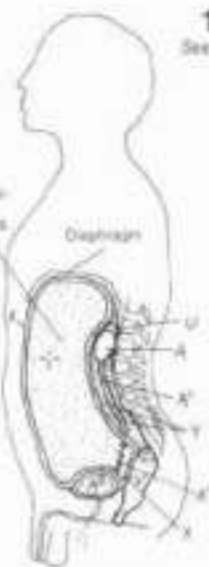- ORGANS & DUCTS:**  
**ESOPHAGUS** • T  
**SUPRARENAL GLAND** • U  
**RECTUM** • V  
**DUCTUS (VAG) DEFERENS** • W

The paired kidneys and ureters lie posterior to the parietal peritoneum of the abdominal cavity; they are, therefore, in the retroperitoneum. During fetal development, some abdominal structures arise in the retroperitoneum (e.g., kidneys), and some become retroperitoneal as a result of movement of visceral organs (e.g., ascending/descending colon, pancreas). The abdominal aorta and its immediate branches and the inferior vena cava and its immediate tributaries are all retroperitoneal. Arteries and veins travel between layers of peritoneum to reach the organs they supply/drain. Lymph nodes, lumbar trunks, and the cisterna chyli (not shown) are all retroperitoneal. The ureters descend in the retroperitoneum and under the parietal peritoneum to reach the posterior and inferior aspect of the bladder. Pelvic viscera and vessels lie deep to the parietal peritoneum.

The kidneys are encapsulated in perirenal fat, secured by an outer, stronger layer (renal fascia). Each kidney and its fascia are packed in paranephric fat. These compartments do not communicate between left and right. Such a support system permits kidney movement during respiration but secures them against impact forces.

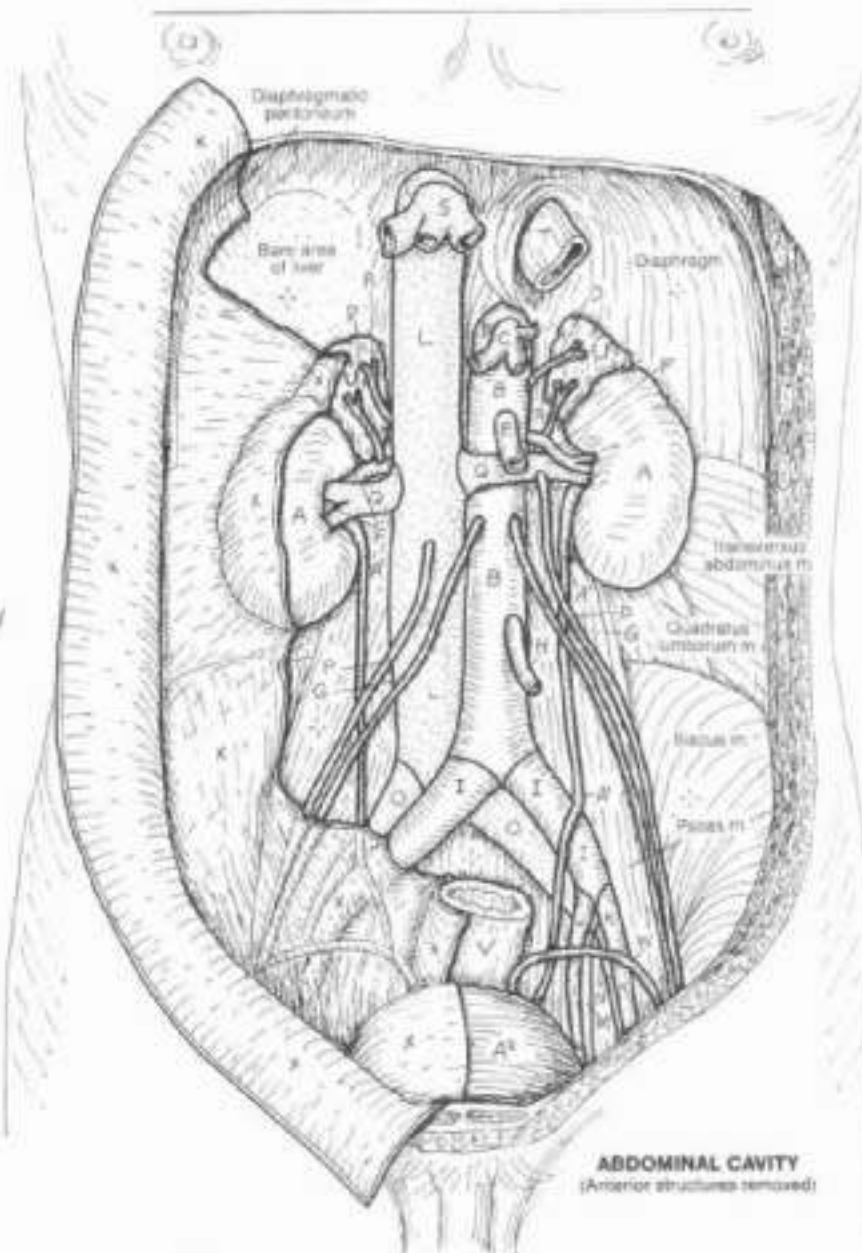


CROSS SECTION THROUGH ABDOMEN  
(Schematic, viewed from below)



SAGITTAL SECTION THROUGH TRUNK  
(Schematic)

## PARIETAL PERITONEUM, RETROPERITONEUM



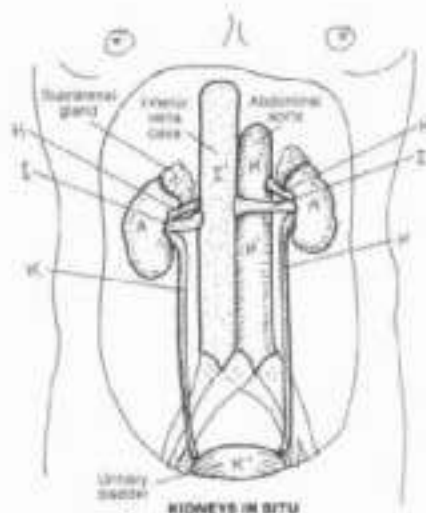
ABDOMINAL CAVITY  
(Anterior structures removed)



# XI. URINARY SYSTEM

## KIDNEY STRUCTURE

Ch. Use red for H, blue for I, yellow for K, and very light colors for B, E, F, G, and J. (1) Begin with the large illustration and note that the thickness of the renal capsule (A) has been greatly exaggerated for coloring purposes. Color the cut edges of blood vessels in the cortex (B). Also color the lines and arrows reflecting blood and urine flow. (2) Complete the overview diagram at the top of the plate.



### PERIPHERAL PART: \*

RENAL CAPSULE A

CORTEX B

MEDULLA (PYRAMID) C

PAPILLA D

### INNER CENTRAL PART: \*

MINOR CALYX E

MAJOR CALYX F

### HILUS: \*

RENAL PELVIS G

RENAL ARTERY H

OXYGENATED BLOOD H'

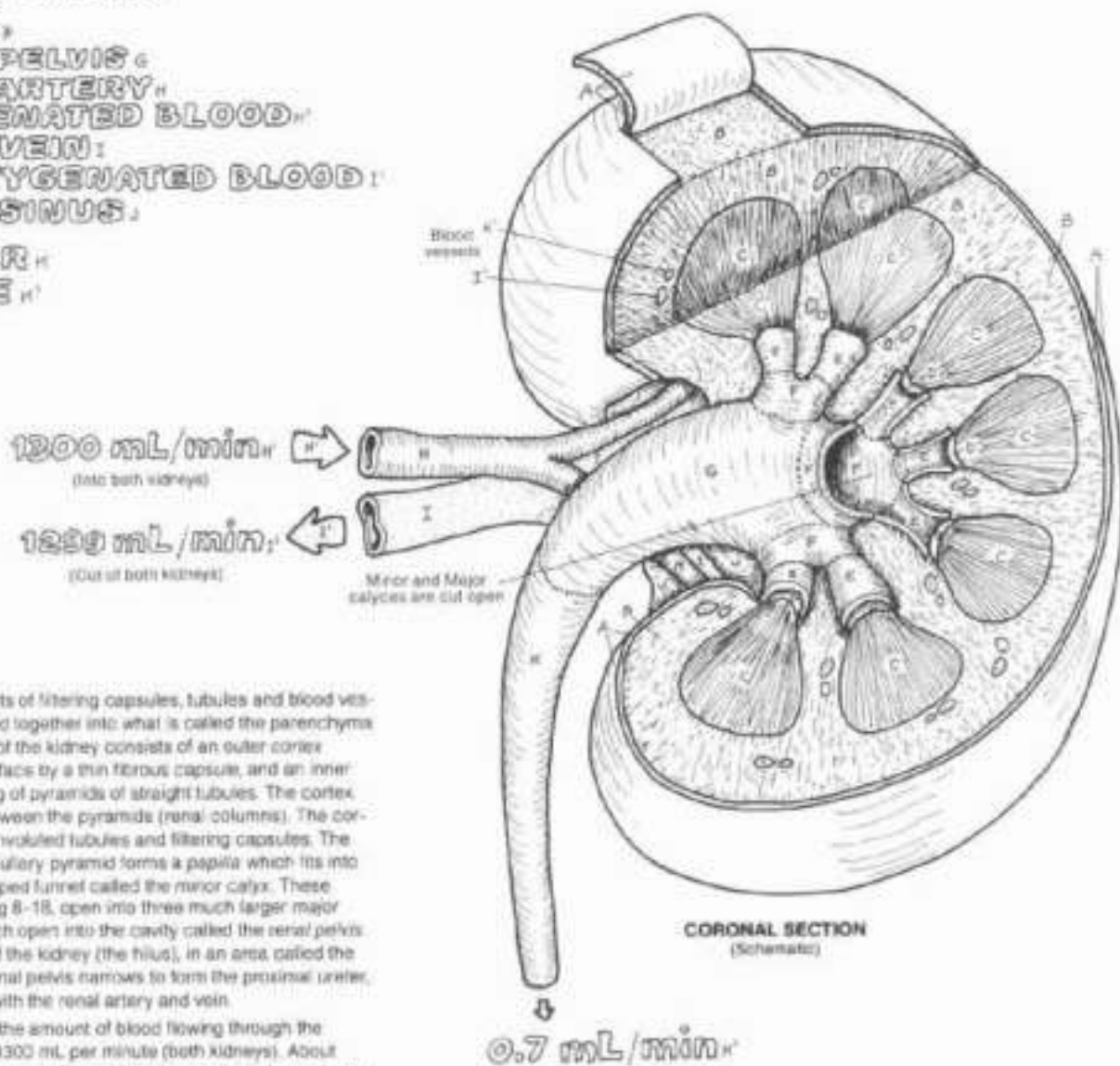
RENAL VEIN I

DEOXYGENATED BLOOD I'

RENAL SINUS J

URETER K

URINE K'



The kidney consists of filtering capsules, tubules and blood vessels tightly pressed together into what is called the parenchyma. The parenchyma of the kidney consists of an outer cortex covered on its surface by a thin fibrous capsule, and an inner medulla consisting of pyramids of straight tubules. The cortex reaches down between the pyramids (renal columns). The cortex consists of convoluted tubules and filtering capsules. The apex of each medullary pyramid forms a papilla which fits into the small cup-shaped funnel called the minor calyx. These funnels, numbering 8-18, open into three much larger major calyces all of which open into the cavity called the renal pelvis in the concavity of the kidney (the hilus), in an area called the renal sinus. The renal pelvis narrows to form the proximal ureter, sharing the area with the renal artery and vein.

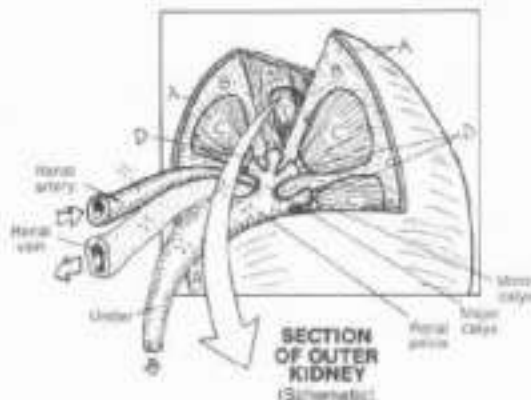
Renal blood flow (the amount of blood flowing through the kidneys) is about 1300 mL per minute (both kidneys). About 125-130 mL of plasma is filtered into the renal tubular systems each minute. Less than 1% of that filtered plasma (about 0.7 mL) is actually excreted as urine. Clearly, the kidney is in the water conservation business!



# XI. URINARY SYSTEM

## URINIFEROUS TUBULE

IN: Use red for E, yellow for K, and the same colors used on the preceding page A-D.  
 (1) Complete the drawing above. (2) In the enlarged wedge-shaped section, one uriniferous tubule is shown; actually, thousands are packed in each such section. Color all directional arrows the color of the adjacent vessel. (3) In the diagram below, color the capsule space gray but not the arrows representing filtrate.



### KIDNEY SECTION:

- CAPSULE.
- CORTIX.
- MEDULLA.
- PAPILLA.

### NEPHRON:

#### RENAL CORPUSCLE:

- GLOMERULUS.
- GLOMERULAR (BOWMAN'S) CAPSULE:
  - PARIETAL LAYER.
  - VISCERAL LAYER (PODOCYTES).
  - CAPSULAR SPACE.

#### PROXIMAL TUBULE:

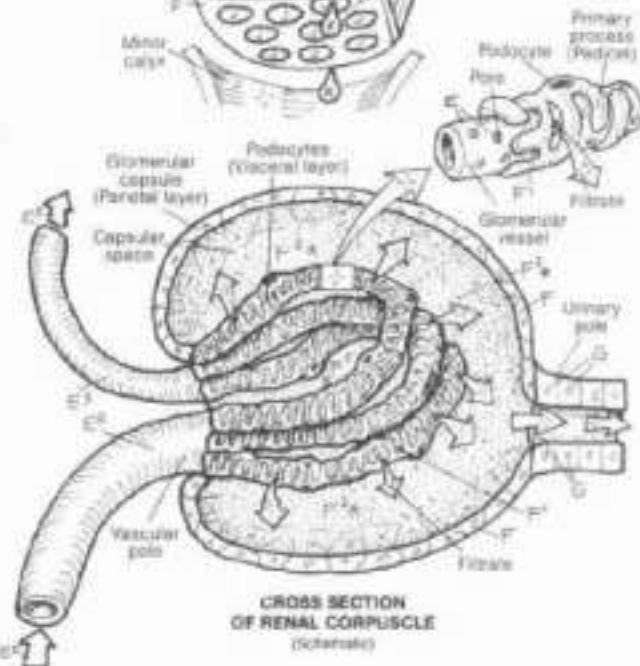
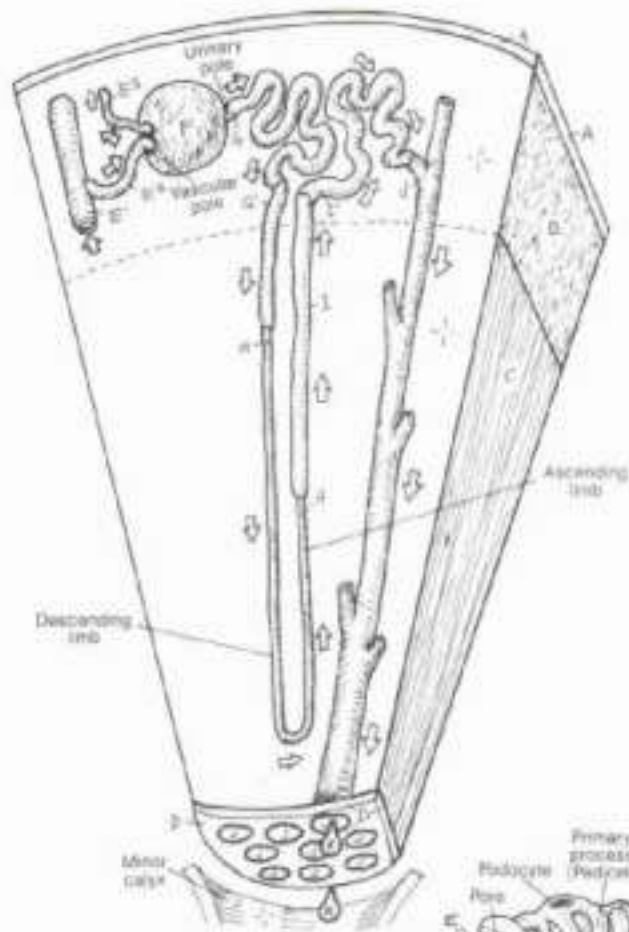
- CONVOLUTED PART.
- STRAIGHT PART.

#### LOOP OF HENLE:

- DISTAL TUBULE:
  - STRAIGHT PART.
  - CONVOLUTED PART.
- COLLECTING TUBULE.
- URINE.

#### BLOOD VESSELS:

- INTERLOBULAR ARTERY.
- AFFERENT ARTERIOLE.
- EFFERENT ARTERIOLE.



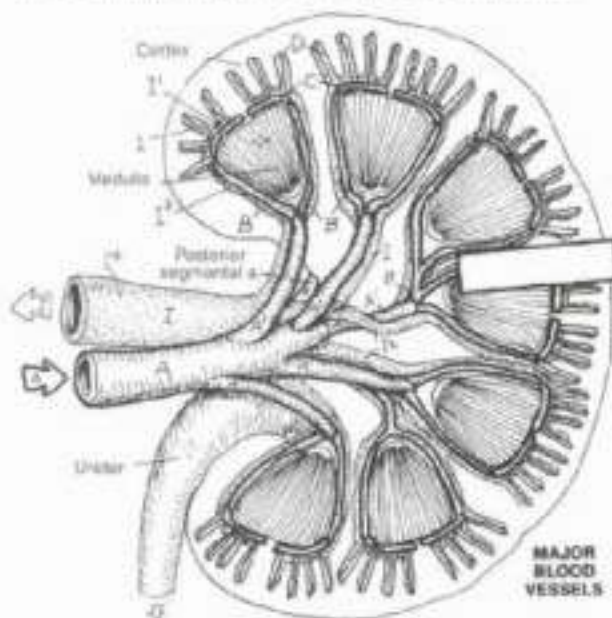
The functional unit of the kidney is the nephron (one million per kidney). Each nephron and a collecting tubule constitute a uriniferous (renal) tubule; each nephron consists of a renal corpuscle and tubules leading to a collecting tubule. The renal corpuscles are in the cortex; the tubules are in both the cortex and the medulla. Each corpuscle consists of a glomerular capsule innervated by a cluster of specialized capillary-like vessels (glomerulus). The vessel leading into each glomerulus is an afferent arteriole, a downstream, fifth-order branch of the renal artery; its entrance into the capsule is the vascular pole. The efferent arteriole departs the vascular pole, its blood destined for the tubular capillary plexus (next plate).

The capsule is shaped like a soft, rubber, partly flat hollow ball pushed in on one side so that it has an outer and an inner layer to it. The inner layer (of cells) is called the visceral layer; the outer layer the parietal layer; the interior is the capsular space which opens into the proximal tubule (urinary pole). The visceral layer is intricately and complexly interwoven with the glomerular vessels. Each cell in the layer has the shape of a centipede, with a "body" containing the nucleus, and multiple "legs" (cell membrane-lined cytoplasmic extensions called primary processes). These processes incompletely encircle the glomerular vessels, leaving slits (interdigitations) among the processes. The "legs" have "feet" (called foot or secondary processes) which attach to the porous vessel wall in such a way as to leave filtration spaces among them. These highly modified, simple squamous epithelial cells of the visceral layer are called podocytes. Plasma escapes the glomerular vessel through the pores, then rushes through the filtration slits to enter the capsular space. This non-cellular plasma filtrate enters the proximal tubule.

We continue with the structure and function of the parts of the uriniferous tubule, in conjunction with the vascular system, in the next plate.

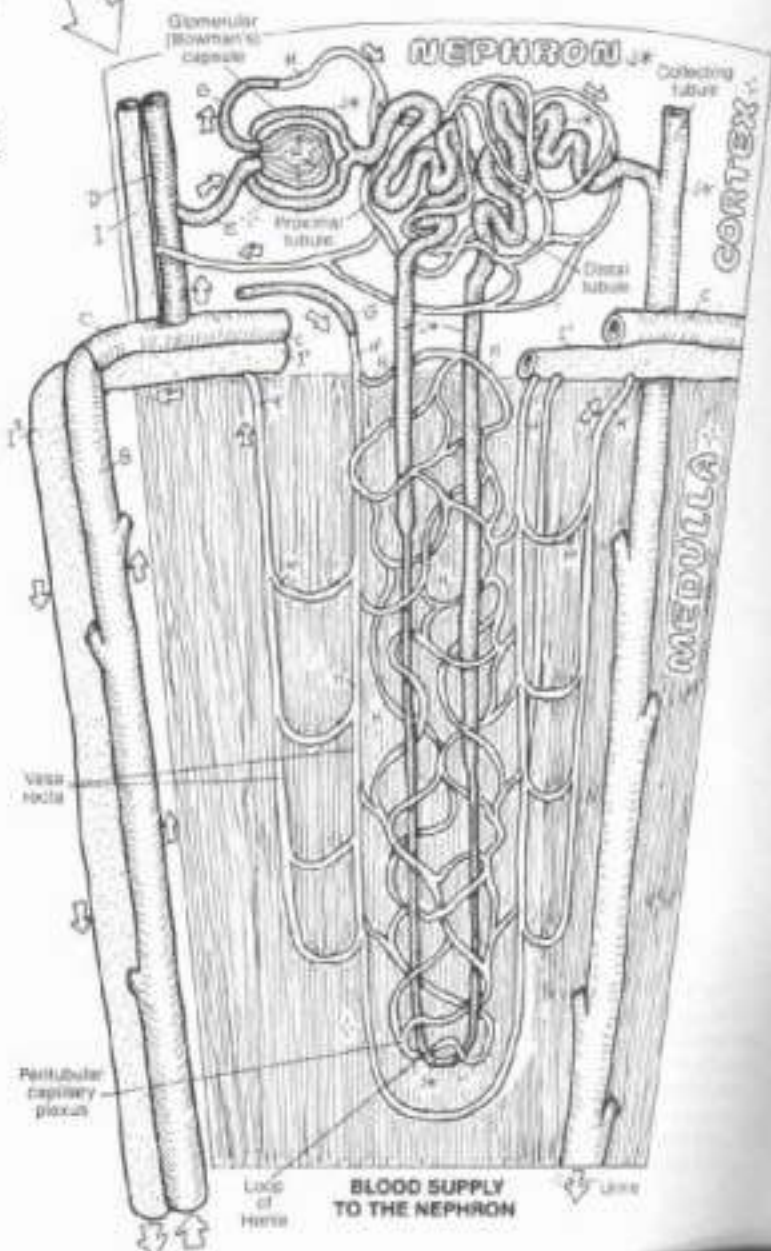
# XI. URINARY SYSTEM RENAL CIRCULATION

DN. Use red for A and blue for V, and a very light color for F. (1) Color the major blood vessels (A-C), noting that the corresponding veins receive only one color (blue). (2) Color the nephrons in the larger illustration gray. Note that the glomerular capsules have been opened to reveal the glomeruli (F). All arrows receive the color of the adjacent vessels.



RENAL A.: A  
SEGMENTAL A.: A  
INTERLOBAR A.: B  
ARCUATE A.: C  
INTERLOBULAR A.: D  
AFFERENT ARTERIOLE: E  
GLOMERULUS: F  
EFFERENT ARTERIOLE: G  
PERITUBULAR CAPIL. PLEXUS: H  
VASA RECTA: I

INTERLOBULAR V.: J  
ARCUATE V.: K  
INTERLOBAR V.: L  
SEGMENTAL V.: M  
RENAL V.: N



The nephron consists of the renal corpuscle and tubules less collecting tubules. The renal corpuscle was considered in Plate 111. Refer to that plate as necessary for the following paragraph. The proximal tubule close to the capsule of origin is highly convoluted. The pyramidal-shaped cuboidal cells of this tubule absorb 85% of the vitamins, amino acids, small proteins, glucose, sodium chloride, and water that came in with the plasma filtrate. The straight part of the tubule descends to become the loop of Henle; the cells of which absorb large amounts of water. The cells of the distal tubule are relatively impermeable to water but not to minerals. Here the filtrate tends to become diluted. The reabsorption of sodium (Na<sup>+</sup>) is facilitated by aldosterone from the adrenal cortex and by dietary restriction of salt. The cells of the collecting tubule are permeable to water (taking it out of the tubule) in the presence of antidiuretic hormone (ADH, vasopressin). It is significantly less permeable in the absence of ADH, and even less so in the presence of diuretic medication.

The renal vascular pattern explains how the tubular cells can recover large amounts of fluid/solute from the filtrate and secrete it into the peritubular capillary plexus, to the extent that only 1% of the plasma filtered by the glomerular capsule reaches the capillaries at any one moment. Follow the route of blood from the renal artery to and through the glomeruli to the efferent arterioles. The efferent arteriole in the upper and middle cortex branches into a peritubular capillary plexus that is intertwined around the convoluted tubules. The plexus is drained by interlobular veins which conduct the blood toward the renal vein. In nephrons close to the medulla (juxtamedullary nephrons), the efferent arteriole (shown without its glomerulus of origin) may give off straight vessels (vasa recta) that "descend" into the medulla adjacent to the straight tubules. These vessels contribute to a separate peritubular capillary plexus in the medulla. Medullary vessels leaving the peritubular capillary plexuses form or contribute to "ascending" vasa recta which generally terminate by joining the arcuate veins. The relationship of the vasa recta to the loops of Henle is a critical factor in the success of water reabsorption. The circulatory pattern among the uniferous tubules is a vital feature in the preservation of body water and the maintenance of chemical neutrality throughout the body.



## XII. REPRODUCTIVE SYSTEM

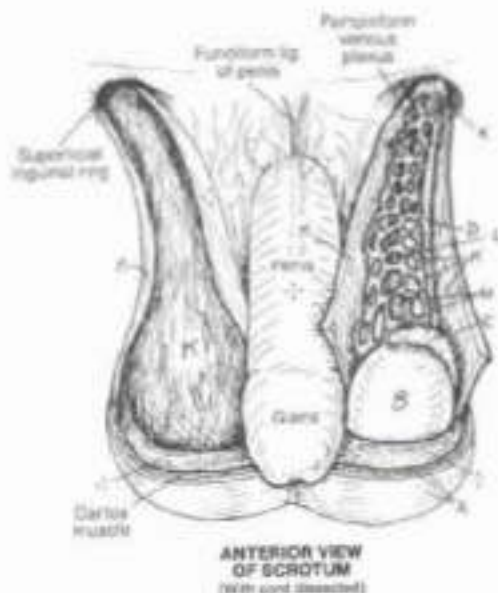
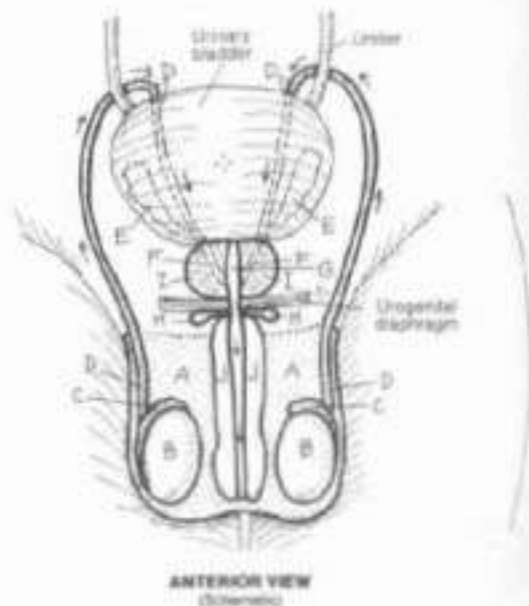
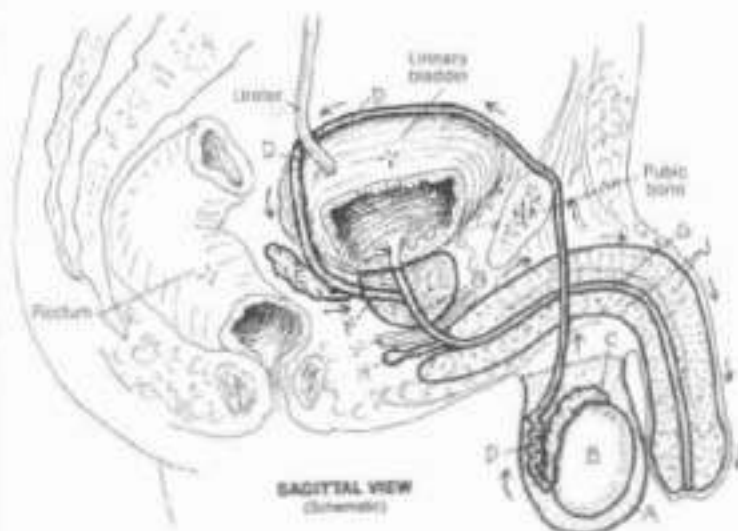
### MALE REPRODUCTIVE SYSTEM

**CR:** Use red for L, blue for M, and very light colors for A, J and K.  
 (1) Color the upper views simultaneously in the sagittal view, or by the urethra is shown in the median plane. (2) The coverings of the spermatic cord in the illustration below actually consist of several layers (see Plate 43). Color the parts of K and L, seen deep to the gubernaculum testis (3).

**SCROTUM.**  
**TESTIS.**  
**EPIDIDYMS.**  
**DUCTUS DEFERENS.**  
**SEMINAL VESICLE.**  
**EJACULATORY DUCT.**  
**URETHRA.**  
**BULBOURETHRAL GLAND.**  
**PROSTATE GLAND.**  
**PENIS.**

The male reproductive system consists of the primary organs, the testes (testes), suspended within a sac of skin and thin fibromuscular tissue (the scrotum), a series of ducts, and a number of glands. Development of the male germinal cells (sperm) in the testes requires a slightly lower-than-body temperature (about 35° C or 95° F); this is achieved by their separation from the warmer body cavities. The temperature within the scrotum can be adjusted slightly by the contraction/relaxation of smooth muscle (dartos muscle) in the scrotal wall, tightening or loosening the tension of the wall about the testes. Mature sperm are stored in the epididymis; with stimulus, sperm cells are induced to move into and through the ductus (vas) deferens by rhythmic contractions of the smooth muscle in the ductal wall. Within the ductus network, the sperm pass through the abdominal wall (via the inguinal canal) and pelvic cavity to enter the prostatic urethra via the pencil-point shaped ejaculatory duct. Here the nutrient-rich secretions of the prostate gland and seminal vesicles are added to the population of sperm in the prostatic urethra, forming semen. Prior to the release of the semen (ejaculation), the bulbourethral glands add secretions to the urethra. The penis and scrotum constitute the external genital organs.

Enlargement of the prostate is common (prostatic hypertrophy/hyperplasia) in men 50 years and older. The glands and connective tissues surrounding the urethra are subject to thickening and blocking urine flow (benign prostatic hypertrophy). Neoplastic growth (prostatic carcinoma) is less common (3-15% of men with prostatic hypertrophy) and occurs in the more peripheral tissues of the prostate.



**SPERMATIC CORD:**  
**COVERINGS.**  
**CONSTITUENTS:**  
**DUCTUS DEFERENS.**  
**TESTICULAR ARTERY.**  
**TESTICULAR VEIN.**

The testicular artery and vein, and some nerves and lymphatics, join the ductus deferens just before entering the deep ring (infra-abdominal orifice) of the inguinal canal. The collection of these form the constituents of the spermatic cord. Passing through the inguinal canal, they become invested by a representative layer from each of the abdominal wall layers (less rectus); these are the coverings of the spermatic cord and testes (here represented as one layer, see Plate 43). In a vasectomy procedure, the ductus deferens is identified within the cord and it alone is divided. A number of techniques (ligatures, cauterization, folding and burial, and so on) exist to prevent the natural tendency of the transected duct sections to recanalize.



## XII. REPRODUCTIVE SYSTEM

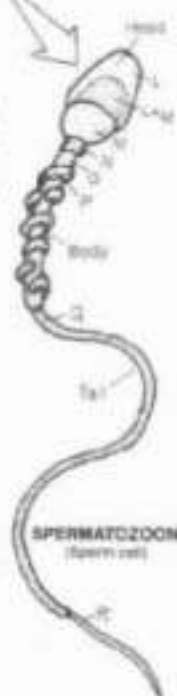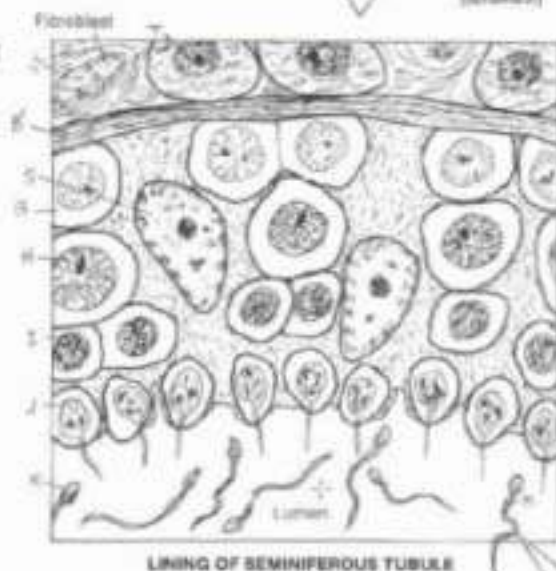
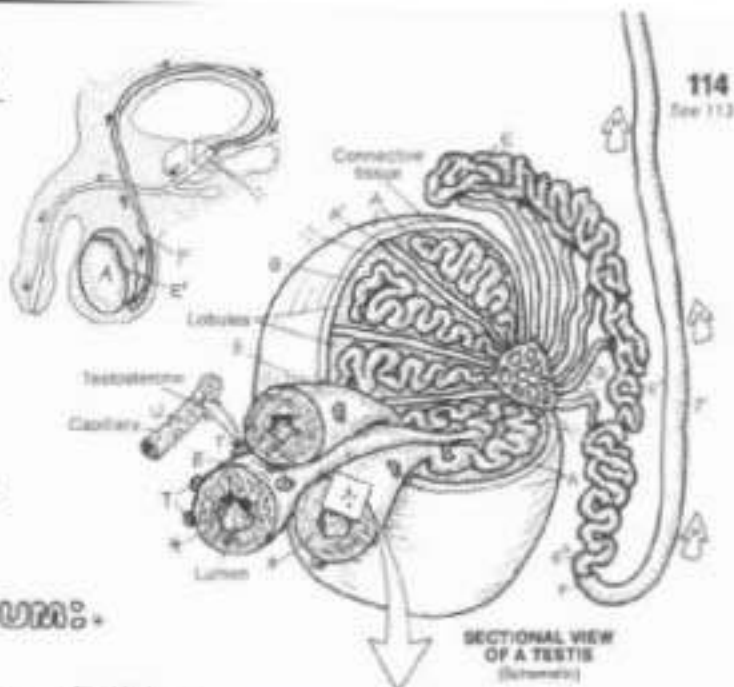
### TESTIS

Ch. Use the colors provided for the testis, epididymis, and ductus deferens on the previous plate with those same structures here (A, E, and F). Use red for U, and light colors for G, H, I, S, and T. (Note that the spermatogenic epithelium is colored gray in the cross section through the tubules above and that the tubular lumen is not to be colored.)

**TUNICA ALBUGINEA**  
**SEPTUM**  
**SEMINIFEROUS TUBULE**  
**RETE TESTIS**  
**EFFERENT DUCT**  
**EPIDIDYMIS HEAD**  
**BODY**  
**TAIL**  
**DUCTUS DEFERENS**

### SPERMATOGENIC EPITHELIUM:

**SPERMATOGONIUM**  
**PRIMARY SPERMATOCYTE**  
**SECONDARY SPERMATOCYTE**  
**SPERMATID**  
**SPERMATOZOOM**  
**HEAD:**  
**ACROSOME**  
**NUCLEUS**  
**TAIL:**  
**NECK**  
**MIDDLE PIECE**  
**MITOCHONDRION**  
**PRINCIPAL PIECE**  
**END PIECE**  
**SERTOLI SUPPORTING CELL**  
**BASEMENT MEMBRANE**  
**INTERSTITIAL CELL OF LEYDIG**  
**BLOOD VESSEL**



The testis (testicles) arise on the posterior abdominal wall during fetal development; as the developing body lengthens, they appear to "descend" into outpocketings of the anterior abdominal wall (scrotum). The testes have two principal functions: development of male germ cells (sperm or spermataza) and the secretion of testosterone, the male sex hormone.

Each testis has a dense, fibrous, outer capsule (tunica albuginea) from which septa are directed centrally to compartmentalize the testis into lobules. One to four tightly coiled seminiferous tubules exist in each lobule. These tubules converge toward the posterior side of the testis, straighten (tubuli recti), and join a network of epithelial-lined spaces (rete testis). Efferent ducts leave the rete to form the head of the epididymis. The convoluted epididymal duct (head-body-tail) is lined with pseudostratified columnar epithelium, one type of which contains long, immobile cilia (sterocilia). At the lower portion of the epididymis, the tubule turns upward to form the ductus deferens. The epididymis provides nutritional support for immature sperm cells and stores sperm. The wall of the ductus deferens, lined with pseudostratified columnar epithelium with stereocilia, contains significant smooth muscle, the rhythmic contractions of which drive sperm toward the prostate gland during emission.

Each seminiferous tubule consists of a lumen with walls of compact, organized masses of cells (spermatogenic epithelium and supporting (Sertoli) cells) encapsulated by a thin fibrous base-

ment membrane. The most immature of the sperm-developing cells are the spermatogonia. These divide and the daughter cells are pushed out toward the lumen of the tubule. These cells differentiate into primary spermatocytes, the largest of the developing germ cells. These divide to become secondary spermatocytes, at which time the chromosome number is reduced from 46 to 23 (meiosis). Each pair of newly formed secondary spermatocytes rapidly divides again to form four spermataza. These small cells mature by developing tails, condensing their nuclei and cytoplasm, and developing acrosomal caps (with enzymes) to break down the wall of the ovum and permit penetration. The mature sperm cell (spermatozoon) consists of a head of 23 chromosomes (nucleus) including the acrosome, a middle piece containing mitochondria to power cell movement, and the rest of the tail (fibers containing microtubules; the end piece is essentially a single flagellum) whose flagellations provide the cell's motive force. Mature sperm are driven out of the tubules through the tubular network into the highly convoluted epididymis.

The interstitial cells dispersed in the vascular loose connective tissue around the tubules include fibroblasts as well as the secretory cells (of Leydig), which are known to produce and secrete testosterone into adjacent capillaries. This male sex hormone stimulates the development of ducts and glands of the reproductive tract at puberty (generally between 11 and 14 years of age) as well as secondary sex characteristics.

## XII. REPRODUCTIVE SYSTEM

### MALE UROGENITAL STRUCTURES

DN: Use blue for I, red for J, yellow for K, and very light colors for D, E, and G. (1) Color the two upper views simultaneously, noting that the superficial and deep fascia (G, H) have been omitted from the coronal view. (2) Color the structural view and the cross section.

**URETHRA:**  
**PROSTATIC U.**  
**MEMBRANOUS U.**  
**SPONGY U.**

**PENIS:**  
**CORPUS CAVERNOSUM:**  
**CRUS OF PENIS:**  
**CORPUS SPONGIOSUM:**  
**BULB OF PENIS:**  
**GLANS PENIS:**

**PREPUCE (FORESKIN):**

**RELATED STRUCTURES:**

**SUPERFICIAL FASCIA:**

**DEEP FASCIA:**

**VEIN: ARTERY: NERVE:**

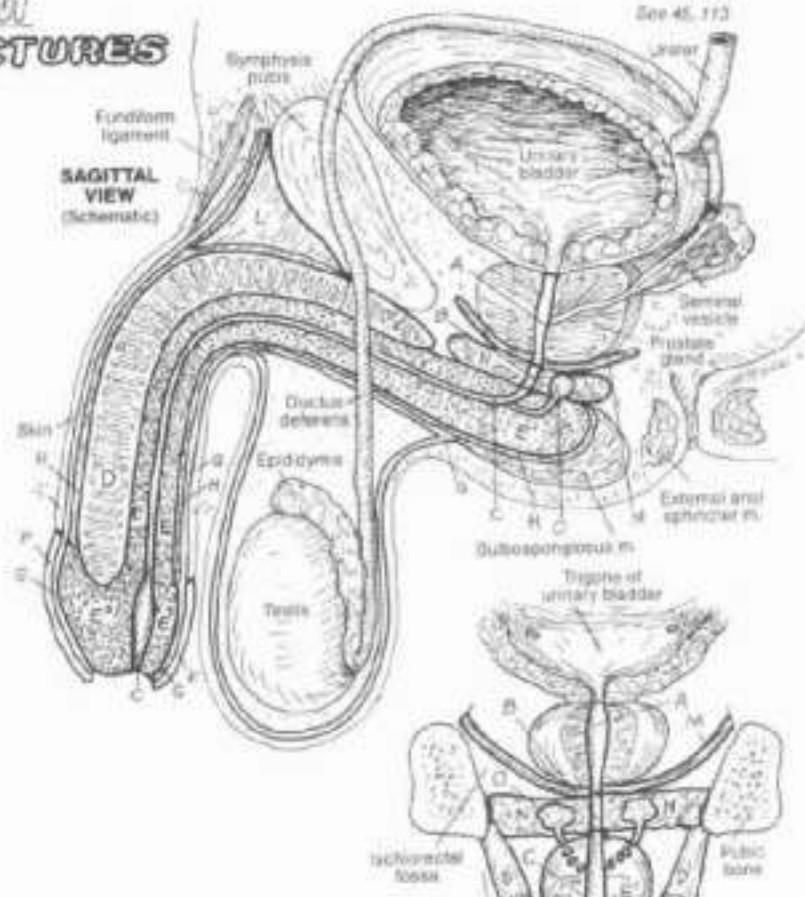
**SUSPENSORY LIG.:**

**LEVATOR ANI**

**(PELVIC DIAPHRAGM):**

**UROGENITAL DIAPHRAGM:**

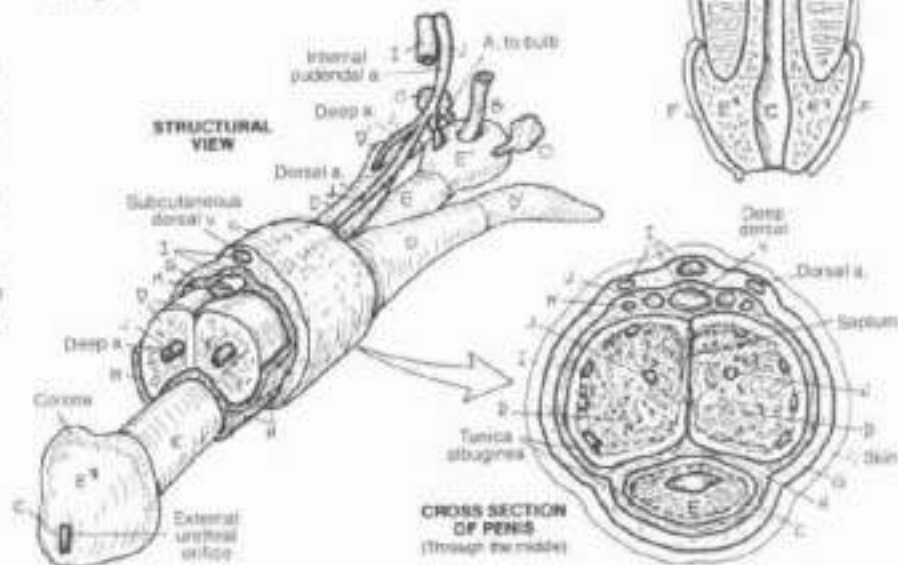
**BULBOURETHRAL GLAND:**



The urethra in the male has an extensive 20 cm (or so) course from the neck of the bladder to the external urethral orifice at the end of the penis. The prostatic urethra receives urine from the urinary bladder, sperm from the ejaculatory ducts, seminal fluid from the seminal vesicles, and secretions from the prostate via several ducts. Reflex contraction of the bladder neck muscles prevent voiding of urine during the expulsion of semen. The urethra continues through the pelvic diaphragm and into the thin, fibromuscular urogenital diaphragm as the membranous urethra. The spongy urethra passes through the penis. Numerous mucus glands exist in the urethral mucosa.

The penis consists of three bodies of erectile tissue, ensheathed in two layers of fasciae. The corpora cavernosa (the two lateral bodies) arise from the ascending rami of the pubic bones; the central corpus spongiosum arises as a bulb suspended from the inferior fascia of the urogenital diaphragm (perineal membrane). Each body consists of erectile tissue with a fibrous capsule (tunica albuginea); the corpus spongiosum contains the urethra as well. The three bodies are bound together in a dense stocking of deep perineal fascia and hang as a unit suspended by the deep suspensory and more superficial fundiform

ligaments. Deep to the skin of the penis is a layer of superficial fascia. The areolar tissue consists of lakes of veins (cavernous sinuses) bound by fibroelastic tissue and smooth muscle. These sinuses are fed by arteries in the erectile bodies. During sexual activity, these arteries dilate secondary to increased autonomic motor activity and the volume of blood entering the sinuses increases, expanding the areolar tissue. As a result, the veins at the periphery of the erectile bodies deep to the tunica albuginea are pressed against the capsule (unable to drain blood) and the penis enlarges and becomes rigid (erection). The glans remains non-rigid.

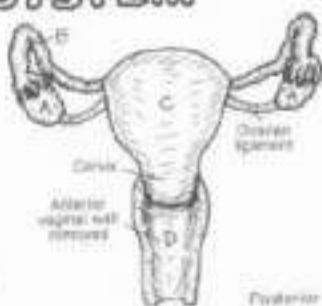




# XII. REPRODUCTIVE SYSTEM

## FEMALE REPRODUCTIVE SYSTEM

DN: (1) Color the two (upper) views of the internal reproductive structures simultaneously in the sagittal view; color the double line representing the peritoneum in gray. (2) In the lower drawings, color the vestibule (N) gray after coloring the other structures located in that area (L-P). (3) In the dissected view of the external structures, take note of the surrounding musculature, none of which is colored.

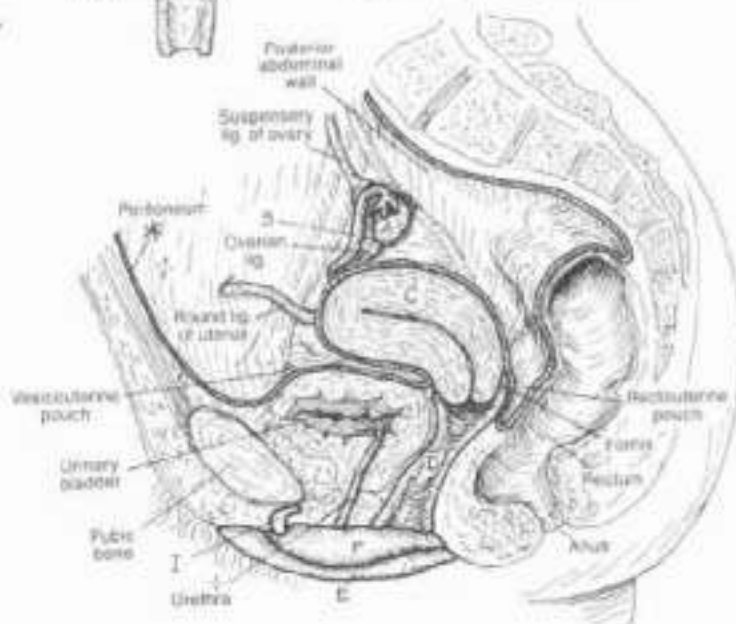


**MEDIAL VIEW**  
(Right side, genitourinary structures)

### INTERNAL STRUCTURES:

- OVARY
- UTERINE (FALLOPIAN) TUBE
- UTERUS
- VAGINA

The primary organ of the female reproductive system is the ovary which produces the female germ cells (ova) and secretes the hormones-estrogen and progesterone. Each ovary, like the testis, arises on the posterior abdominal wall (adjacent to the kidneys) during early fetal development. It also descends along that wall, like the testis, but is interrupted early in its journey by a ligament and is retained in the pelvis. The uterus serves as a site for implantation and nourishment of the embryo/fetus. The uterine tubes provide a conduit for the freshly fertilized or unfertilized ovum enroute to the uterus. The vagina, a fibromuscular sheath, receives the semen from the penis and transmits it to the uterus and acts as a birth canal from the uterus to the outside for the newborn.

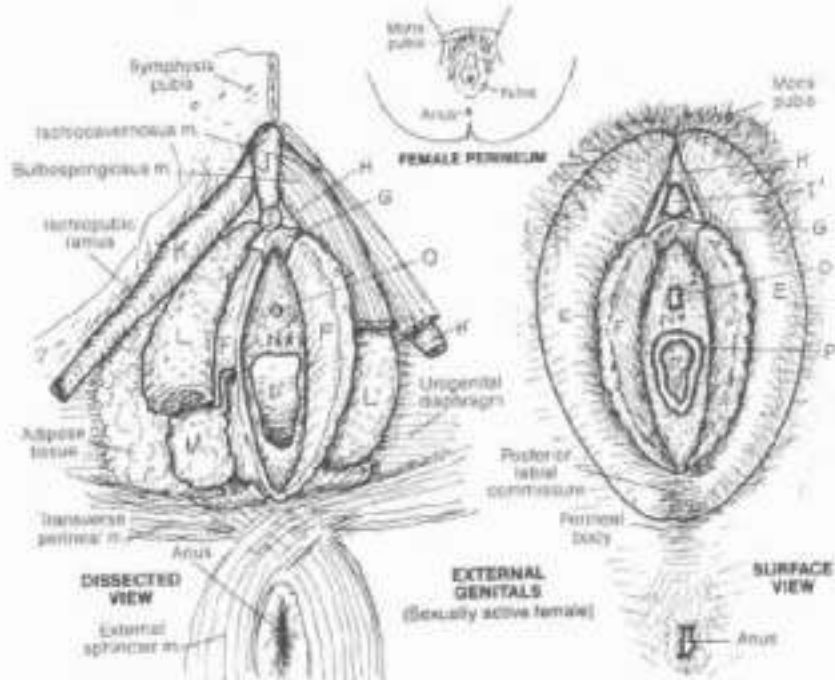


### EXTERNAL STRUCTURES:

- LABIUM MAJUS
- LABIUM MINUS
- FRENUM
- PREPUCE
- CLITORIS
- GLANS
- BODY
- CRUS

- BULB OF THE VESTIBULE
- VESTIBULAR GLAND/DUCT
- VESTIBULE
- URETHRAL ORIFICE
- VAGINAL ORIFICE/HYMEN

The female external genital collectively constitute the *vulva*. They are located within the perineum. The labia majora are fat-filled folds of skin largely obscuring the cavity/space between them (vestibule) that contains the urethral and vaginal orifices. Medial to the labia majora are the folds of skin (labia minora) which approach the clitoris anteriorly and split around it, forming the frenulum and prepuce of the clitoris. Like the penis, the clitoris has a crus (pl. crura) arising from each ischiopubic ramus; the two crura join in the midline to form the body or corpus. The body is capped by a skin-covered, vascular, sensitive glans. These clitoral components contain erectile tissue (less in the glans) enclosed in fascial coverings; their erection or rigidity is accomplished by the same mechanism operative in the penis. The clitoris, unlike the penis, does not incorporate the urethra. The vestibular bulbs are homologous to the bulb of the penis, but separated into two erectile bodies. They are covered by the bulbospongiosus muscle, and protrude into the vagina during sexual stimulation. The vaginal orifice is completely or incompletely covered or surrounded by a rim of mucosa called the hymen. Remnants of it (as shown) are often retained in the sexually active female.

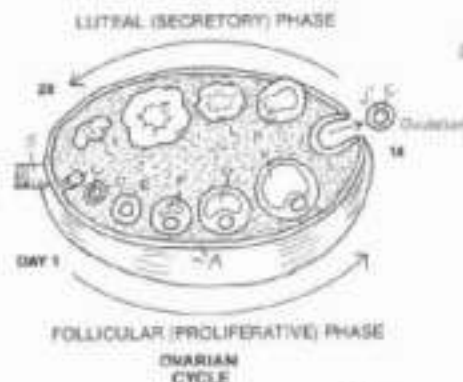




## XII. REPRODUCTIVE SYSTEM OVARY

117  
See 116

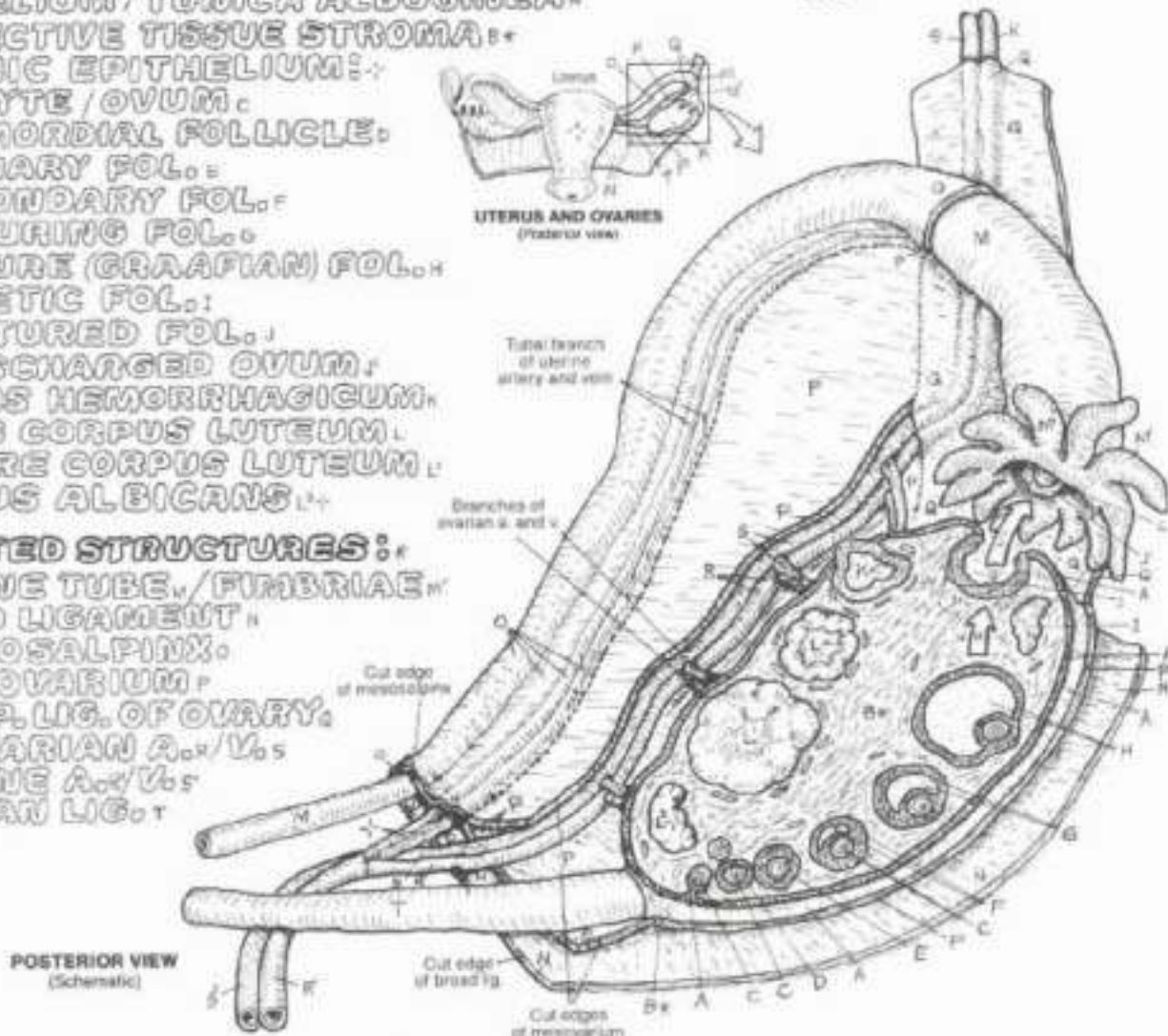
24. Use the colors from the preceding plate for the ovary (A) and uterine tube (M). Use red for K and F, yellow for L, blue for B, and very light colors for C, J, M, O and P. (1) Color the development of the female germ cell in both upper and lower views of the sectioned ovary. The oocyte (C) is colored through ovulation. In the large illustration, color the background stroma (B) gray; do not color the blood vessels in the stroma.



**OVARIAN STRUCTURES:**  
**EPITHELIUM / TUNICA ALBUGINEA:**  
**CONNECTIVE TISSUE STROMA:**  
**OGONIC EPITHELIUM:**  
**OOCYTE / OVUM:**  
**PRIMORDIAL FOLLICLE:**  
**PRIMARY FOL.**  
**SECONDARY FOL.**  
**MATURING FOL.**  
**MATURE (GRAAFIAN) FOL.**  
**ATRETIC FOL.**  
**RUPTURED FOL.**

**DISCHARGED OVUM:**  
**CORPUS HEMORRHAGICUM:**  
**YOUNG CORPUS LUTEUM:**  
**MATURE CORPUS LUTEUM:**  
**CORPUS ALBICANS:**

**RELATED STRUCTURES:**  
**UTERINE TUBE / FIMBRIAE:**  
**BROAD LIGAMENT:**  
**MESOSALPINX:**  
**MESOVARIUM:**  
**SUSP. LIG. OF OVARY:**  
**OVARIAN A. & V.:**  
**UTERINE A. & V.:**  
**OVARIAN LIG.:**



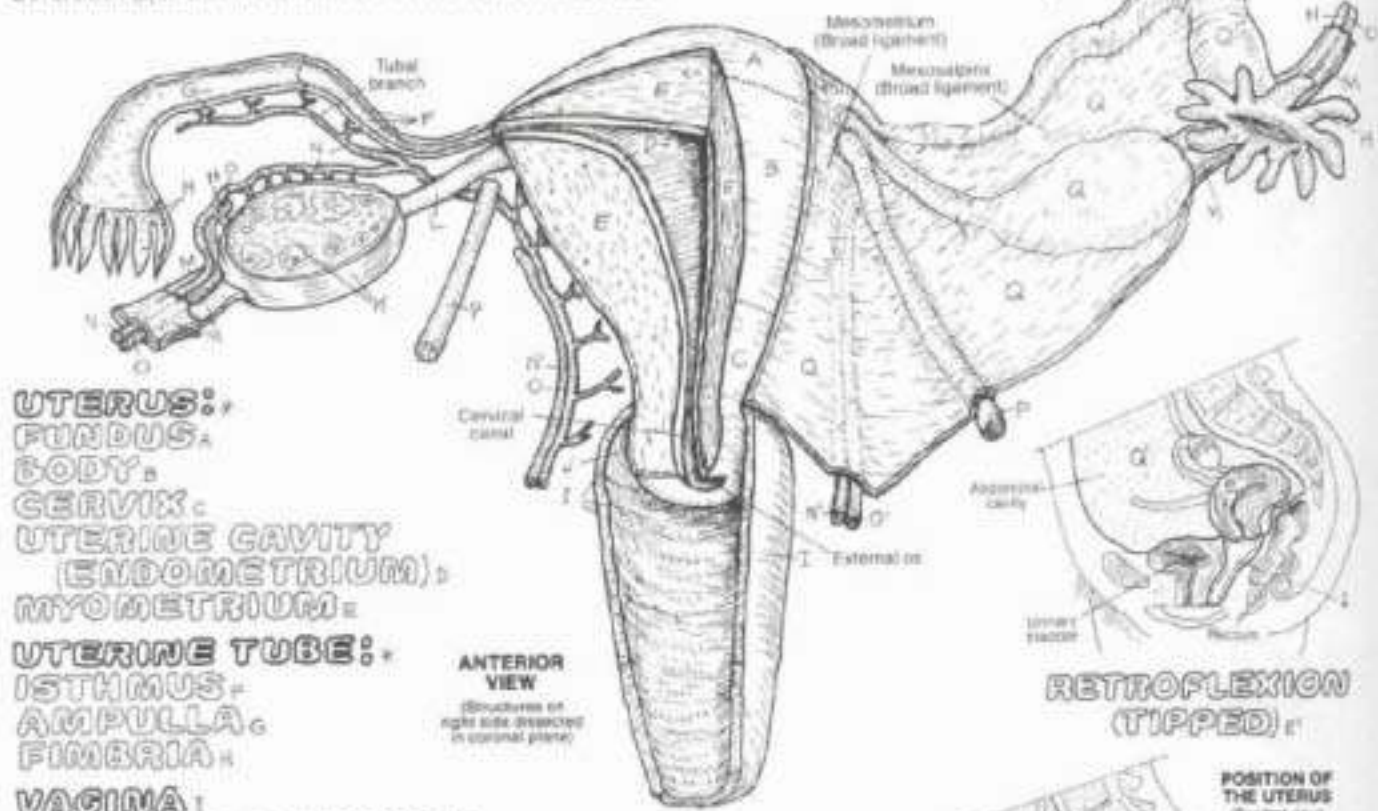
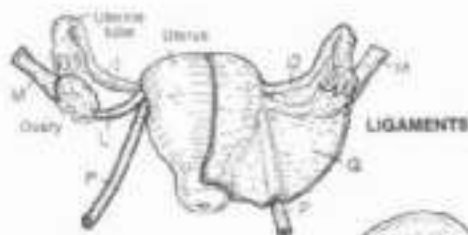
Development of female germ cells and the secretion of the hormones estrogen and progesterone are the functions of the ovary. Confined by the thin but dense fibrous tunica albuginea, lined with epithelium, many ovarian follicles in various stages of development can be seen in the connective tissue stroma. A follicle consists of an immature epithelial germ cell (oocyte) surrounded by one or more layers of non-germinating cells. These germ cells were seeded in the ovary early in development—over 400,000 of them. Of these, only 500 or so will mature, the rest slopping short in their development and degenerating with their follicular cells (atretic follicles). Development of an ovum starts with the primordial follicle—an oocyte with one layer of follicular cells. The oocyte increases in size and maturity as the follicle cells increase in number. In secondary follicles, a small space (antrum) filled with follicular fluid appears. This antrum continues to increase/expand at the expense of the follicle cells, which are pushed away from the oocyte

except for a layer of cells (mature follicle). Those cells in the outermost part of the follicle secrete estrogen during the proliferative phase of the reproductive cycle. On about the 14th day of that cycle, the ovum (surrounded by a glycoprotein coat, the zona pellucida, and some follicular cells) bursts from the follicle into the waiting fingers (fimbriae) of the uterine tube. The ruptured follicle involutes, and some bleeding and clotting goes on (corpus hemorrhagicum) as the follicle cells transition, characterized by accumulating large amounts of lipid. This newly formed structure (corpus luteum) secretes estrogen and progesterone during the secretory phase of the cycle, and in the event of pregnancy, will support the developing embryo/fetus for up to three months with these secretions. Should pregnancy not ensue, the corpus luteum will involute and degenerate as the corpus albicans. Follicles or corpora albicans/lutea collectively relating to two or three different but sequential cycles can be seen in the ovary at one time.

# XII. REPRODUCTIVE SYSTEM

## UTERUS, UTERINE TUBES, & VAGINA

Ch. Use red for A, blue for G, and light colors for D, E, and Q. (1) Begin with the left half of the large illustration. Only parts of the ovarian and uterine veins are shown. Nerves and lymph vessels that may accompany arteries and veins are not shown. (2) Color the two views of the ante- and the retroflexed uterus.



**UTERUS:**  
**FUNDUS:**  
**BODY:**  
**CERVIX:**  
**UTERINE CAVITY**  
**(ENDOMETRIUM):**  
**MYOMETRIUM:**

**UTERINE TUBE:**  
**ISTHMUS:**  
**AMPULLA:**  
**FIMBRIA:**

**VAGINA:**  
**FORNIX OF VAGINA:**

**RELATED STRUCTURES:**

**OVARY:**  
**OVARIAN LIG.:**  
**SUSPENSORY LIG. OF OVARY:**  
**OVARIAN ART. & VEIN:**  
**ROUND LIG. OF UTERUS:**  
**UTERINE ART. & VEIN:**  
**BROAD LIG. (PERITONEUM):**

**ANTERIOR VIEW**  
 (Structures on right side dissected in coronal plane)

**RETROFLEXION (TIPPED)**

**POSITION OF THE UTERUS (Sagittal view)**

**ANTEFLEXION (NORMAL)**

The ovaries, uterus, uterine tubes, and vagina make up the internal organs of reproduction in the female. The ovaries are suspended on the posterior layer of the broad ligament by a peritoneal extension (mesovarium), and supported by the suspensory ligament of the ovary (a lateral extension of the broad ligament and mesovarium), the ovarian ligament, and the round ligament (from the lateral wall of the uterus to the medial wall of the ovary). In this view the ovaries have been brought to the horizontal to better clarify their relationship to the uterine tubes. The uterine tubes, suspended in a part of the broad ligament (mesosalpinx), are lateral extensions of the uterus, lined with ciliated columnar epithelium supported by connective tissue and smooth muscle. The rhythmic contractions of this muscle aid the ovum in its trek from the fimbriae to the uterine cavity and the lining cells support it nutritionally. The tube shows three rather distinct parts: the distal fimbriae (finger-like projections) which "catch" the discharged ovum and whisk it into the tubular lumen; the ampulla or widest part of the tube; and the isthmus whose lumen narrows as it enters the uterine wall/cavity. The uterus is a pear-shaped structure whose neck (cervix) fits into the upper part of the vagina and whose body/fundus is bent (ante- and retroflexed) anteriorly over the bladder. Backward bending/tilting

(retroflexion/retroversion) of the uterus is not uncommon, particularly in women who have given birth. The retroflexed uterus predisposes to mild slipping into the vagina (prolapse) when the uterus is more in the axis of the cervix/vagina. Such an event is generally resisted by the pelvic and urogenital diaphragms, the perineal body and numerous fibrous ligaments (broad ligament, and condensations of the pelvic fasciae, not shown) mooring the uterus and its tubes to the pelvic wall and sacrum. The wall of the uterus is largely smooth muscle (myometrium) lined with a glandular surface layer of variable thickness (endometrium) that is extremely sensitive to the hormones estrogen/progesterone.

The vagina is an elastic, fibromuscular tube with a mucosal lining of stratified squamous epithelium. The anterior and posterior mucosal surfaces are normally in contact. The anterior vaginal wall incorporates the short (4 cm) urethra. Remarkably, the mucosa of the vagina lacks glands; secretory activity during sexual stimulation is derived from a transudate of plasma from the local capillaries and from glands of the cervix. The vaginal lining reveals few sensory receptors. Where the cervix fits into the vagina, a circular moat or trough is formed around it (fornix, fornices). The fibroelastic posterior fornix is capable of significant expansion during intercourse.







# XII. REPRODUCTIVE SYSTEM

## BREAST (MAMMARY GLAND)

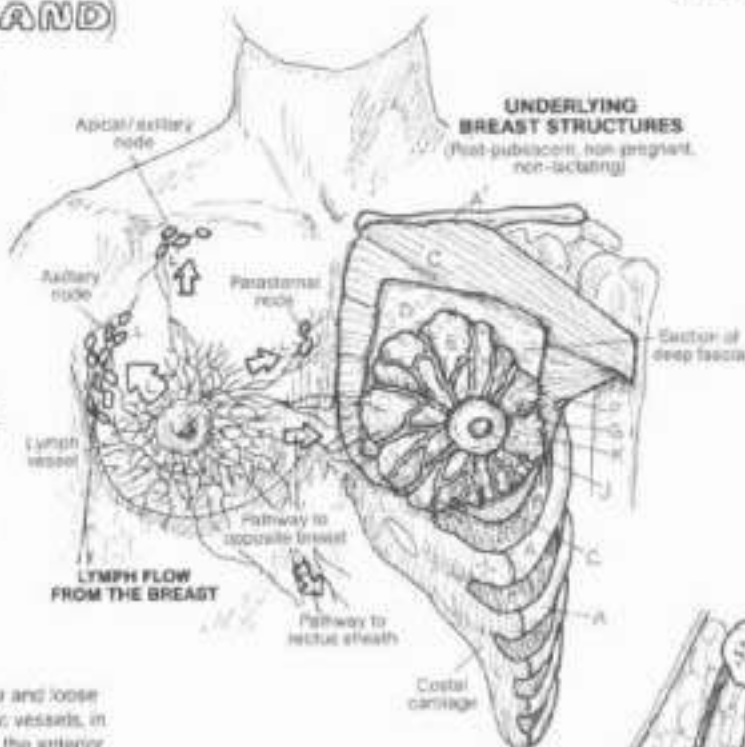
Ch: Use yellow for E, pinks, tans, or browns, for J and K, and light colors for A, D, E, and G. (1) Color the two illustrations of the breast and underlying breast structures, simultaneously. (2) Color the arrows indicating the direction of lymph flow, and the lymph nodes of the chest. If you wish, you may color over the network of lymph vessels. (3) Color the diagrams of breast development. (4) Color the enlargement of glands and ducts in the lower right corner.

RIB, CLAVICLE, INTERCOSTAL MUSCLE, PECTORALIS MAJOR M., DEEP FASCIA, SUPERFICIAL FASCIA (FAT), SUSPENSORY LIGAMENT, GLANDULAR LOBE, LACTIFEROUS DUCT, LACTIFEROUS SINUS, NIPPLE, AREOLA.

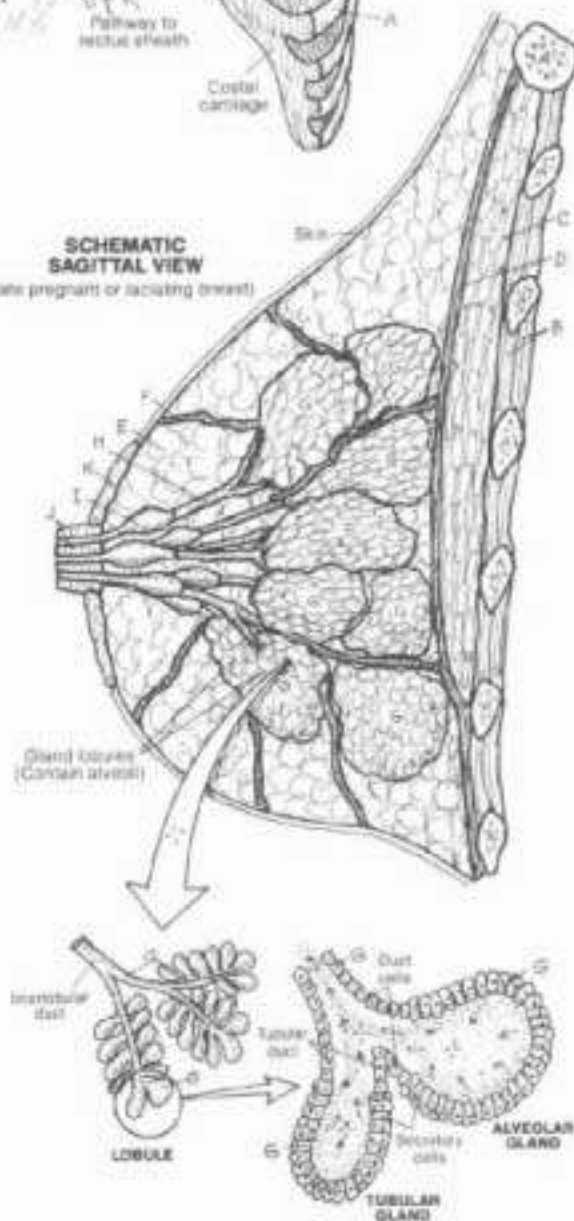
### LYMPHATIC DRAINAGE

The breast (in both males and females) is an area of fatty (adipose and loose areolar) fibrous tissue, and associated nerves, blood and lymphatic vessels, in the subcutaneous fascia overlying the pectoralis major muscle on the anterior chest wall. The fatty tissue is supported by extensions of the deep fascia overlying the muscle (suspensory ligaments) and functions most prominently in the young, well-developed, post-pubescent (after puberty) female breast. Packed within the adipose tissue is a collection of branching ducts (lactiferous ducts) in the male and in the non-pregnant (non-lactating) female, these ducts are undeveloped. There are few or no glands (alveoli) associated with these ducts in these populations. At puberty, the increased secretion of estrogen from the ovaries (and perhaps the adrenal glands) influences an enlargement of the nipple and areola in the female, and a generally marked increase in local fat proliferation. As a result, the breast enlarges to some degree (highly variable). In the early stages of pregnancy the lactiferous duct system undergoes profound proliferation, and small, inactive tubular and alveolar (tubuloalveolar) glands form, opening into alveolar ducts. A lobule consists of a number of these ducts and glands; a lobe (of which there are 15-20) consists of a number of lobules and an interconnecting interlobular duct. The interlobular ducts converge to form as many as 20 lactiferous ducts. These ducts dilate to form lactiferous sinuses just short of the nipple, and then narrow again within the nipple. These sinuses probably function as milk reservoirs during lactation. The nipple consists of pigmented skin with some smooth muscle fibers set in fibrous tissue. Erection of the nipple may enhance flow of milk through the ducts. The areolar areola, also pigmented more highly than the surrounding skin, contains sebaceous glands that may act as a skin lubricant during periods of nursing. In the latter stages of pregnancy, the alveolar glands undergo maturation and begin to form milk. Milk production peaks after delivery of the newborn, and is the result of the action of several hormones influencing the gland cells. The letdown and excretion of milk results from a neuroendocrine reflex mechanism that is initiated by the baby sucking the nipple.

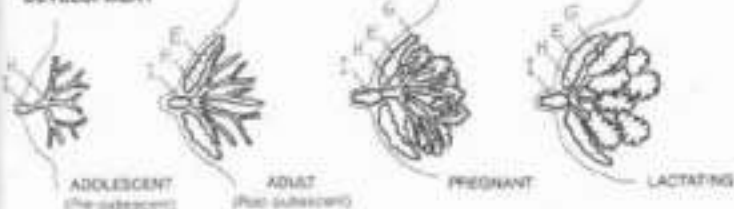
The lymphatic vessels are an important part of the breast; they drain the fat portion of the milk produced during lactation, and they transfer inhaled material or neoplastic (cancer) cells from the breast to more distant parts. The potential lymphatic avenues for metastasis or spread of infection are shown above.



SCHMATIC SAGITTAL VIEW (Late pregnant or lactating breast)



### BREAST DEVELOPMENT



## XII. REPRODUCTIVE SYSTEM EMBRYONIC DEVELOPMENT 1

CH. Use light colors throughout. (1) Follow the events from fertilization to implantation. The number of days cited in this and the following two plates are days after (post-) fertilization. Fertilization occurs about 14 days after the last day of menstruation. Physicians date fetal age by time since last menstrual period (LMP). Thus, fetal age according to LMP is 14 days earlier than true (post-fertilization) age.

### ZONA PELLUCIDA

### FERTILIZATION (1ST STAGE):

FEMALE PRONUCLEUS:

HEAD OF SPERM:

MALE PRONUCLEUS:

### BLASTOMERE

### (CLEAVAGE) STAGE:

2-CELL:

4-CELL:

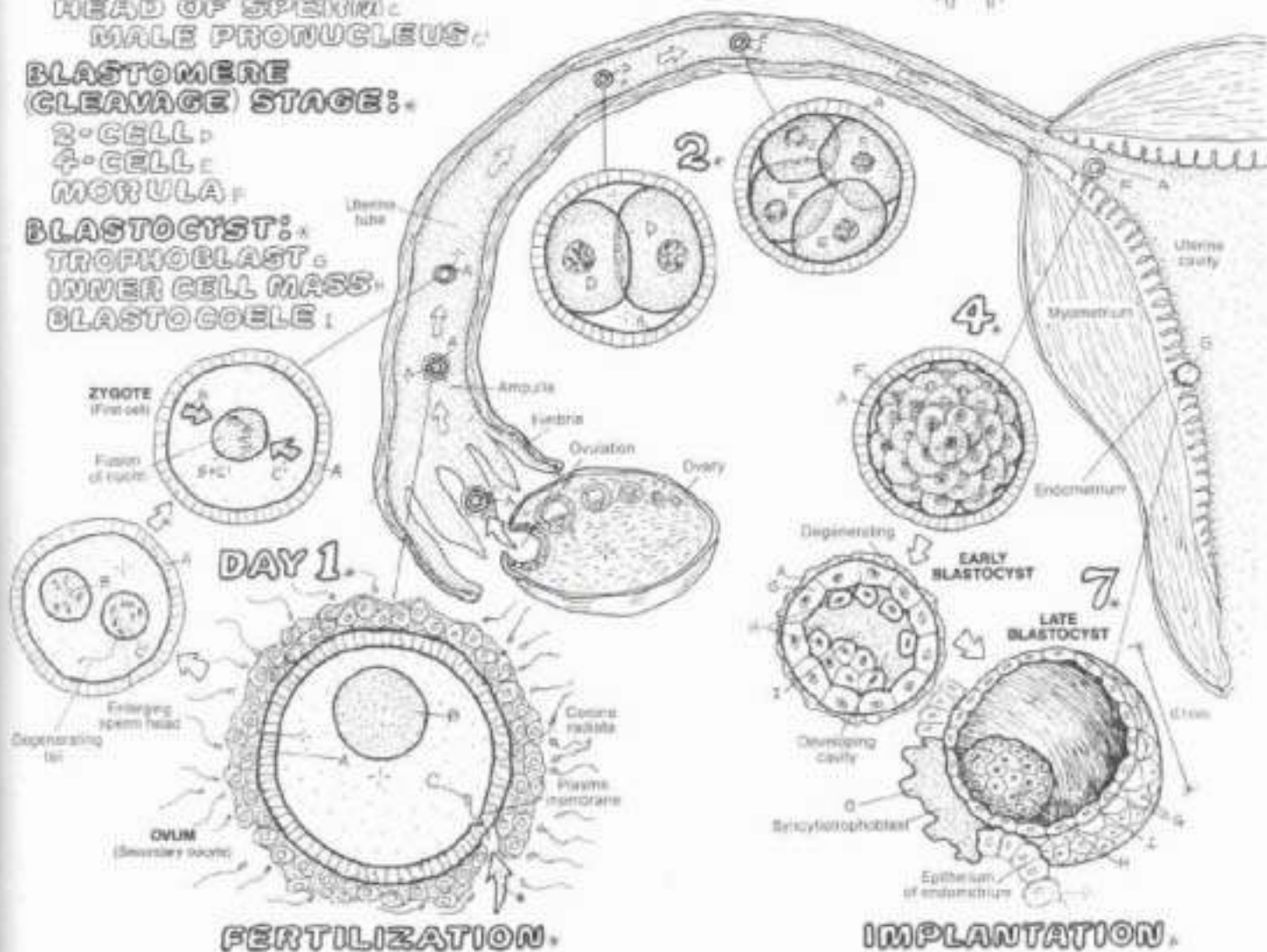
MORULA:

### BLASTOCYST:

TROPHOBLAST:

INNER CELL MASS:

BLASTOCOEL:



Following ovulation, the ovum enters the uterine tube and proceeds toward the uterus. It reaches the ampulla of the tube in about 30 minutes. If sperm-laden semen has been deposited in the fornices of the vagina in the preceding several minutes to several (24) hours, several hundred of the original 50 million or more sperm will successfully reach the ampulla. Over a period of several hours, the sperm become activated and with the aid of sperm-produced enzymes, one of the sperm will penetrate the corona radiata (retained follicular cells) and zona pellucida of the ovum, fuse with the plasma membrane (leaving its cell membrane attached to the ovum's plasma membrane), and enter the ovum. This event is called fertilization. As the tail breaks down and disappears, the head of the sperm enlarges, and forms the male pronucleus. The nucleus of the ovum is the female pronucleus. The two pronuclei approach each other, fuse nuclear membranes, and form a single nucleus. The male and female

chromosomes join up in the metaphase stage of the first mitotic division of the fertilized ovum. The zygote is the name given to the first cell of the new individual.

The zygote undergoes division (cleavage stage) to form two blastomeres. Over the next two days or so post-fertilization, within the restraints of the zona pellucida, the cells divide to form a four cell blastomere and again to form eight cells, and so on, until a ball of cells (morula) is formed. After about five days, the cells within the morula disperse enough to accommodate progressively enlarging fluid-filled cavities. Some cells are pushed aside to form a peripheral rim of cells (trophoblast) enclosing a large single cavity (blastocoel); some cells form an inner cell mass within the blastocoel. This multicellular structure is called the blastocyst. The blastocyst enters the uterus and implants in the endometrium on about the 7th day post-fertilization.



## XII. REPRODUCTIVE SYSTEM EMBRYONIC DEVELOPMENT (2)

Use the same color as on the previous page for trophoblast (C) and note that the syncytiotrophoblast (D) is now given a separate color. Use yellow for F. Complete each drawing before proceeding to the next.

### 2 LAYER EMBRYONIC DISC:

EPIBLAST

HYPOBLAST

### TROPHOBLAST

SYNCYTIOTROPHOBLAST

AMNION/AMNIOTIC CAVITY

YOLK SAC: PRIMARY, SECONDARY

EXOCOELOMIC MEMBRANE

EXTRAEMBRYONIC MEMBRANE

CONNECTING STALK

EXTRAEMBRYONIC COELOM

### 3 LAYER EMBRYONIC DISC:

ECTODERM

MESODERM

ENDODERM

On day 11 post-fertilization, the inner cell mass gives rise to a flat embryonic disc, consisting of a layer of columnar cells (epiblast), and an adjacent layer of cuboidal cells (hypoblast). The epiblast will develop almost entirely into the embryo. The amniotic cavity develops among the trophoblast cells adjacent to the epiblast; the roof of the cavity is called the amnion. The embryo and subsequent fetus will develop within this cavity. The trophoblast also gives rise to the primary yolk sac; the cells lining this sac are continuous with those of the hypoblast. Though it has no yolk, this sac probably has a nutritional function for the embryonic disc. Cells of the trophoblast form an extraembryonic mesoderm tissue (membrane) that largely fills the cavity once known as the blastocyst.

By day 14, the primary yolk sac diminishes in size, replaced by a secondary yolk sac. Cavities within the extra-embryonic membrane form a single cavity (it looks paired, but the connection between yolk sacs does not create two cavities). This cavity (I) surrounds the amnion/amniotic cavity and the yolk sac except where the amnion retains a connecting stalk to the trophoblast layer.

By day 16, the epiblast undergoes significant changes. The primary yolk sac is gone. Cells emerge from the epiblast and migrate into the area between the epiblast and hypoblast and into the hypoblast layer. The cells between are embryonic mesoderm cells; the cells migrating into the hypoblast layer form embryonic endoderm. The remaining epiblast cells become embryonic ectoderm. The earlier two-layered embryonic disc has formed into a three-layered embryonic disc. These three layers are called germ layers and give rise to the cells and tissues of the body. From ectoderm forms the skin and related glands, nervous system, the hypophysis, lens of the eye, and the inner ear. From mesoderm forms bones, muscle and the connective tissues, lymphoid organs, blood, the urogenital system, and serous membranes. From endoderm forms the epithelial part of the gastrointestinal system and respiratory system as well as the epithelia of the pharynx and thyroid.

By day 24 post-fertilization, the once flat embryonic disc has rounded to form either the amniotic cavity an embryo with a definite head end and tail end, secured to the chorion (C, D, H) by the connecting stalk. As the lateral folds of embryonic mesoderm encircle the ventral (anterior) part of the embryo to form the antero-lateral abdominal walls, the yolk sac is pinched off and formation of the primitive gut begins. By the end of three weeks post-fertilization, the gastrointestinal tract, brain, and heart have begun their development.

DAY 11

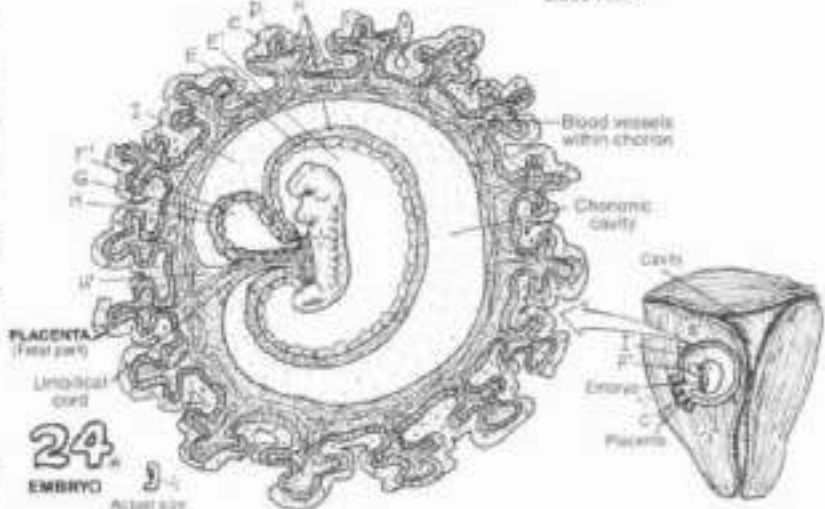
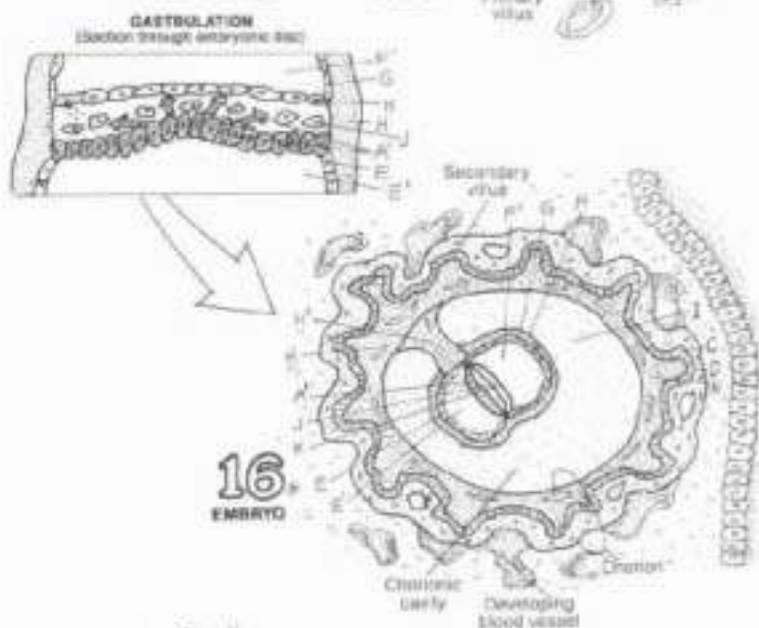
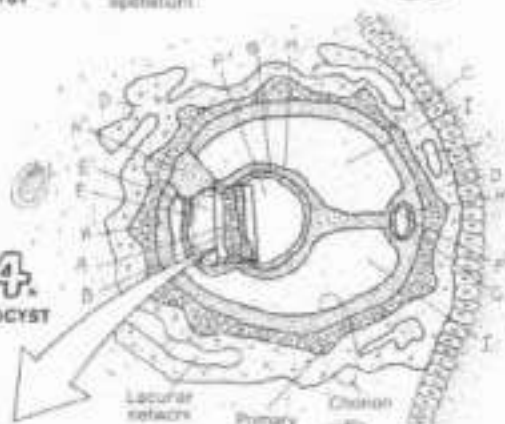
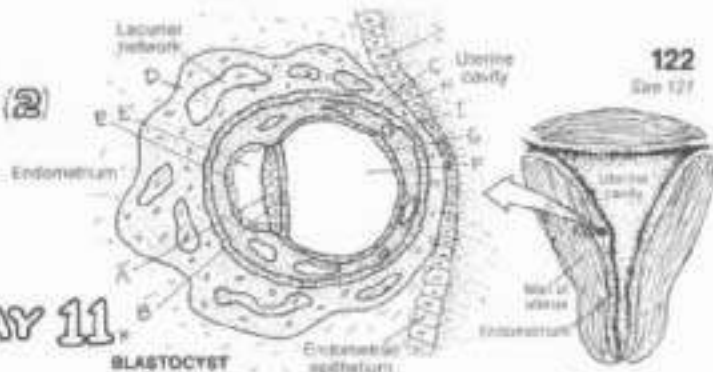
BLASTOCYST

14  
BLASTOCYST

16  
EMBRYO

24  
EMBRYO

Actual size





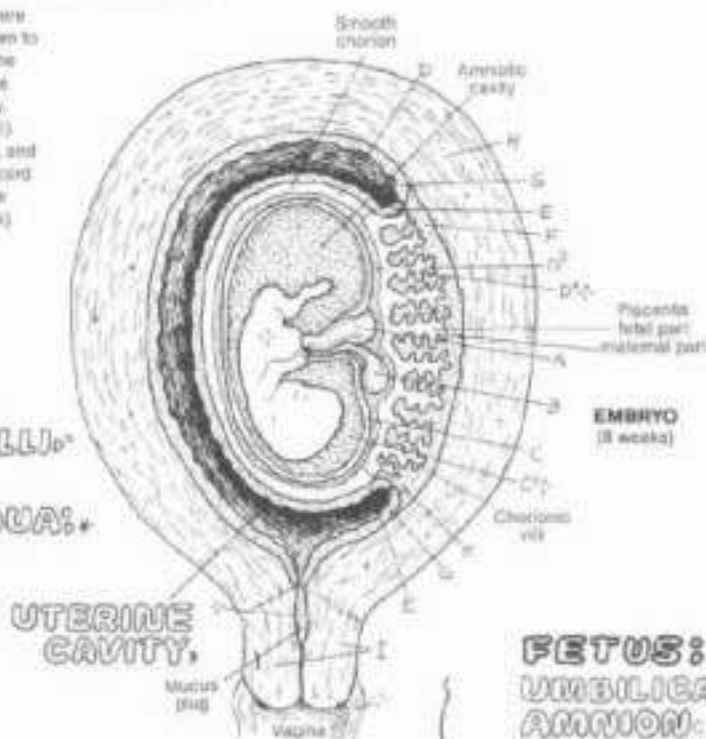## XII. REPRODUCTIVE SYSTEM

### EMBRYO/FETUS COVERINGS

123  
See 82, 122

DN. Use the same colors for structures B and C that were given to them on the preceding plate. Use the color given to "connecting stalk" for the umbilical cord (A), and use the color given to "trophoblast" for chorion (D). (1) Color the embryonic coverings. The uterine cavity is colored gray, though it is actually lined with the decidua capsularis (E). Note that the amniotic cavity (C'), chorionic cavity (D'), and the embryo/fetus are left uncolored. (2) The umbilical cord is composed of different blood vessels but receives one color (A). The band representing the uterine wall (below) is colored with both G and H.

**EMBRYO:**  
**UMBILICAL CORD:**  
**YOLK SAC:**  
**AMNION & CAVITY:**  
**CHORION, CAVITY, VILLI:**  
**UTERUS:**  
**ENDOMETRIAL DECIDUA:**  
**D. CAPSULARIS:**  
**D. BASALIS:**  
**D. PARIETALIS:**  
**MYOMETRIUM:**  
**CERVIX:**



**FETUS:**  
**UMBILICAL CORD:**  
**AMNION, CAVITY:**  
**CHORION, VILLI:**

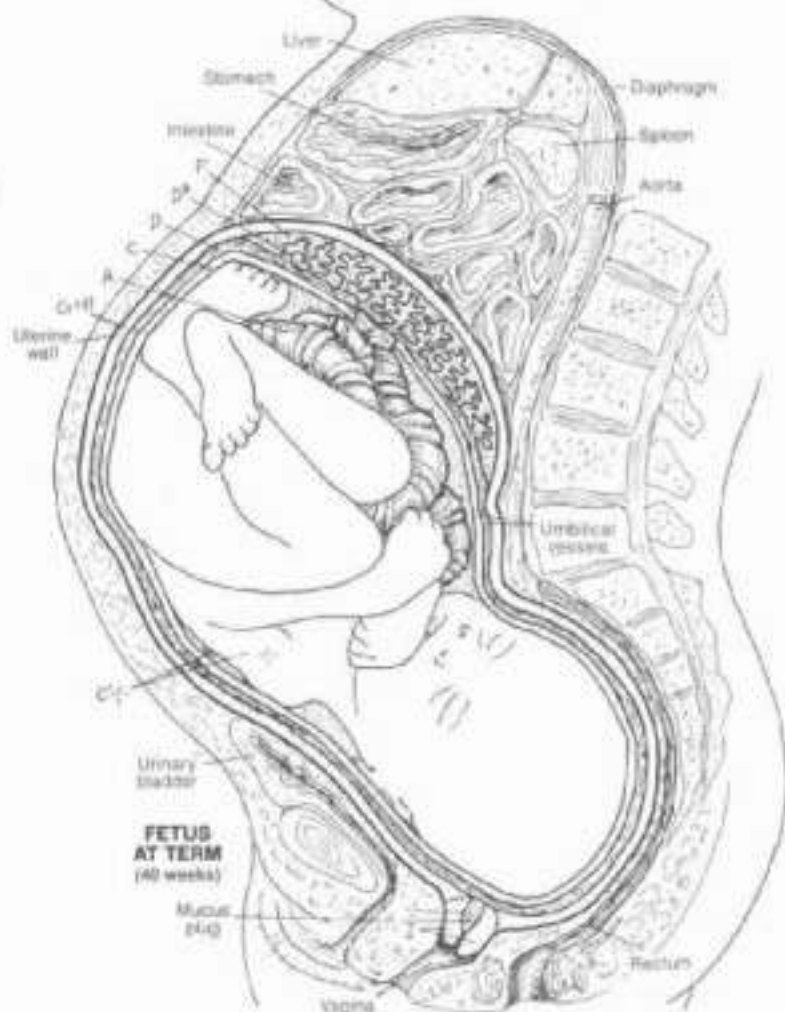
The developing embryo (called the fetus after eight weeks of development) lies within and is supported, nurtured, and protected by membranes and sacs. These coverings have both maternal and fetal origins.

Those of fetal origin include the amnion and chorion/chorionic villi, the umbilical cord, the yolk sac. The chorion forms a sac around the early embryo; the cavity of the sac is the chorionic cavity (recall Plate 122). As the embryo grows, the chorionic sac is obliterated and the amnion and chorion fuse (amniochorionic membrane). The chorion exhibits villi circumferentially early on (e.g., 24 day embryo); in time, most of the villi are absorbed except for those in the developing placenta (eight week embryo), creating a smooth chorion around the amnion and a bushy one (the villi and an underlying chorionic plate) in the future placenta. This is the situation with the fetal membranes at term (40 weeks) as well.

The coverings of maternal origin (the decidua), are thickened, fairly distinct layers of the uterine mucosa (endometrium) in which the blastocyst implanted. Looking at this eight week embryo (above), the decidua basalis is integrated with the fetal villi to form the placenta. The decidua capsularis surrounds the embryo and its membranes. The decidua parietalis lines the uterine cavity, superficial to the myometrium.

The parietalis is continuous with the capsularis as shown. This is the situation with the maternal membranes at eight weeks. When the fetus grows to the point of pushing the decidua capsularis against the parietalis, the uterine cavity is obliterated. The capsularis soon degenerates, leaving only the parietalis (lower illustration). This layer will be retained after birth as the basal endometrium. The decidua basalis and chorionic villi (placenta) will be discharged after birth.

The fetus develops within the fluid-filled amniotic cavity. The plasma-like fluid gives freedom to the embryo to develop its form without mechanical pressure. It also acts as a water cushion absorbing shock forces. Just prior to birth, the amniotic membrane surrounding the fetus bursts, sending a half liter or more fluid into the vagina and to the outside (breaking the "bag of waters"). Parturition (childbirth) generally occurs about 280 days (40 weeks) after fertilization.



# XIII. ENDOCRINE SYSTEM

## INTRODUCTION

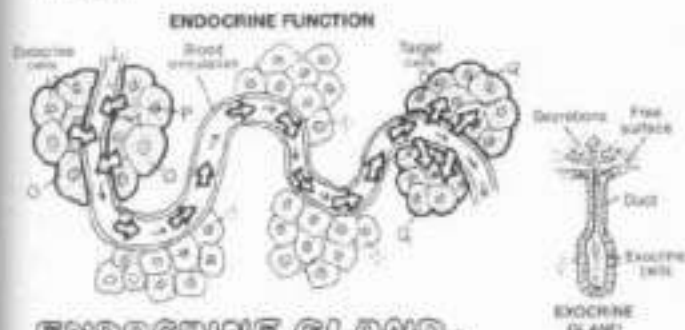
Ch: Use a very light color for C, and a darker one for D (actually located on posterior surface of thyroid) (1) After coloring endocrine glands and tissues, color the scheme at lower left

- ENDOCRINE GLANDS:**  
**HYPHYPHYSIS (PITUITARY)**  
**PINEAL**  
**THYROID**  
**PARATHYROID (4)**  
**THYMUS**  
**ADRENAL (SUPRARENAL) (2)**  
**PANCREAS**  
**OVARY (2)**  
**TESTIS (2)**

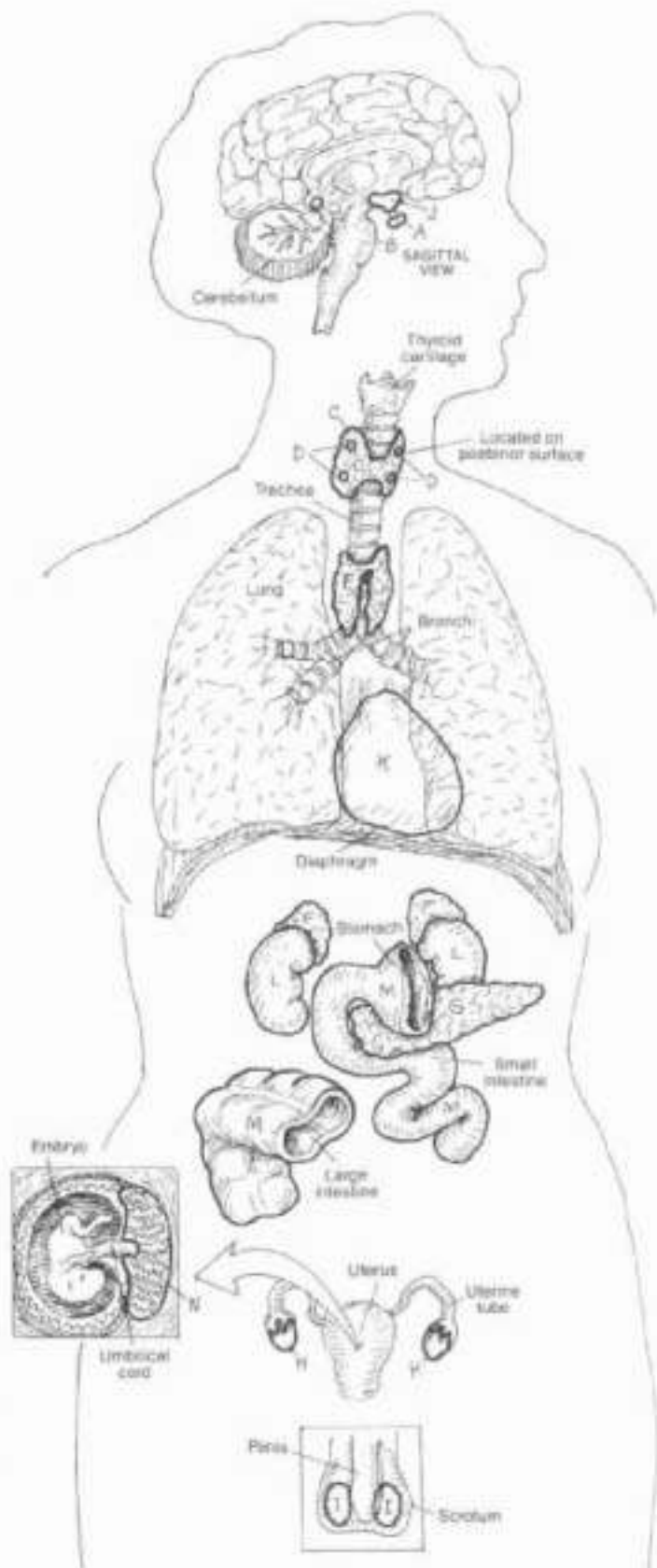
- ENDOCRINE TISSUES:**  
**HYPOTHALAMUS**  
**HEART**  
**KIDNEY (2)**  
**GASTROINTESTINAL TRACT**  
**PLACENTA**

Endocrine glands and tissues are discrete masses of secretory cells and their supporting tissue and neighboring capillaries into which the cells secrete their hormones. These glands are without ducts. Some endocrine secretory cells exist in non-endocrine organs; they may be diffusely distributed (e.g., enteroendocrine cells of the gastrointestinal tract, interstitial cells of the testis), or they may occur as microscopic "islands" (e.g., pancreatic islets), or they may be a group of secretory neurons in the brain (hypothalamus). Others form single organs, the principal function of which is to secrete hormones (e.g., thyroid, hypophysis, and so on). Hormones are chemical agents usually effective among cells (target organs) some distance from their source. In concert with the nervous system, endocrine organs/tissues integrate and harmonize the activities of varied and sometimes seemingly unrelated organs and their activities by negative and positive feedback control mechanisms, resulting in growth, reproduction and related activity, and metabolic stability (a condition of the body's internal environment known as homeostasis).

Less well-known endocrine activity is seen in the heart (secretes atrial natriuretic peptide or ANP, increases sodium excretion and inhibits smooth muscle contractions), the kidney (secretes renin which is involved in the formation of substances that cause vasoconstriction and raise blood pressure; and erythropoietin which stimulates red blood corpuscle development), the gastrointestinal tract (produces numerous polypeptide hormones that regulate gastrointestinal motility and enzyme secretion), and the placenta (secretes human chorionic gonadotropin or HCG in support of embryonic growth during the first 90 days post-fertilization; also secretes estrogen, progesterone, and a lactogenic and growth-stimulating hormone).



**ENDOCRINE GLAND.**  
**HORMONAL SECRETION.**  
**TARGET ORGAN.**

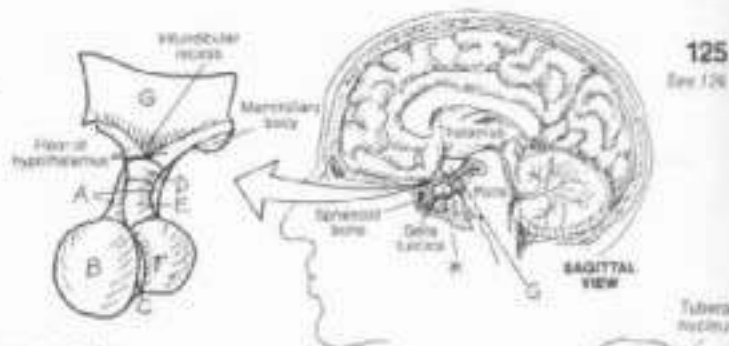




# XIII. ENDOCRINE SYSTEM

## HYPHYPHYSIS & HYPOTHALAMUS

Ch: Use red for H, blue for K, purple for L, and a very light color for J  
 (1) Begin with the enlarged view of the hypophysis and hypothalamus.



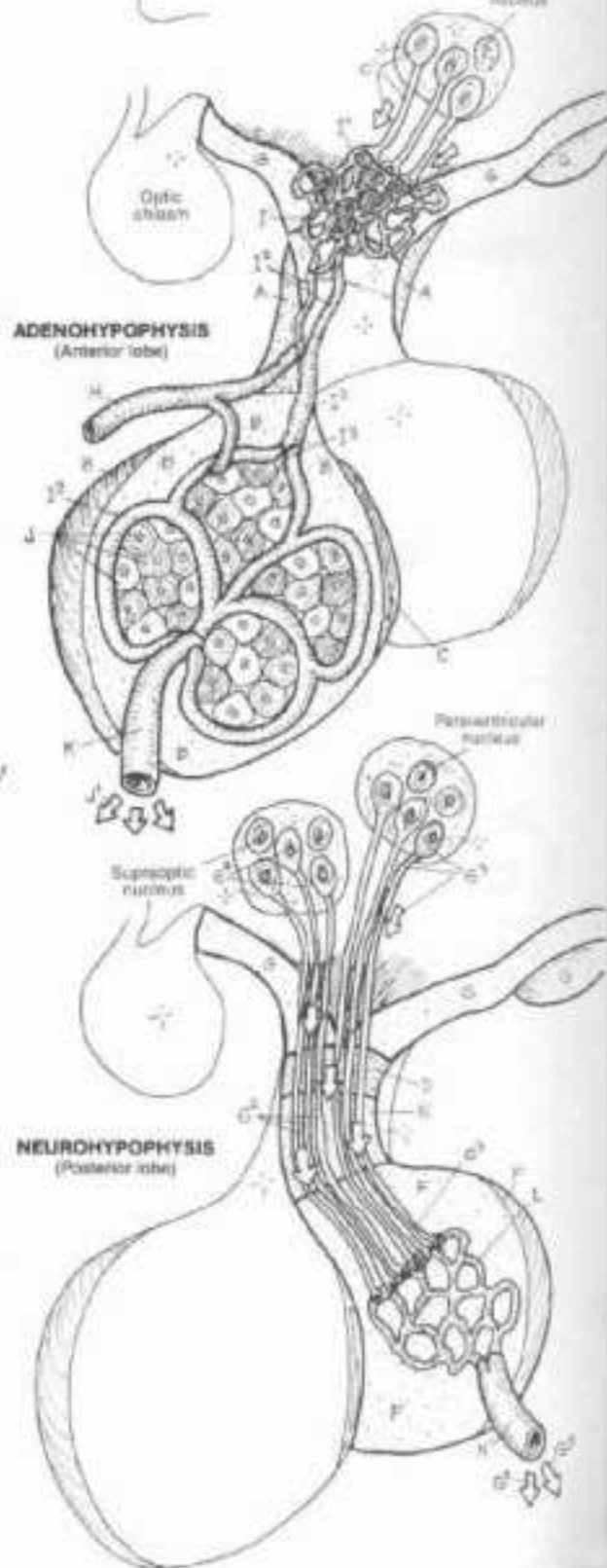
### HYPHYPHYSIS (PITUITARY GLAND):\*

**ADENOHYPHYPHYSIS:**  
 PARS TUBERALIS,  
 PARS DISTALIS (ANT. LOBE),  
 PARS INTERMEDIUS.

**NEUROHYPHYPHYSIS:**  
 MEDIAN EMINENCE,  
 INFUNDIBULAR STEM,  
 PARS NERVOSA (POST. LOBE)†

### HYPHYPHALAMUS †

The hypophysis (pituitary gland) is suspended from the hypothalamus of the brain by the infundibulum and fits into a bony recess of the sphenoid bone called the sella turcica. The hypophysis is about the size of four peas. The gland is derived from an upward extension of the developing roof of the mouth (adenohypophysis) and a downward migration of the floor of the hypothalamus of the brain (neurohypophysis). From above to below, the neurohypophysis includes the median eminence, the infundibular stem and the pars nervosa (posterior lobe). It is contiguous with the hypothalamus. The adenohypophysis includes the pars tuberalis which embraces the infundibular stem, the pars distalis (anterior lobe), and the pars intermedia which is rudimentary and appears to secrete no significant levels of hormones.



**ADENOHYPHYPHYSIS:**  
 HYPHYPHAL. SECR. NEURON / HORMONE †  
 SUP. HYPHYPHYSAL ARTERY †  
 HYPHYPHYSAL PORTAL SYSTEM †  
 CAPILLARY / PORTAL V. / SINUSOID †  
 SECRETORY CELL / HORMONES †  
 INF. HYPHYPHYSAL VEIN †

The pars distalis of the adenohypophysis contains cells that secrete one of several hormones (see next plate). These cells are stimulated by hormones from secretory neurons in the hypothalamus. These hormones reach the pars distalis by way of a vascular portal system, capillaries in the median eminence form long and short portal veins that enter the pars distalis and form sinusoids around the secretory cells. Secretions from these cells enter the sinusoidal vessels which are drained by inferior hypophyseal veins.

**NEUROHYPHYPHYSIS:**  
 HYPHYPHAL. SECRETORY NEURONS OF:  
 SUPRAOPTIC NUCL. / HORMONE †  
 PARAVENTRIC. NUCL. / HORMONE †  
 CAPILLARY PLEXUS,  
 HYPHYPHYSAL VEIN †

The pars nervosa of the neurohypophysis has no secretory cells of its own. Axons of secretory neurons in the supraoptic and paraventricular nuclei of the hypothalamus extend down through the infundibulum to capillary networks in the posterior lobe. There these axon terminals release oxytocin and antidiuretic hormones into the circulation (see next plate).



# XIII. ENDOCRINE SYSTEM

## HYPHYPHYSIS & TARGET ORGANS

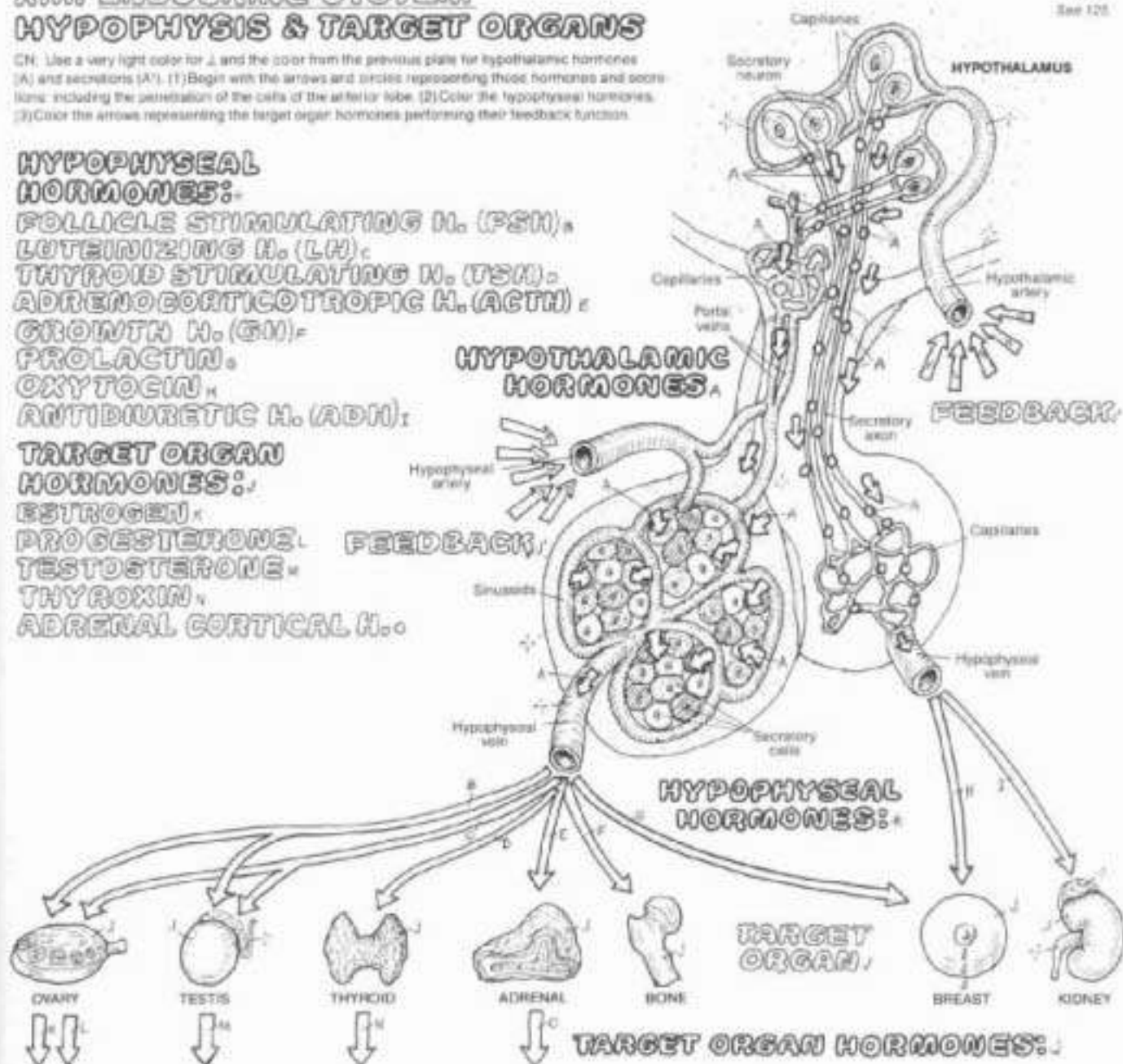
CH. Use a very light color for A and the color from the previous plate for hypothalamic hormones (A) and secretions (A'). (1) Begin with the arrows and circles representing those hormones and secretions including the penetration of the cells of the anterior lobe. (2) Color the hypothalamic hormones. (3) Color the arrows representing the target organ hormones performing their feedback function.

### HYPHYPHYSAL HORMONES:

- FOLLICLE STIMULATING H. (FSH)
- LUTEINIZING H. (LH)
- THYROID STIMULATING H. (TSH)
- ADRENOCORTICOTROPIC H. (ACTH)
- GROWTH H. (GH)
- PROLACTIN
- OXYTOCIN
- ANTIDIURETIC H. (ADH)

### TARGET ORGAN HORMONES:

- ESTROGEN
- PROGESTERONE
- TESTOSTERONE
- THYROXIN
- ADRENAL CORTICAL H.



### STRUCTURAL/FUNCTIONAL EFFECT/FEEDBACK:

The hypothalamus has been seen in the previous plate to be intimately connected to the hypophysis by blood vessels and secretory axons. Here we look at hypothalamic (releasing) hormones, hypophyseal (pituitary) hormones, their target organs and the hormones of the target organs. The secretory (granular) cells of the pars distalis (anterior lobe) are stimulated by hypothalamic hormones which are released by secretory axons into the hypophyseal portal system in the median eminence (infundibulum). The secretions of these cells are adeno-hypophyseal hormones which enter the circulation and mediate the activities of a number of target organs. *FSH* drives ovarian follicular growth and secretion of estrogen and testicular spermatogenesis. *LH* stimulates testosterone secretion, ovulation, development of the corpus luteum, and estrogen/progesterone secretion. *TSH* stimulates secretion of thyroxin, a hormone of the thyroid gland. Adrenocorticotrophic hormone (*ACTH*, corticotropin) stimulates the secretion of adrenal cor-

tical hormones; *ACTH* also has melanocyte-stimulating properties (dispersal of pigment in the skin). *GH* stimulates body growth, especially bone. Prolactin mediates milk secretion. Oxytocin and antidiuretic hormone (*ADH*; vasopressin) are products of secretory neurons in the supraoptic and paraventricular nuclei of the hypothalamus. These hormones are transported down long axons to be released among capillaries in the pars nervosa (posterior lobe) of the neurohypophysis. Oxytocin induces ejection of milk and stimulates uterine contractions. Vasopressin causes retention of body water (antidiuresis) by the kidneys; given exogenously, vasopressin is a significant vasoconstrictor. Control of hypothalamic and hypophyseal secretions is accomplished by feedback mechanisms. Negative feedback control is reflected by the relationship of estrogen to *FSH*; as estrogen concentration in the plasma increases, production of *FSH* diminishes. Positive feedback responses are less common.

## XII. ENDOCRINE SYSTEM

### THYROID & PARATHYROID GLANDS

127

Ch: Use red for H, blue for I, light colors for E, F, G, and the same colors as on Plate 124 for A and D. (1) Color the three upper views simultaneously, taking note of the arteries and veins that penetrate the thyroid. (2) Color the microscopic sections of hyposecretive and hyperactive thyroid follicles; normal tissue lies between the two extremes. (3) Color the diagram of thyroid and parathyroid function.

#### THYROID<sup>A</sup>

THYROID FOLLICLE:  
FOLLICLE CELL:  
COLLOID:  
THYROXIN<sup>A</sup>

#### PARATHYROID (4)<sup>D</sup>

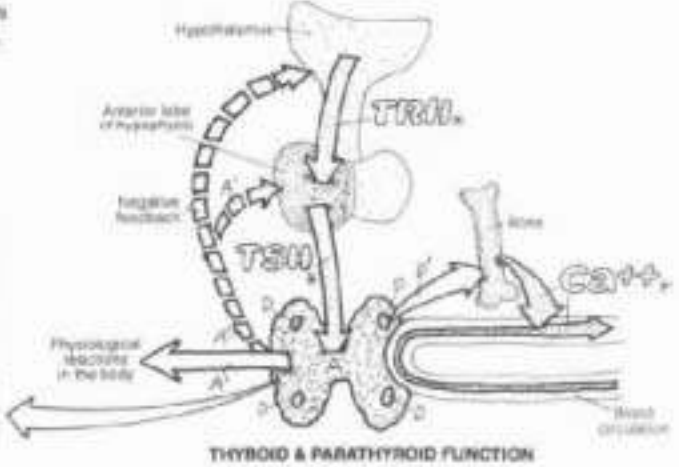
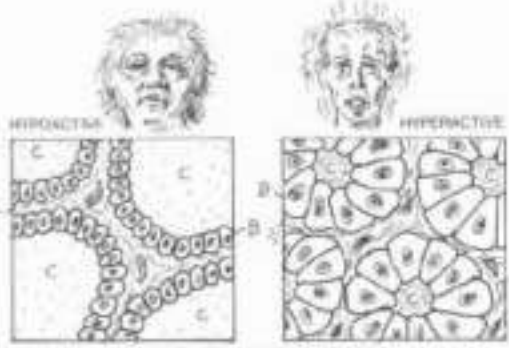
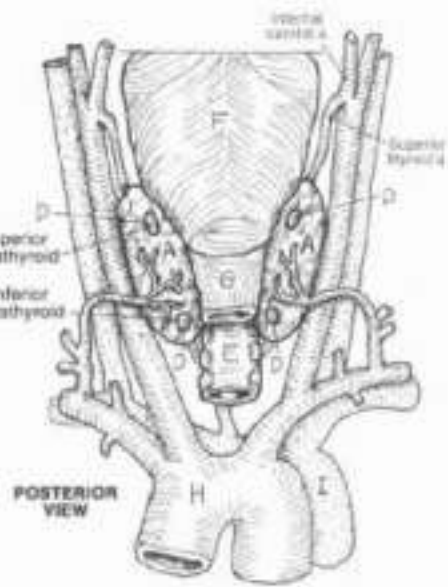
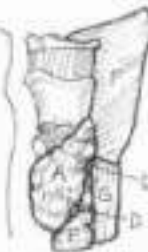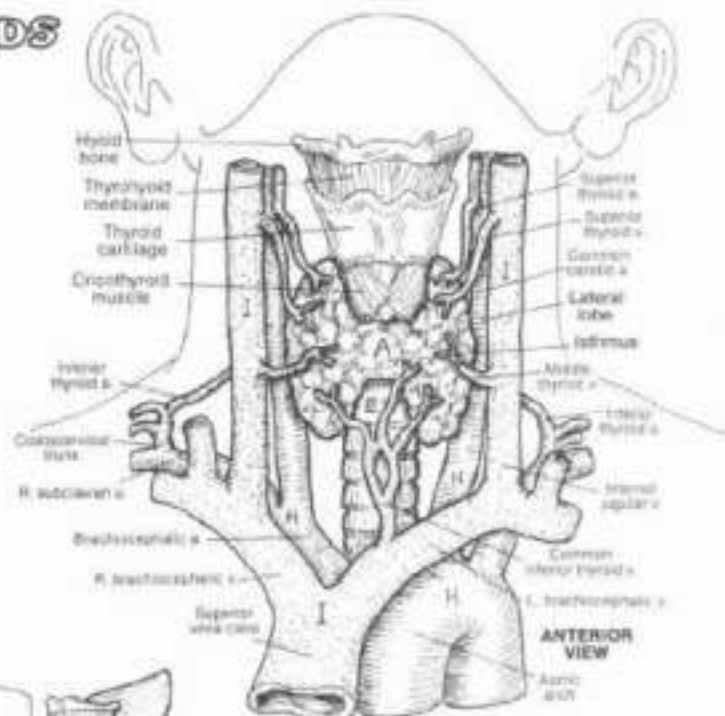
PARATHORMONE<sup>D</sup>

#### RELATED STRUCTURES:<sup>H</sup>

TRACHEA:  
PHARYNX:  
ESOPHAGUS:  
ARTERIES:  
VEINS:

The thyroid gland, covering the anterior surfaces of the 2nd to 4th tracheal rings, is bound by a fibrous capsule whose posterior layer encloses the four parathyroid glands. The thyroid gland, composed of right and left lobes connected by an isthmus, consists of clusters of follicles (like grapes) supported by loose fibrous tissue rich in blood vessels. A microscopic section through a follicle reveals a single layer of cuboidal epithelial cells forming the follicular wall. The follicle contains colloid, a glycoprotein (thyroglobulin), produced by the follicle cells. These cells take up thyroglobulin and dismantle it to form a number of hormones, primarily thyroxin (T<sub>4</sub>, tetraiodothyronine). Thyroxin is then secreted into the adjacent capillaries. Thyroid hormones contain iodide (a reduced form of iodine) which is absorbed by the follicle cells from the blood. Thyroxin formation and secretion is encouraged by thyroid-stimulating hormone (TSH) from the hypophysis. The relationship operates on a negative feedback mechanism: increased secretions of thyroxin inhibit further secretion of TSH. Thyroxin increases oxygen consumption in practically all tissues, and thus maintains the metabolic rate. It is involved at many levels in growth and development. Excessive secretion of thyroxin generally results in weight loss, extreme nervousness, and an elevated basal metabolic rate. Congenital thyroid insufficiency is manifested by dwarfism and mental retardation; in late onset, mental activity is diminished, the voice changes, and accumulation of mucous material in the skin and fascia gives a puffy appearance.

The parathyroids consist of small buttons of highly vascular tissue containing two cell types, one of which secretes parathormone. Parathormone maintains plasma calcium levels by inducing osteoclastic activity (bone breakdown), freeing calcium ions. Normal muscle activity and blood clotting depend on normal calcium levels in the plasma. Reduced parathyroid function lowers calcium levels and below certain levels causes muscle stiffness, cramps, spasms, and convulsions (tetany).



Cross sections through follicles (approximately x 200)



# XIII. ENDOCRINE SYSTEM

## ADRENAL (SUPRARENAL) GLANDS

Color the red for F, blue for B, yellow for H, and a very light color for E. (1) In the upper view only those vessels with subscripts are to be colored. (2) Color the cross section through the adrenal, and related arrows and hormones. (3) Color the various organs associated with the "fight or flight" reaction, noting the listed effects.

### ADRENAL GLAND

CAPSULE

CORTIX:

ZONA GLOMERULOSA:

ZONA FASCICULATA:

ZONA RETICULARIS:

MEDULLA:

ARTERIES:

SUPERIOR SUPRARENAL A.<sub>B, F</sub>

MIDDLE SUPRARENAL A.<sub>F</sub>

INFERIOR SUPRARENAL A.<sub>B, F</sub>

VEINS:

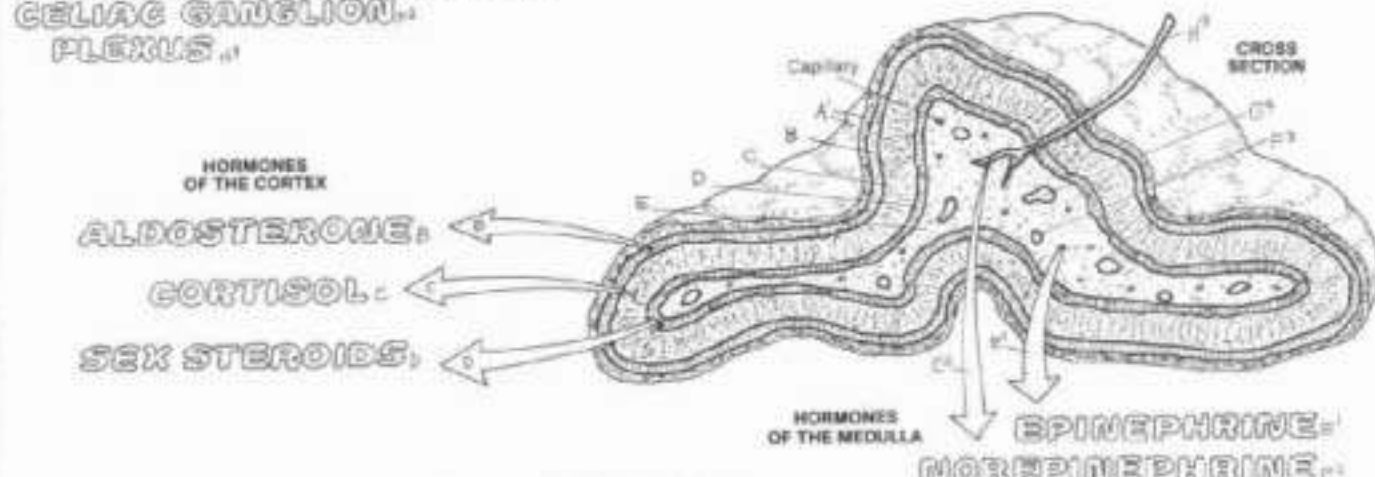
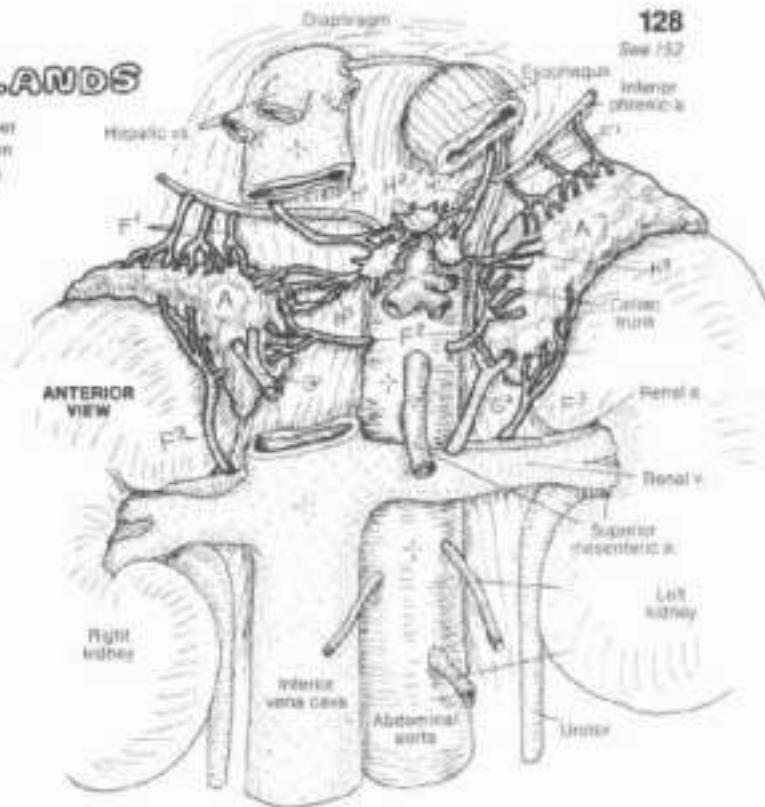
R. & L. SUPRARENAL V.<sub>F</sub>

SUPRARENAL PLEXUS:

GREATER SPLANCHNIC N.<sub>B, H</sub>

CELIAC GANGLION:

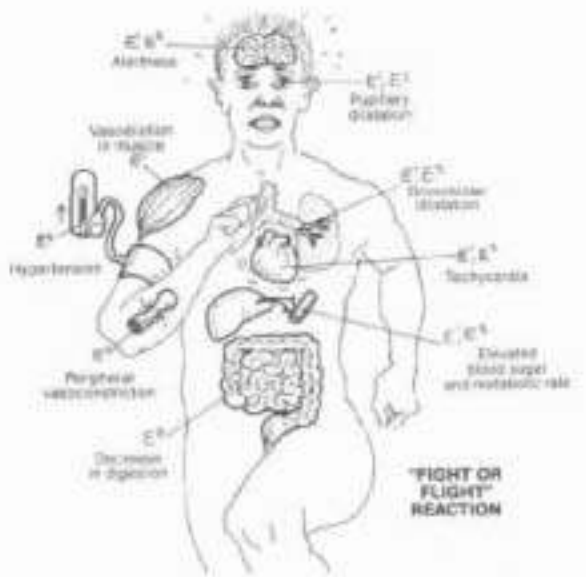
PLEXUS



The adrenal (suprarenal) glands lie in the retroperitoneum within the renal fascia on the superior and medial aspects of each kidney (T11-T12 vertebral levels). As with other endocrine glands, the adrenals are abundantly vascularized. The adrenals are two different glands encapsulated as one: the outer cortex and the inner medulla.

The adrenal cortex is organized into three regions: the outer zona glomerulosa (secreting hormones dealing with fluid/electrolyte balance, such as aldosterone and other mineralocorticoids); and the zona fasciculata and zona reticularis (secreting hormones influencing carbohydrate metabolism, such as cortisol and other glucocorticoids; also low levels of sex hormones). Hypophyseal ACTH stimulates secretion of the glucocorticoids. Aldosterone is secreted in response to certain enzymes in the blood (renin-angiotensin system). All these hormones play roles involving all aspects of protein, carbohydrate, electrolyte, and water metabolism; thus the adrenal cortex is necessary for life.

The medulla consists of cords of secretory cells supported by reticular fibers, and an abundant collection of capillaries. Fibers of the greater splanchnic nerve (from spinal cord segments T5-T10; a major pre-ganglionic nerve of the sympathetic division of the autonomic nervous system) pass through the celiac ganglia without synapsing to enter the adrenal gland. These fibers terminate on and stimulate the medullary secretory cells, 50% of which produce and release epinephrine, the rest secrete norepinephrine. These secretory cells are, in fact, modified post-ganglionic neurons. Their secretions stick the "fight or flight" reaction: in response to life-threatening situations as diagrammatically represented at right.





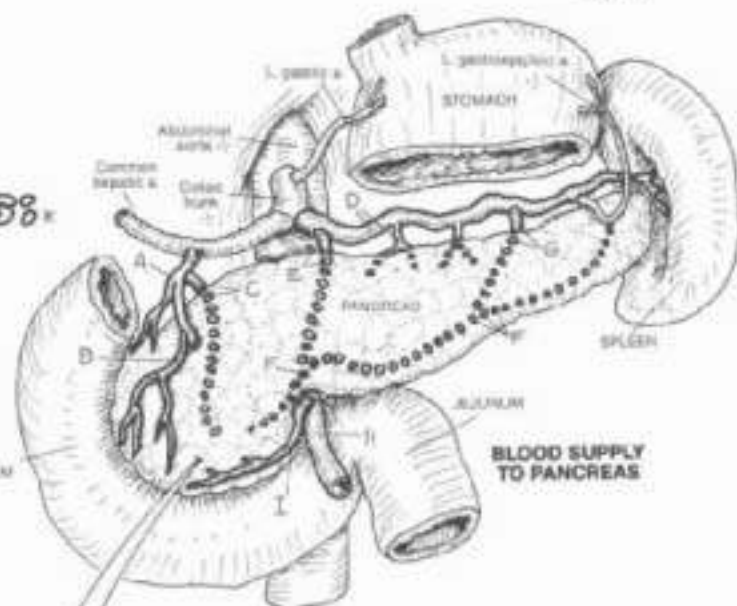
# XIII. ENDOCRINE SYSTEM

## PANCREATIC ISLETS

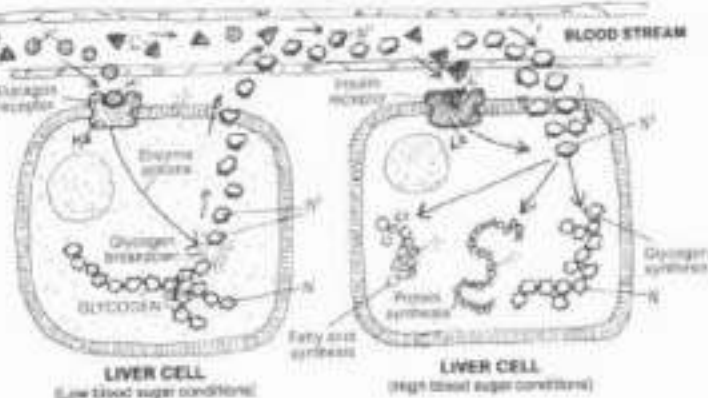
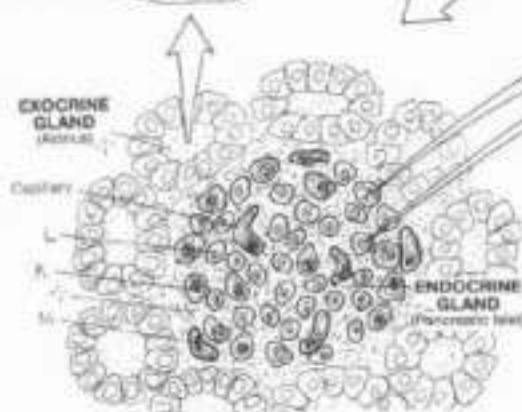

CH. Use purple for M, and light colors for K and L. (1) In coloring the upper drawing, include the broken lines representing arteries within or on the posterior surface of the pancreas. (2) Color the microscopic section of the pancreas and the enlarged view of an islet. Color the arrows and the diagram reflecting the role of glycogen and insulin receptors in liver cells with respect to glucose and glycogen.

- ARTERIES TO THE PANCREAS:**
- GASTRODUODENAL & BR<sub>1</sub>, A
  - ANT. PANCREATICO-DUOD., B
  - POST. PANCREATICO-DUOD., C
  - SPLenic & BR<sub>2</sub>, D
  - DORSAL PANCREATIC, E
  - INFERIOR PANCREATIC, F
  - GREAT PANCREATIC, G
  - SUPERIOR MESENTERIC, H
  - INF. PANCREATICO-DUOD., I

The pancreas is supplied by numerous arteries from sources springing from the celiac and superior mesenteric arteries. The extensive capillary networks of the pancreas are drained by tributaries of the hepatic portal vein which conducts the secreted hormones of the pancreatic islets to the liver and beyond for general circulation.



- PANCREATIC ISLET:**
- ALPHA CELL, K
  - GLUCAGON<sub>K</sub>/RECEPTOR<sub>K</sub>
  - BETA CELL, L
  - INSULIN<sub>L</sub>/RECEPTOR<sub>L</sub>
  - BLOOD CAPILLARY<sub>M</sub>
  - GLYCOGEN<sub>N</sub> GLUCOSE<sub>N</sub>



The islets (islets) of endocrine tissue (and their capillaries) in the pancreas are surrounded by masses of grape-like clusters/follicles of exocrine gland cells. The secretions of these cells enter ducts that are tributaries of the pancreatic duct(s) opening into the duodenum.

The islets are characterized by three or four different cell types. Alpha (A) cells, generally located in the periphery of the islet, secrete glucagon, a polypeptide hormone that binds to glycogen receptors on liver cell membranes. Glucagon induces the enzymatic breakdown of glycogen to glucose, a process called glycogenolysis. Glucagon also facilitates the formation of glucose from amino acids in the liver, a process called gluconeogenesis. As a result of these processes, blood glucose levels increase.

Beta (B) cells, constituting 70% of the islet cell population, occupy the central part of the islet and secrete insulin, a polypeptide, primarily in response to increased plasma levels of glucose. Most insulin is taken up by the liver and kidney,

but almost all cells can metabolize insulin. Insulin expedites the removal of glucose from the circulation by increasing the number of proteins that transport glucose across cell membranes (glucose carriers, not shown) in muscle cells, fat cells, leukocytes, and certain other cells (not including liver cells). Insulin increases the synthesis of glycogen from glucose in liver cells. Uptake of insulin is facilitated by insulin receptors (proteins) on the external and internal surfaces of many—but not all—cell membranes. Decreased insulin secretion or decreased numbers or activity of insulin receptors leads to glucose intolerance and/or diabetes mellitus. The effects of insulin activity are far-reaching: mediating electrolyte transport and the storage of nutrients (carbohydrates, proteins, fats), facilitating cellular growth, and enhancing liver, muscle, and adipose tissue metabolism. The islets also reveal two other sensory cell types: D and F cells (not shown). These cells are in the periphery of the islet, and constitute about 5-10% of the islet cell population.

## XIV. NERVOUS SYSTEM ORGANIZATION

**CN:** Use very light colors for A and C. (1) The spinal cord has been placed behind the vertebral column in the main illustration to show the length of the cord and corresponding spinal cord regions in relation to the length and regions of the vertebral column. Note the descending spinal nerve roots (arrows coming off the right) in the lumbar region and below. (2) In coloring the spinal nerves and their peripheral branches at lower right, color over the lines representing them. (3) Color the motor ganglia of the autonomic nervous system (L and M) in the lower right drawing.

### CENTRAL (CNS) NERVOUS SYSTEM:

#### BRAIN:

CEREBRUM

BRAINSTEM

CEREBELLUM

#### SPINAL CORD, / REGIONS:

CERV., THOR., LUM., SAC., COX

The nervous system consists of neurons arranged into a highly integrated central part (central nervous system, or CNS) and bundles of neuronal processes (nerves) and islands of neurons (ganglia) largely outside the CNS making up the peripheral part (peripheral nervous system, or PNS). These neurons are supported by neuroglial cells, and a rich blood supply. Neurons of the CNS are interconnected to form centers (nuclei, gray matter) and axon bundles (tracts, white matter). The brain is the center of sensory awareness and movement, emotions, rational thought and behavior, foresight and planning, memory, speech, language and interpretation of language.

The spinal cord, an extension of the brain beginning at the foramen magnum of the skull, traffics in ascending/descending impulses, and is a center for spinal reflexes, source of motor commands for muscles below the head, and receiver of sensory input below the head.

### PERIPHERAL (PNS) NERVOUS SYSTEM:

#### CRANIAL NERVES (12 PAIR) E

#### SPINAL NERVES / BRANCHES F

CERVICAL (8) G

THORACIC (12) H

LUMBAR (5) I

SACRAL (5) J

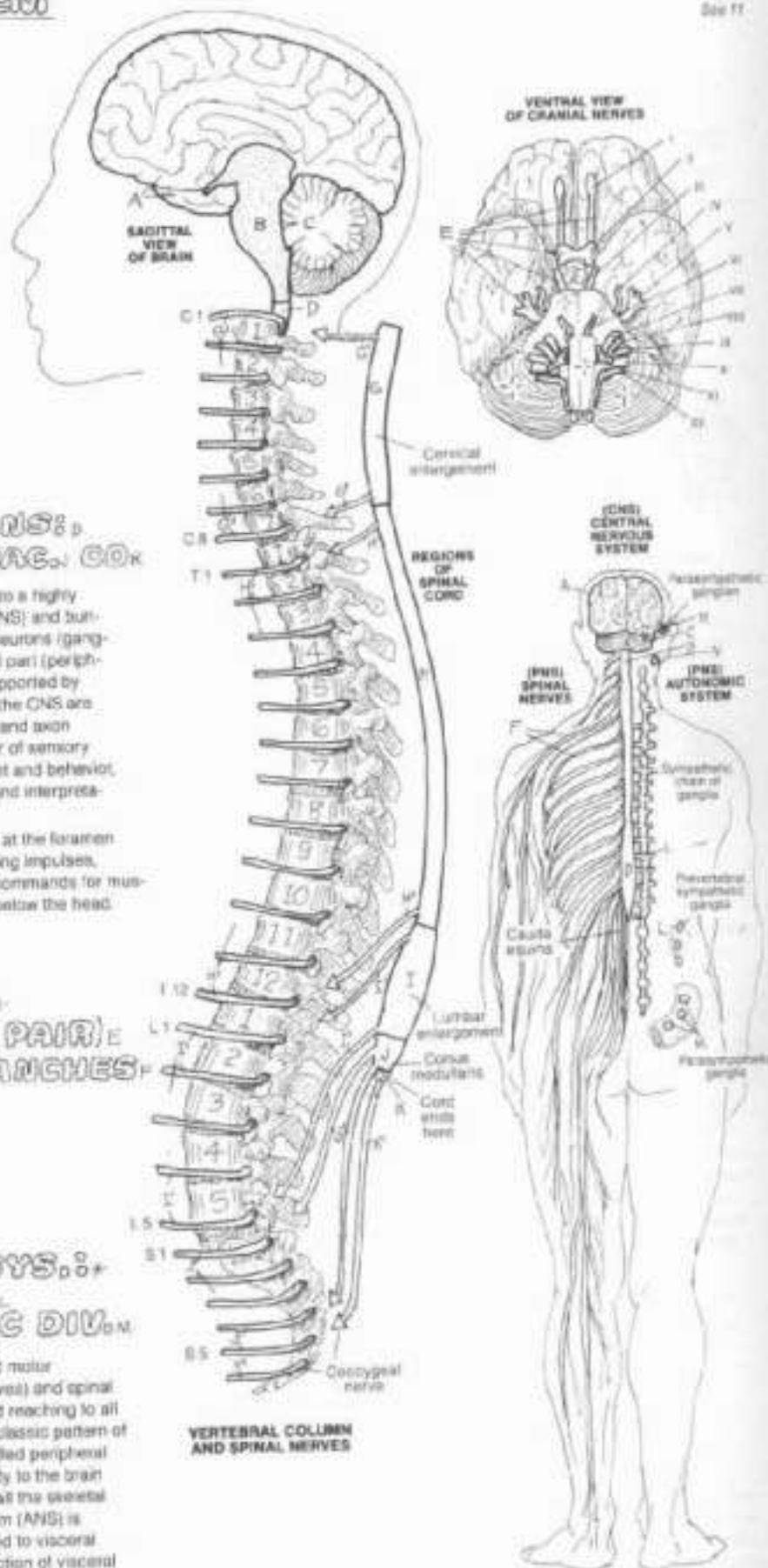COCCYGEAL (1) K

#### AUTONOMIC NERVL. SYS. L, M

SYMPATHETIC DIV.

PARASYMPATHETIC DIV. N

The PNS consists largely of bundles of sensory and motor axons (nerves) radiating from the brain (cranial nerves) and spinal cord (spinal nerves) segmentally and bilaterally and reaching to all parts of the body (visceral and somatic) through a classic pattern of distribution. Branches of spinal nerves are often called peripheral nerves. Nerves conduct all sensations from the body to the brain and spinal cord, and conduct motor commands to all the skeletal muscles of the body. The autonomic nervous system (ANS) is a subset of ganglia and nerves in the PNS dedicated to visceral movement and glandular secretion, and the conduction of visceral sensations to the spinal cord and brain.



VERTEBRAL COLUMN AND SPINAL NERVES

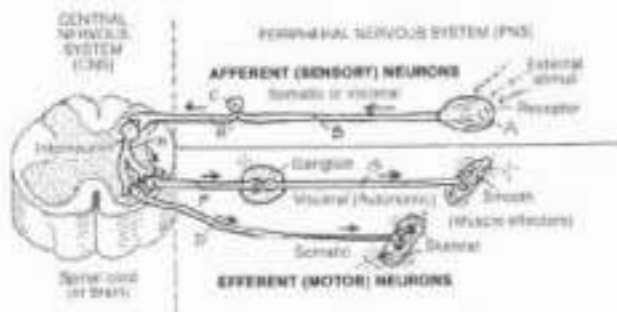


# XIV. NERVOUS SYSTEM

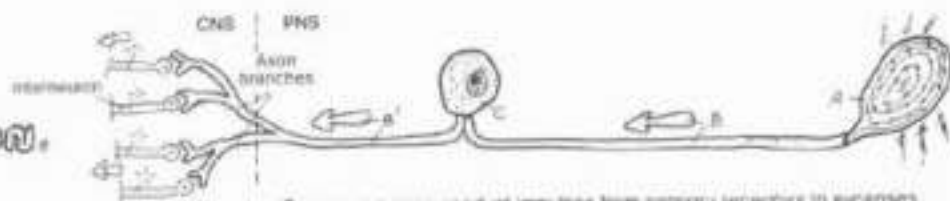
## FUNCTIONAL CLASSIFICATION OF NEURONS

CN: Use light colors throughout the plate.  
Do not color the summary diagram at the top of the page until completing the rest of the plate.

Neurons generally function in one of three modes: they conduct impulses from receptors in the body to the central nervous system or CNS (sensory or afferent neurons); or they conduct motor command impulses from the CNS to muscles of the body (motor or efferent neurons); or they form a network of interconnecting neurons in the CNS between motor and sensory neurons (interneurons). If the sensory or motor neurons relate to musculoskeletal structures or the skin and limbs, the prefix "somatic" may be applied (somatic afferent/somatic efferent). If these neurons are related to organs with hollow cavities (viscera), the prefix "visceral" may be applied (visceral afferent/visceral efferent).




**PNS:**  
**SENSORY NEURON.**  
**RECEPTOR.**  
**AXON**  
**(PERIPHERAL PROCESS):**  
**CELL BODY:**  
**AXON**  
**(CENTRAL PROCESS):**



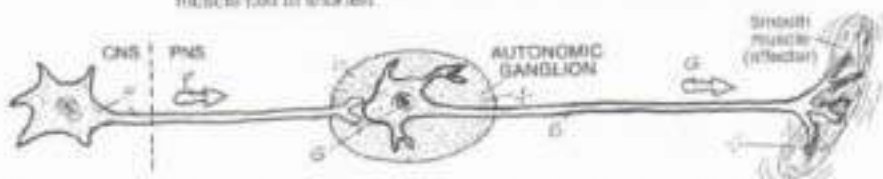
Sensory neurons conduct impulses from sensory receptors to synapses in the CNS. The receptors may be sensitive to touch, pressure, pain, joint position, muscle tension, chemical concentration, light, or other mechanical stimulus, basically providing information on the external or internal environment and related changes. Sensory neurons are unipolar neurons with certain exceptions, and are characterized by peripheral processes ("axons"), cell bodies, and central processes ("axons").

**PNS:**  
**SOMATIC MOTOR N.**  
**CELL BODY:**  
**AXON.**  
**MOTOR END PLATE:**



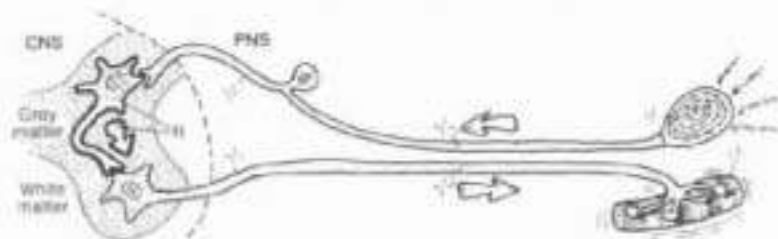
Motor neurons conduct impulses from cell bodies located in the CNS, through axons that leave the CNS and subsequently divide into branches, each of which becomes incorporated into the cell membrane of a muscle cell (motor end plate). Here the neuron releases its neurotransmitter that induces the muscle cell to shorten.

**PNS:**  
**AUTONOMIC MOTOR N.**  
**PREGANGLIONIC NEURON.**  
**POSTGANGLIONIC NEURON.**



Autonomic motor neurons function as paired units connected at a ganglion by synapse. The first or preganglionic neuron arises in the CNS, and its axon embarks for a ganglion located some distance from the CNS. There it synapses with the cell body or dendrite of a postganglionic neuron whose axon proceeds to the effector organ: smooth muscle, cardiac muscle, or glands.

**CNS:**  
**INTERNEURON**  
**(ASSOCIATION N.)**



Interneurons are found mostly in the CNS. They make up the bulk of the neurons of the brain and spinal cord. They come in a variety of shapes and sizes. Many of them are directly related to incoming (sensory) impulses and others to outgoing motor commands. Others serve to integrate sensory or ascending input with higher centers to effect an appropriate motor output.



# XIV. NERVOUS SYSTEM

## SYNAPSES & NEUROTRANSMITTERS

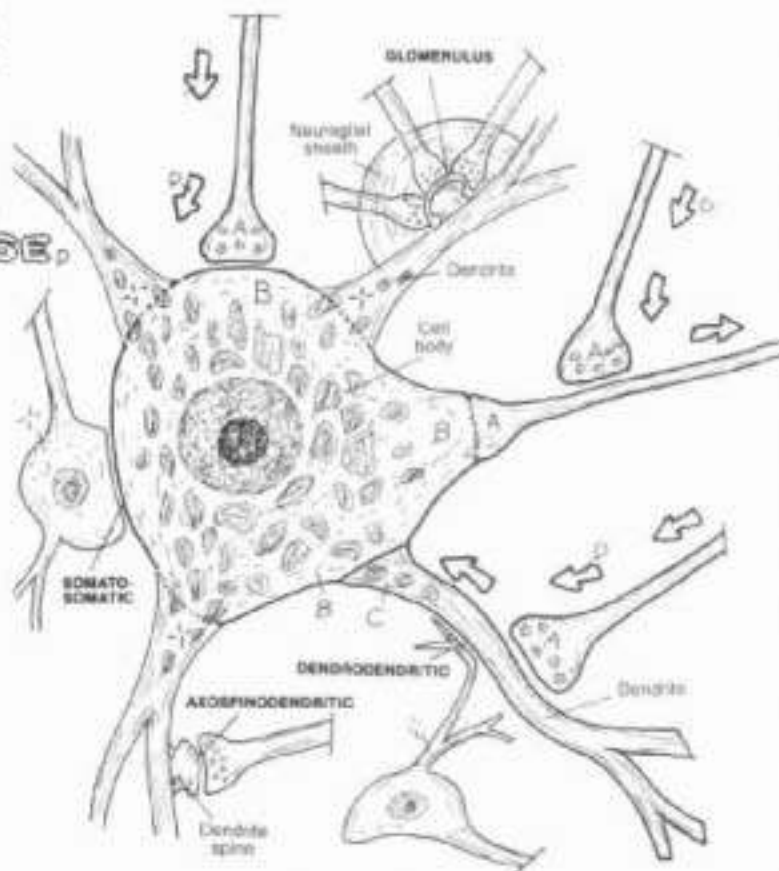
CN: Use light colors for A, B, and C (1) in the upper drawing, each of the synapses shown has two parts. Color only the ones labeled with subscripts (A, B, C). Color the nerve impulse (D) and the related directional arrows. (2) Color the numbered steps in the lower drawing. Note the change of color in the presynaptic membrane between exocytosis (H) and endocytosis (K).

### BASIC TYPES OF SYNAPSES:

- AXO-AXONIC
- AXO-SOMATIC
- AXO-DENDRITIC

Connections between and among neurons are called synapses. They are, for the most part, non-contact, chemical transmissions between one part of a neuron and another. There are other less common types of synapses (some of which are not shown) as well. For example, we show a complex of synapses between three axons and a dendrite, all surrounded by a neuroglial sheath (glomerulus). Synapses permit the conduction of electrochemical impulses among a myriad of neurons almost instantly. In the simplest example, a monosynaptic reflex arc between a sensory neuron and a motor neuron requires one synapse. At the other extreme, there are polysynaptic pathways in the brain and spinal cord involving millions of synapses. Certain neurons are known to receive more than 5000 synapses each! Multiple synapses greatly increase the available options of nervous activity. The ability to integrate, coordinate, associate, and modify sensory input and memory to achieve a desired motor command is directly related to the number of synapses involved in the pathway.

NERVE IMPULSE,

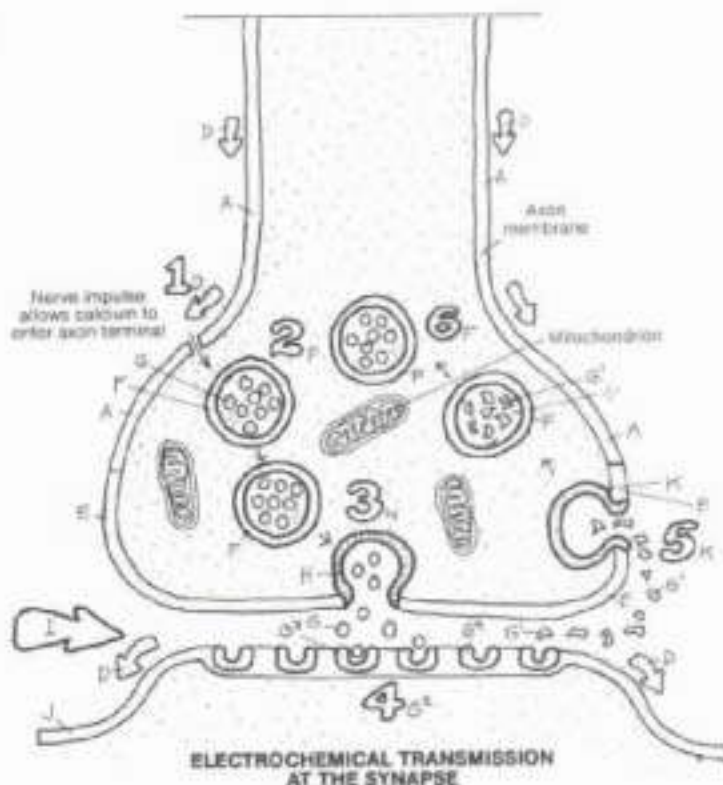


TYPES OF SYNAPSES

### TYPICAL SYNAPSE:

- PRESYNAPTIC AXON
- PRESYNAPTIC MEMBRANE
- SYNAPTIC VESICLE
- NEUROTRANSMITTER
- FRAGMENT
- EXOCYTOSIS
- SYNAPTIC GLETT
- POSTSYNAPTIC MEMBRANE
- RECEPTOR
- ENDOCYTOSIS

Here we present a typical axo-dendritic synapse. The axon (1) is presynaptic (in front of the synapse). Within the cytoplasm of the axon terminal are synaptic vesicles (2) transporting molecules of neurotransmitter. These vesicles migrate toward and fuse with the presynaptic membrane (3). Neurotransmitter is spilled into the tiny synaptic cleft by a process of exocytosis. The neurotransmitter molecules interact with the receptors on the postsynaptic membrane of the postsynaptic dendrite (4). Inactivated neurotransmitter fragments are taken up by the presynaptic membrane (5; endocytosis), enclosed in a synaptic vesicle, and re-synthesized (6). The neurotransmitter may enhance (facilitate) or depress (inhibit) the electrical activity of the postsynaptic membrane. Sufficiently excited by multiple facilitatory synapses, the postsynaptic neuron will depolarize and transmit an impulse to the next neuron or effector; sufficiently inhibited by multiple inhibitory synapses, the postsynaptic neuron will not be depolarized and will not transmit an impulse. All of this occurs very rapidly and globally throughout the nervous system.



ELECTROCHEMICAL TRANSMISSION AT THE SYNAPSE

# KIV. NERVOUS SYSTEM

## DEVELOPMENT OF CENTRAL NERVOUS SYSTEM

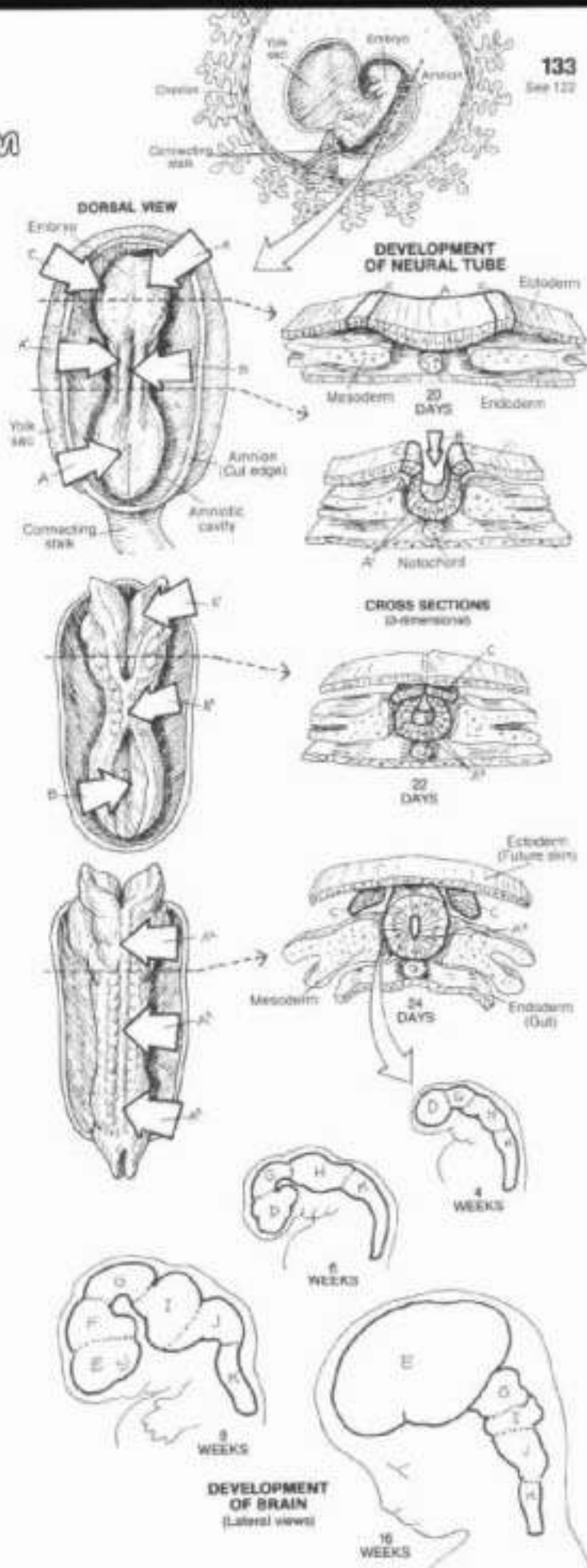
CH. Use light colors for A and C. (1) Begin with the two dorsal views of the 20-day embryo. Color as well the large arrows pointing to the surface locations. Simultaneously color the diagrammatic cross section to its right. Follow the same procedure for the later views of the growing embryo. (2) Color the stages of brain development in the head end of the neural tube.

### NEURAL PLATE, FOLD, TUBE, NEURAL GROOVE: NEURAL CREST.

The nervous system develops from the dorsal surface of the ectodermal germ layer (future skin) of the embryo. In the 20-21 day embryo, a longitudinal groove (neural groove) begins to form on the thickened layer (neural plate). In the central part of the plate, the groove deepens, forming neural folds on either side. Deepening of the neural groove proceeds toward the head and tail ends of the embryo. By 22 days, the dorsal part of the folds fuse in the central part of the groove, forming a neural tube. During this process, the neural tube separates from the ectoderm. By 24 days, formation of the neural tube has progressed to the extreme ends of the embryo. Much of the neural tube will form the spinal cord; the head end of the tube will form the brain. The neural crest cells, formed from the neural folds, will develop into certain nerve cells of the peripheral nervous system and Schwann cells. The surrounding mesoderm will form the cranium and the vertebral column and related muscles. The notochord (a primitive supporting rod for the embryo) will be absorbed by the developing vertebral column, and remnants of it will remain as the core of the intervertebral discs (nucleus pulposus). The endoderm will contribute to the development of the digestive tract.

### FOREBRAIN: TELENCEPHALON, DIENCEPHALON, MIDBRAIN (MESENCEPHALON), HINDBRAIN: METENCEPHALON, MYELENCEPHALON, SPINAL CORD.

By the end of three weeks of embryonic development, three regions of the developing brain are apparent: forebrain, midbrain, and hindbrain. With further growth, the forebrain expands to form the massive telencephalon (endbrain; future cerebral hemispheres) and the more central diencephalon ("between" brain; future top of the brain stem). The midbrain retains its largely tubular shape as the mesencephalon (midbrain; future upper brain stem). The hindbrain differentiates into the upper metencephalon ("change" brain; future middle brain stem) and a large dorsal outpocketing (future cerebellum), and the lower myelencephalon (spinal brain; lowest part of the future brain stem). The brain stem narrows to become the spinal cord at the level of the foramen magnum of the skull.

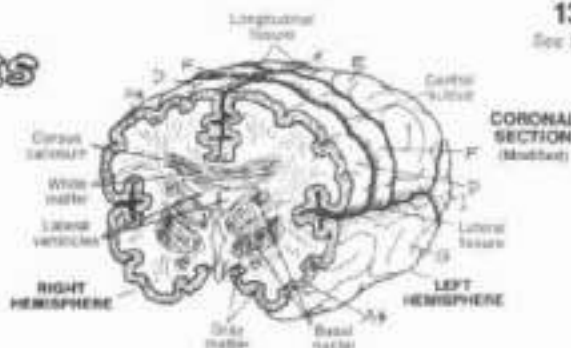




# XIV. NERVOUS SYSTEM

## CNS: CEREBRAL HEMISPHERES

CN. Use light colors for B, E, I, and J. (1) Color the two large hemispheres first. Note that the stippled areas of specialized function are parts of lobes, but receive their own colors. Color the areas identifying the major fissures and sulci. (2) Color the coronal section and posterior portion of the brain. The coronal section of the cerebral cortex is colored gray. (3) Color gray the stretched-out cortex and the convoluted cortex illustrating how the latter provides increased surface area in a smaller space.



### CEREBRAL CORTEX: A+

#### FRONTAL LOBE:

PRINCIPAL SPEECH AREA:  
PRIMARY MOTOR AREA  
(PRECENTRAL GYRUS)

#### PARIETAL LOBE:

PRIMARY SENSORY AREA  
(POSTCENTRAL GYRUS)

#### TEMPORAL LOBE:

AUDITORY AREA

#### OCCIPITAL LOBE:

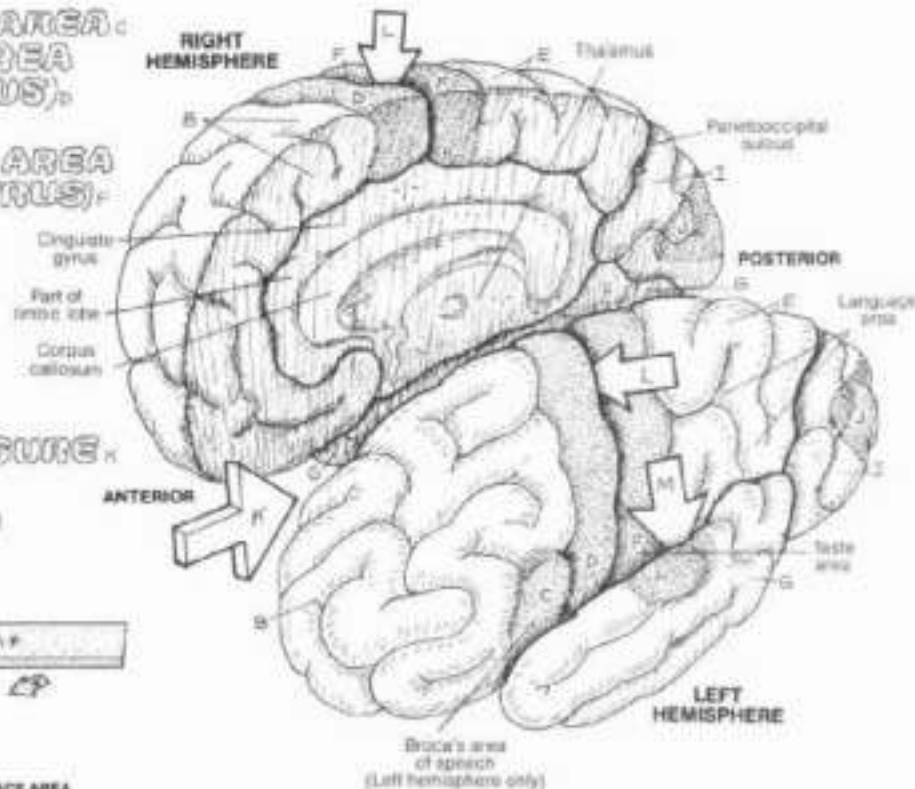
VISUAL AREA

#### MAJOR FISSURES/ SULCUS:

LONGITUDINAL FISSURE

CENTRAL SULCUS

LATERAL FISSURE



CORTICAL CONVOLUTIONS: INCREASED SURFACE AREA

The paired cerebral hemispheres (cerebrum), derivatives of the embryonic telencephalon, consist of four major elements: (1) an outer cerebral cortex of gray matter, the topography of which reveals fissures (deep grooves), gyr (hills), and sulci (furrows); (2) underlying white matter consisting of numerous tracts destined for or leaving the cortex and oriented along three general directions; (3) discrete masses of gray matter at the base of the cerebrum (basal nuclei) that subserve motor areas of the cortex; (4) paired cavities called lateral ventricles. The cerebral cortex is the most highly evolved area of the brain. About 2-4 mm (roughly 1/8 inch) thick, the cortex is divided into lobes distinctly bordered by sulci; the lobes are generally related to the cranial bones that cover them: frontal, parietal, temporal, occipital. The exception is the limbic lobe (part of which is shown); it incorporates parts of other (frontal, temporal, parietal) lobes.

Cortical mapping experiments (based on electrical stimulation) and clinical/pathologic data have been the principal methods by which functions of the cortex have been discovered. All parts of the cortex are concerned with storage of experience (memory), exchange of impulses with other cortical areas (association), and the two-way transmission of impulses with subcortical areas (afferent/efferent projections).

The frontal lobe is concerned with intellectual functions such as reasoning and abstract thinking, aggression, sexual behavior, olfaction or smell, articulation of meaningful sound (speech), and voluntary move-

ment (precentral gyrus). The central sulcus separates the frontal lobe from the parietal lobe. The parietal lobe is concerned with body sensory awareness, including taste (postcentral gyrus), the use of symbols for communication (language), abstract reasoning (e.g., mathematics), and body imaging. The temporal lobe is partly limbic and here is concerned with the formation of emotions (love, anger, aggression, compulsion, sexual behavior); the non-limbic temporal lobe is concerned with interpretation of language, awareness and discrimination of sound (hearing; auditory area), and constitutes a major memory processing area. The occipital lobe is concerned with receiving, interpreting, and discriminating visual stimuli from the optic tract, and associating those visual impulses with other cortical areas (e.g., memory).

In evolutionary terms, the limbic lobe or system is the oldest part of the cortex; it is the center of emotional behavior. The limbic neurons occupy parts of the inferior and medial cortices of each hemisphere, and some subcortical areas as well. Certain limbic areas are closely related topographically to the olfactory tracts.

The cerebral hemispheres appear structurally as mirror images of one another; functionally they are not. The speech area develops fully only on one side, usually the left. In general, the left hemisphere tends to deal with certain higher functions (mathematical, analytical, verbal) while the right concentrates on visual, spatial, and musical orientations. The matter of cerebral "dominance" (left hemisphere, left speech center, right handed) or vice versa is quite controversial.



# XIV. NERVOUS SYSTEM

## CNS: TRACTS/NUCLEI OF CEREBRAL HEMISPHERES

Ch: Use very light colors for F and G. (1) Color gray the various sections of cerebral cortex without coloring the cortical surfaces. (2) Among the many views shown, color each structure whenever it appears before going on to the next title/structure.

### CEREBRAL CORTEX<sup>A\*</sup>

### SUBCORTICAL AREAS:

#### BASAL NUCLEI:

CAUDATE NUCLEUS.

LENTICULAR NUCLEUS.

#### LATERAL VENTRICLE.

#### WHITE MATTER TRACTS:

#### COMMISSURES:

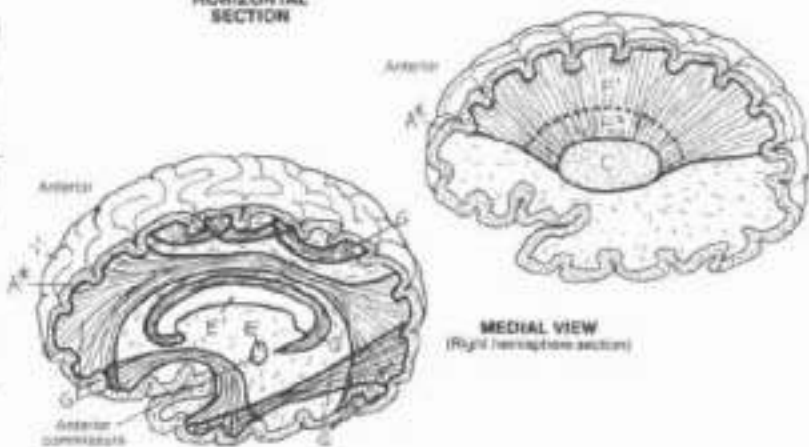
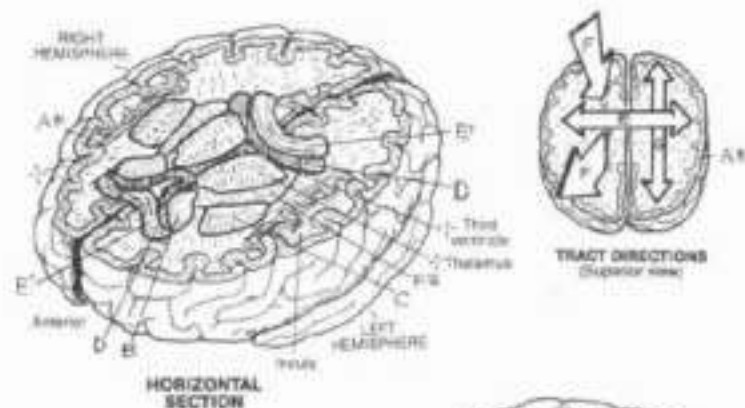
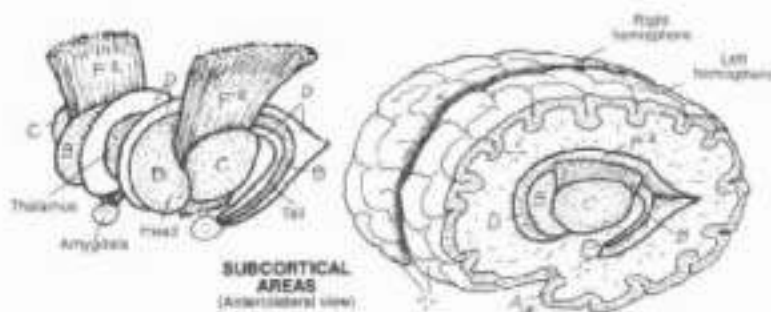
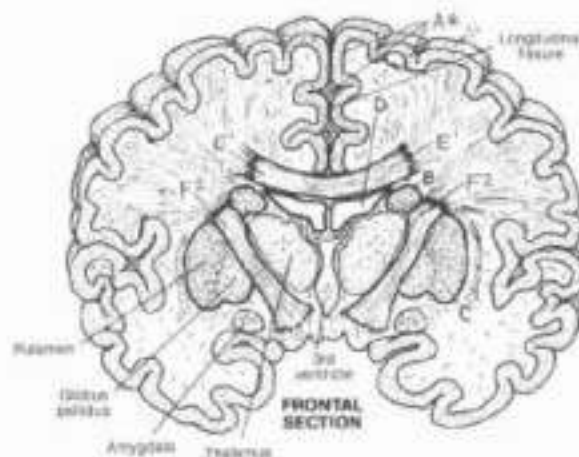
CORPUS CALLOSUM<sup>E</sup>

#### PROJECTION TRACTS:

CORONA RADIATA<sup>F</sup>

INTERNAL CAPSULE<sup>F\*</sup>

#### ASSOCIATION TRACTS.



The subcortical areas of the cerebral hemispheres include the white matter below the cortex, the basal ganglia (nuclei), and the lateral ventricles.

The basal nuclei are discrete islands of gray matter amidst a sea of white matter at the base of the hemispheres on either side of and above the diencephalon (see next plate). The major basal nuclei are the caudate nucleus and the lenticular nucleus. Both are named according to their shape: the caudate, when viewed laterally, appears to have a head and a progressively narrowing and curving tail (cauda, tail) ending at the amygdala (a nucleus of the limbic system). The lenticular nucleus is arguably lens-shaped. The basal ganglia have connections with the cerebral cortex, the thalamus, and nuclei near the thalamus. The basal ganglia are involved in the planning, initiation, maintenance, and termination of movement (motor activity). They monitor and mediate descending commands from the motor cortex. They are instrumental centers in maintaining muscle tone and programming sequential postural movements and adjustments.

Their influence is manifested as appropriately gated impulses influencing the lower motor neurons of the cranial and spinal nerves in their innervation of skeletal muscle. Diseases of the basal ganglia include dystonias and dyskinesias and, perhaps most well known of all, Parkinson's disease (abnormal gait, rigidity, tremors).

The white matter of the hemispheres consists of tracts oriented in six general directions. Tracts connecting left and right hemispheres are called commissures, of which the largest is the corpus callosum. This massive tract spans the two hemispheres, roofing over the lateral ventricles. It makes possible communications between centers in the paired hemispheres. Bundles of white matter, both long and short, connecting anterior and posterior cortical areas, are called association tracts. An emotional response to a visual stimulus is made possible, in part, by association tracts.

Perhaps the most spectacular mass of white matter in the brain is that projection tract of myelinated axons (the corona radiata) radiating from the level of the basal ganglia to and from all parts of the cortex. It is continuous inferiorly with the compact band of fibers (internal capsule) passing between and partly encapsulating the two basal nuclei. All motor commands are conducted here; all sensory input reaching the cortex passes through these fibers. Very importantly, the thalamus and cortex communicate by this pathway.

# XIV. NERVOUS SYSTEM

## CNS: DIENCEPHALON

CN. Use light colors for A and B, and a very bright color for C. (1) Color each structure wherever it appears before going on to the next slide. (2) Although not colored, the neighboring relations of the diencephalon to adjacent structures are important and have been identified by name. These should be given special attention.

### DIENCEPHALON: THALAMUS, HYPOTHALAMUS, EPITHALAMUS (PINEAL GLAND), THIRD VENTRICLE.

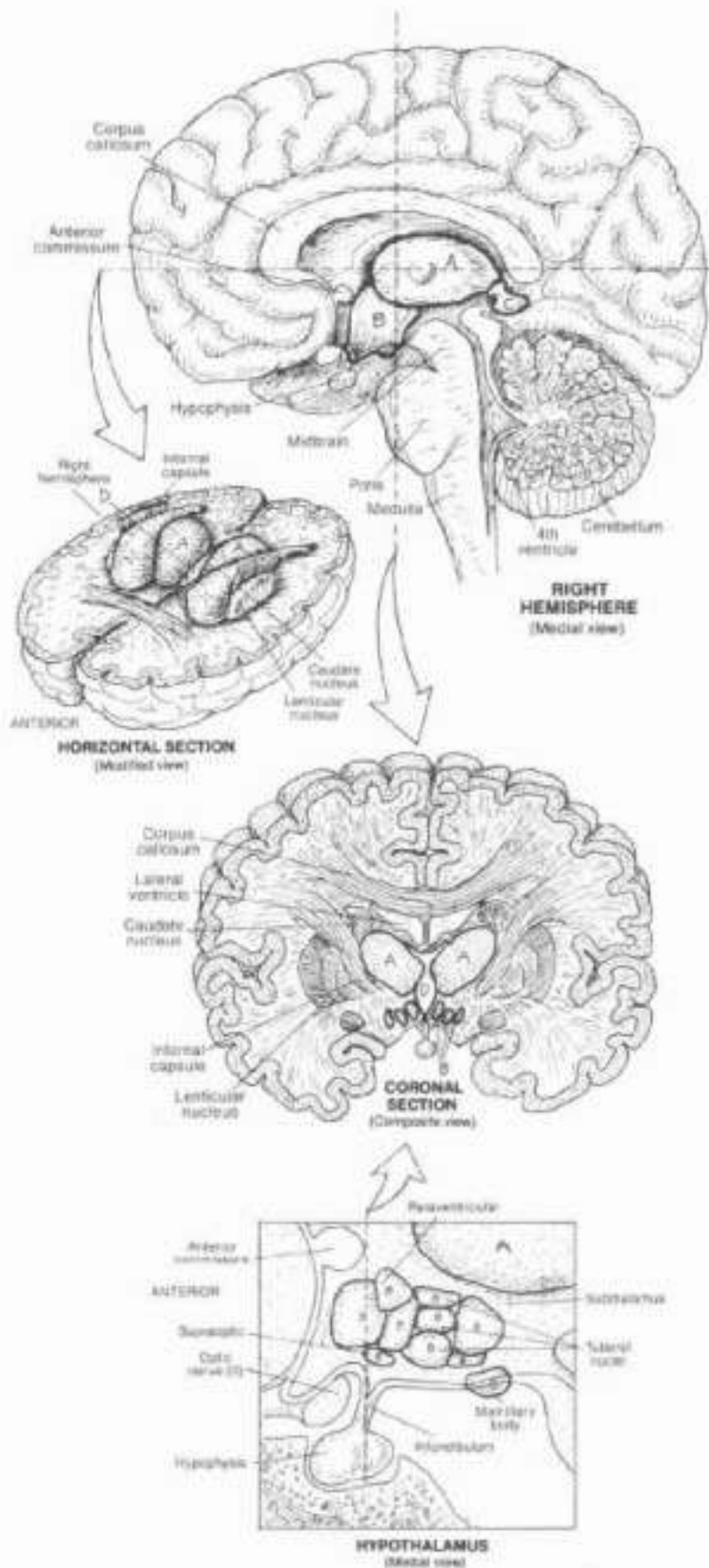
The diencephalon, the smaller of the two derivatives of the early forebrain, lies between (or between) but is not part of the massive, surrounding cerebral hemispheres.

It consists of masses of nuclei at the top of (and indeed is part of) the brain stem. The diencephalic structures are paired and are arranged around the third (or) ventricle and its infundibular recess. On each side, the diencephalon consists of the thalamus and the subthalamus inferior to it, the hypothalamus embracing the infundibular recess of the third ventricle, and the epithalamus or pineal gland suspended from the posterior wall of the third ventricle. The structural relationship of these structures to the whole matter of the cerebrum, the third ventricle, the basal ganglia, and the midbrain should be carefully studied to ensure orientation.

The thalamus consists of several groups of cell bodies and processes that, in part, process all incoming impulses from sensory pathways (except olfactory). It has broad connections with the motor, general sensory, visual, auditory, and association cortices. Not surprisingly, the corticothalamic (cortex to thalamus) fibers contribute significantly to the corona radiata. Still other thalamic nuclei connect to the hypothalamus and other brain-stem nuclei. Thalamic activity (1) integrates sensory experiences resulting in appropriate motor responses, (2) integrates specific sensory input with emotional (motor) responses (e.g., a baby crying in response to hunger), and (3) regulates and maintains the conscious state (awareness), subject to facilitating/inhibiting influences from the cortex. Subthalamic nuclei are concerned with motor activity and have connections with the basal ganglia.

The hypothalamus consists of nuclear masses and associated tracts on either side of the lower third ventricle. The hypothalamus maintains neuronal connections with the frontal and temporal cortices, thalamus, neurohypophysis, and brainstem. Its neurosecretions (hormones) are also directed to the adenohypophysis via the hypophysial portal system. In addition, the hypothalamus is concerned with emotional behavior, regulation of the autonomic (visceral) nervous system and related integration of visceral (autonomic) reflexes with emotional reactions, activation of the drive to eat (hunger) and the subsequent feeling of satisfaction (satiety) following fulfillment of that drive. Finally, it mediates descending impulses related to both reflexive and skilled movements. All of this in an area the size of four peas!

The epithalamus (pineal gland) consists primarily of the pineal body and related nuclei and tracts that have connections with the thalamus, hypothalamus, basal nuclei, and the medial temporal cortex. It produces melatonin (a pigment-enhancing hormone), the synthesis of which is related to diurnal cycles or rhythms (body activity in day or sunlight as opposed to dark or nocturnal periods). It may influence the onset of puberty through inhibition of testicular/ovarian function. Remarkably, the pineal is the only unpaired structure in the brain.



# XIV. NERVOUS SYSTEM

## CNS: BRAIN STEM / CEREBELLUM

Ch. Use darker colors for C, E, M, and the lightest for K. (1) As you color each structure in as many colors as it is shown, take particular note of the orientation of the view. (2) Note that the fourth ventricle is located in both parts of the hindbrain and receives the same color in both parts. The diencephalon has been presented on the previous plate and is shown here only for orientation.

### DIENCEPHALON

#### MIDBRAIN:

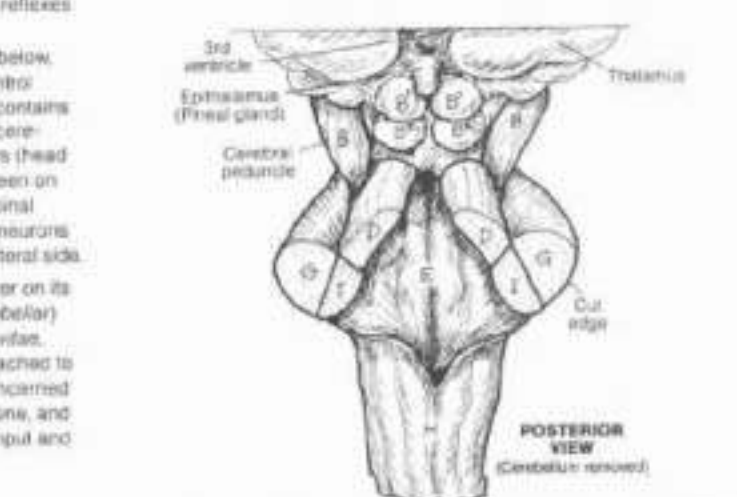
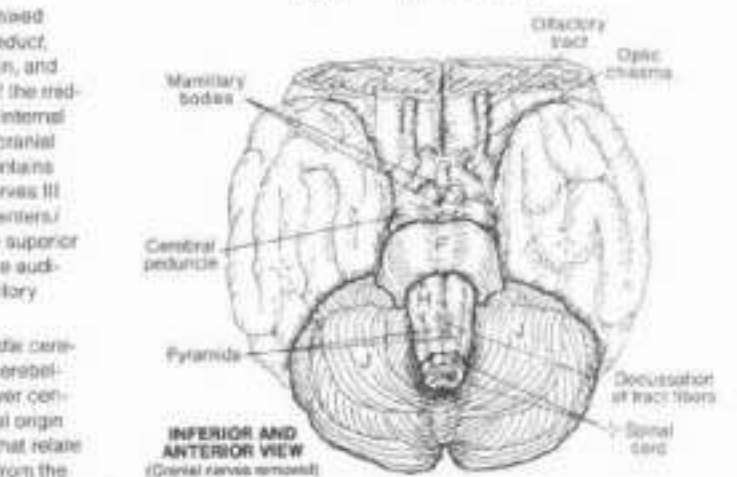
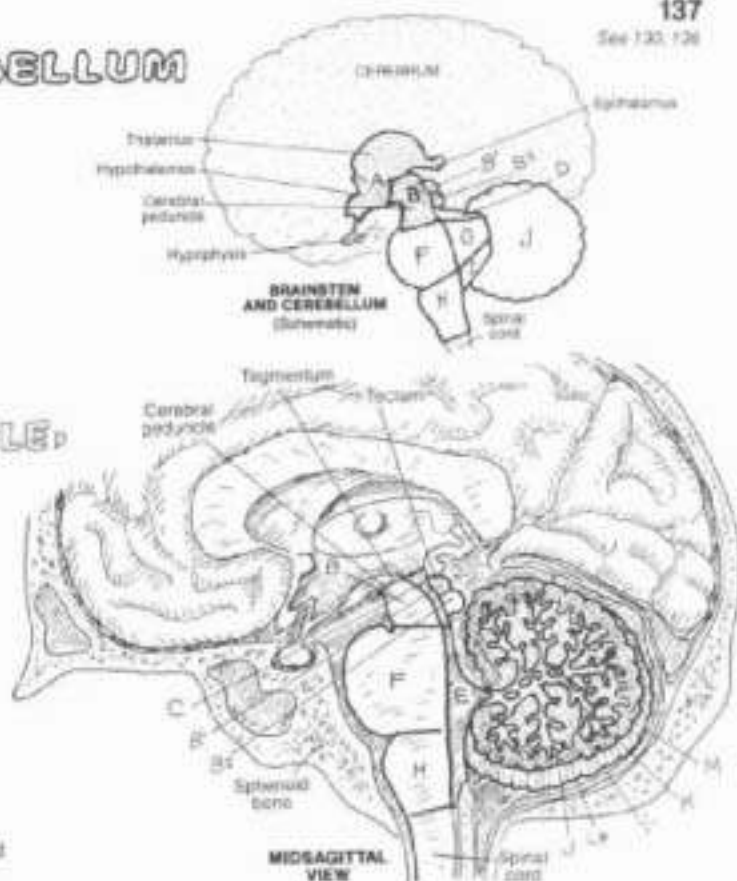
- CEREBRAL AQUEDUCT,
- SUPERIOR COLLICULUS,
- INFERIOR COLLICULUS,
- SUP. CEREBELLAR PEDUNCLE,

#### HINDBRAIN:

- 4TH VENTRICLE,
- pons,
- MID. CEREBELL. PED.,
- MEDULLA,
- INF. CEREBELL. PED.,

### CEREBELLUM

- ARBOR VITAE,
- CEREBELLAR CORTEX,
- DEEP CEREB. NUCLEUS



The brainstem consists of all portions of the brain less the cerebrum and cerebellum.

The midbrain includes two columns of tracts (cerebral peduncles) and mixed nuclei/tracts posterior to these columns (tectum), the cerebral aqueduct, superior cerebellar peduncles (conducting tracts from thalamus, midbrain, and medulla), and the more posterior superior and inferior colliculi (tectum of the midbrain). The peduncles consist of descending axons continuous with the internal capsule above and destined for lower motor neurons in the brain stem (cranial nerve) and spinal cord (spinal nerves) below. The deeper tectum contains nuclei of the reticular formation, nuclei/tracts concerned with cranial nerves III and IV, relay of impulses between lower and higher centers, and other centers/tracts concerned with somatic and visceral motor-related impulses. The superior colliculi are centers for visual reflexes; the inferior colliculi make possible auditory reflexes (e.g., involuntary movements in response to visual and auditory stimuli, respectively).

The upper hindbrain is the pons. Massive stalks of white matter, the middle cerebellar peduncles, cross the fourth ventricle (pons, bridge) to reach the cerebellum. The pons consists of (1) tracts descending from the midbrain to lower centers; (2) masses of cell bodies that synapse with certain tracts of cortical origin and whose axons constitute the middle cerebellar peduncle; (3) nuclei that relate to cranial nerves V, VI, VII, and VIII; (4) several ascending tracts arising from the medulla and spinal cord; and (5) a network of polysynaptic neurons (part of the reticular formation) that facilitate/inhibit (mediate) somatic and visceral reflexes and form a mechanism for arousal, wakefulness, and alertness.

The medulla, continuous with the deep pons above and the spinal cord below, consists of much the same organization as the pons. Life-sustaining control centers for respiration, heart rate, and vasomotor function exist here. It contains nuclei concerned with cranial nerves VII, IX, X, XI, and XII. The inferior cerebellar peduncle carries tracts from the spinal cord and vestibular centers (head balance) in the medulla. Two particularly evident bundles of fibers are seen on the anterior surface of the medulla. These pyramids consist of corticospinal fibers conducting voluntary movement-related impulses to lower motor neurons of the spinal cord. 80% of these fibers cross (decussate) to the contralateral side.

The cerebellum consists of two hemispheres, with a cortex of gray matter on its surface (cerebellar cortex), central masses of motor-related (deep cerebellar) nuclei, and bands of white matter forming a tree-like appearance (arbor vitae, tree of life) when the cerebellum is cut in section. The cerebellum is attached to the brain stem by the three cerebellar peduncles. The cerebellum is concerned with equilibrium and position sense, fine movement, control of muscle tone, and overall coordination of muscular activity in response to proprioceptive input and descending traffic from higher centers.



# XIV. NERVOUS SYSTEM

## CNS: SPINAL CORD

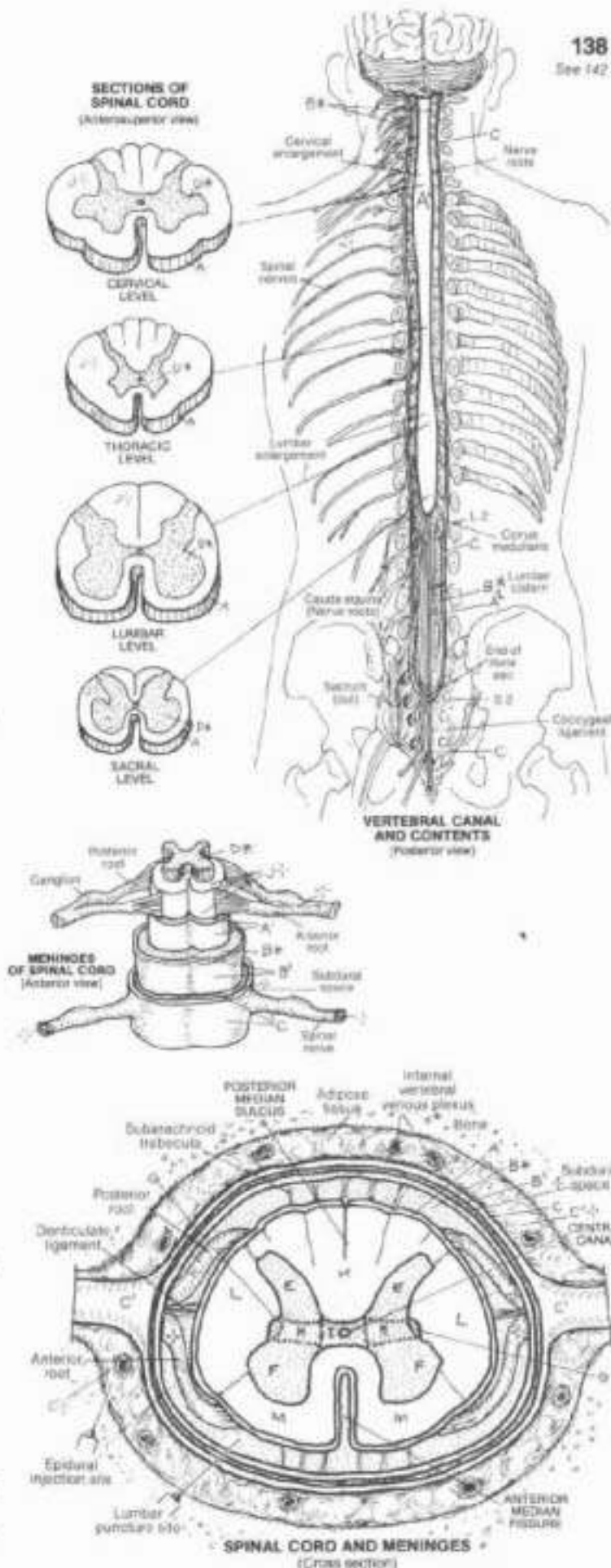
**CR:** Use bright colors for A-C (except where indicated by asterisk) or no-color symbols (-); Use medium dark colors for D-I, and light colors for K-M. (1) In the upper drawing, color B\* gray over the nerve roots within the dura mater and outside the spinal cord. (2) Color the cone sections taken at various levels. (3) Color the meninges or the spinal cord. What is not shown (therapist at site) (meninges) is the presence of the pia mater, subarachnoid space, and arachnoid around the nerve roots. (4) Do not color the structures within the subarachnoid space or the central canal in the drawing of the bottom of the plate.

- SPINAL CORD:**
- MENINGES:**
- PIA MATER:**
- FILUM TERMINALE\***
- SUBARACHNOID SPACE,\*\***
- ARACHNOID\***
- DURA MATER:**
- EPIDURAL SPACE**

The spinal cord begins at the foramen magnum of the skull and ends as the conus medullaris at a vertebral level of L1 or L2. It bulges slightly in the lower cervical and lumbar regions (enlargements) in relation to the presence of large numbers of axons associated with the upper and lower limbs. Enclosed in coverings called meninges, the spinal cord is awash in cerebrospinal fluid (CSF) within the subarachnoid space. The spinal meninges and related spaces include, from inner to outer: a thin, vascular pia mater that ensheathes the cord and nerve rootlets/roots, and continues inferiorly from the conus as the filum terminale to join the dura mater at the 2nd sacral vertebra (S2); a significant CSF-containing subarachnoid space surrounding cord and nerve roots, whose largest portion is the lumbar cistern from L2 to the end of the dural sac at S2, filled with nerve roots (cauda equina); a thin arachnoid, the consistency of which is similar to a dense spider's web; a potential subdural space; and the tough, protective, fibrous dura mater (the dural sac). Between the dura and the ligament-covered, periosteum-lined vertebral bones/intervertebral discs is the fat-filled epidural space containing a plexus of veins.

- GRAY MATTER:**
- POSTERIOR HORN:**
- ANTERIOR HORN:**
- LATERAL HORN (T1-L2):**
- INTERMEDIATE ZONE\***
- GRAY COMMISSURE:**
- WHITE MATTER:**
- POSTERIOR FUNICULUS:**
- LATERAL FUNICULUS:**
- ANTERIOR FUNICULUS**

The spinal cord consists of a central mass of gray matter arranged into the form of an H and a peripheral array of white matter (funiculus) consisting of descending and ascending tracts. The amount of white matter decreases as the cord progresses distally, seen especially well in the sacro-coccygeal region. The gray posterior horns (actually columns when seen in three dimensions) receive the central processes of sensory neurons (recall Plate 131) and direct incoming impulses to the adjacent white matter for conduction to other cord levels or higher centers. The anterior horns include lower motor neurons that represent the "final common pathway" for motor commands to muscle. Lateral horns exist only in the thoracic and upper lumbar cord and include autonomic motor neurons supplying smooth muscle (in vessels and viscera) and glands. It is in the gray matter that spinal reflexes occur in conjunction with facilitatory and inhibitory influences from higher centers.

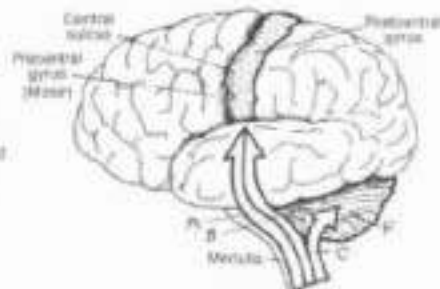


SPINAL CORD AND MENINGES (Cross section)

# XIV. NERVOUS SYSTEM

## CNS: ASCENDING TRACTS

**ON** Use bright colors for A-C and a light color for F (1) Color the pain/temperature pathway which is shown on one side only for visual simplicity. Note that the sensory cortex and the thalamus are to be colored gray. (2) In the muscle stretch/position sense pathways, note there are two different cerebellar peduncles, each receiving a different color.

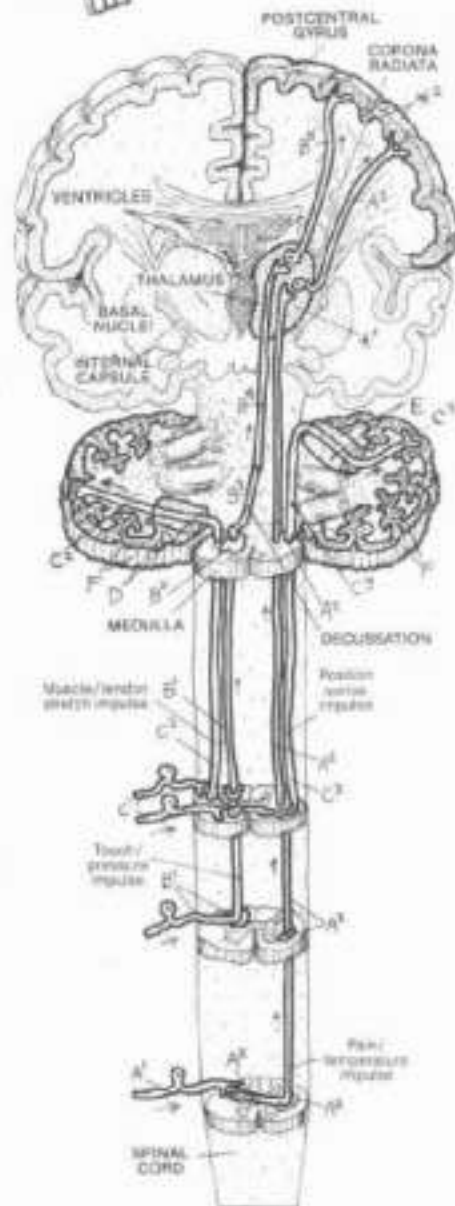
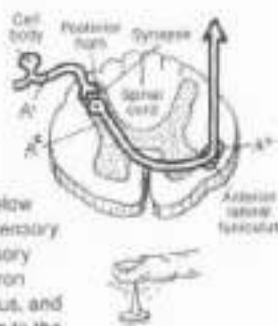


Ascending pathways consist of linearly arranged neurons, the axons of which travel in a common bundle (tract) conducting impulses toward the thalamus, cerebral cortex, or cerebellum. In the examples shown here, each of the pathways begins with a sensory neuron. These sensory pathways permit body surface sensations and muscle/tendon stretch information (below the head) to reach brain stem and cerebellar centers for response and cortical centers for awareness.

### PAIN/TEMPERATURE: A

- SENSORY NEURON<sup>A</sup>
- LAT. SPINOTHALAMIC TRACT<sup>A</sup>
- THALAMUS<sup>A</sup>
- THALAMOCORTICAL TRACT<sup>A</sup>
- SENSORY CORTIX<sup>A</sup>

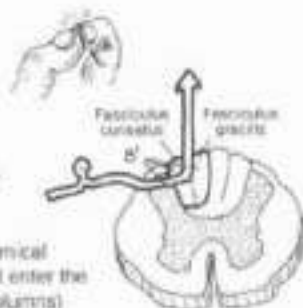
Pain and temperature receptors on the body surface and elsewhere below the head generate impulses that travel to the spinal cord by axons of sensory neurons (1st order neuron). The central process ("axon") of each sensory neuron enters the posterior horn and synapses with the 2nd order neuron whose axon crosses to the contralateral side, enters the lateral funiculus, and ascends as part of the lateral spinothalamic tract. This neuron ascends to the thalamus where it synapses with relay (3rd order) neurons, the axons of which traverse the internal capsule and corona radiata (thalamocortical tract) to reach the postcentral gyrus of the cerebral cortex ("sensory cortex").



### TOUCH/PRESSURE: B

- SENSORY NEURON:
- N. GLOVEATUS & GRACILIS<sup>B</sup>
- INT. ARCULATE FIBERS<sup>B</sup>
- MED. LEMNISCUS<sup>B</sup>
- THALAMUS<sup>B</sup>
- THALAMOCORTICAL TRACT<sup>B</sup>
- SENSORY CORTIX<sup>B</sup>

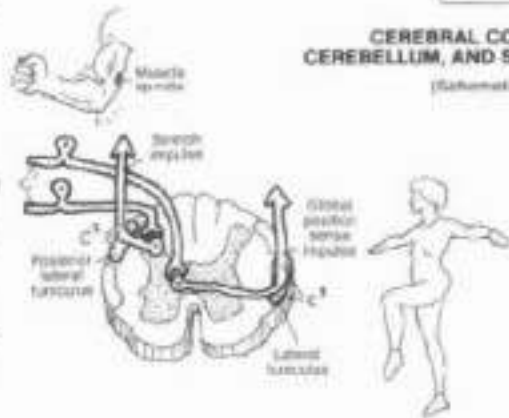
Touch and pressure receptors below the head generate electrochemical impulses that travel to the spinal cord through sensory neurons that enter the posterior horn and join/ascend the posterior funiculus (posterior columns) to the medulla. Here they synapse with 2nd order neurons in the nuclei cuneatus and gracilis. The axons of these neurons sweep to the opposite side (as internal arcuate fibers) to form an ascending bundle (medial lemniscus) in the brain stem that terminates in the thalamus. There these axons synapse with 3rd order relay neurons whose axons reach the postcentral gyrus of the cerebral cortex via the thalamocortical tract.



### MUSCLE STRETCH / POSITION SENSE: C

- SENSORY NEURON:
- POST. SPINOCEREBELLAR TRACT<sup>C</sup>
- INF. CEREBELLAR PED.<sup>C</sup>
- ANT. SPINOCEREBELLAR TR.<sup>C</sup>
- SUP. CEREBELLAR PED.<sup>C</sup>
- CEREBELLAR CORTIX<sup>C</sup>

Impulses from muscle spindles and other proprioceptors (receptors responsive to muscle stretch/loads) are conducted by sensory neurons to the spinal cord. Single receptor input is conducted by 2nd order neurons that ascend the ipsilateral lateral funiculus (posterior spinocerebellar tract) and enter the cerebellum via the inferior cerebellar peduncle. More global proprioceptive input ascends the contralateral anterior spinocerebellar tract and enters the cerebellum via the superior cerebellar peduncle. By these and similar pathways that function in the absence of awareness, the cerebellum maintains an ongoing assessment of body position, muscle tension, muscle overuse, and movement. In turn, it mediates descending impulses from cortical and sub-cortical centers destined for motor neurons.





# KIV. NERVOUS SYSTEM

## CNS: DESCENDING TRACTS

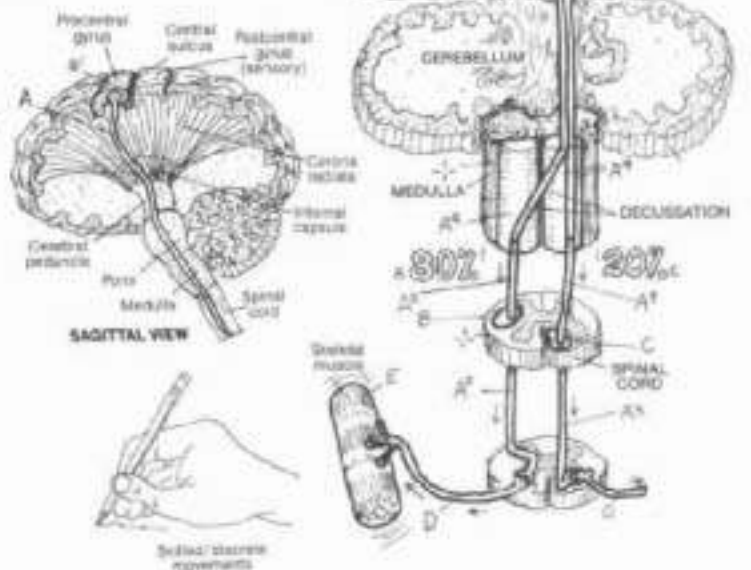
CN. Use light colors for H, I, and K. (1) Color the pyramidal tract in the sagittal view. (2) Color the pyramidal tract in the schematic coronal section at upper right, including the percentage figures. (3) Color the extrapyramidal system.

### PYRAMIDAL TRACT / RELATED AREAS:

- MOTOR CORTEX\*
- CORTICOSPINAL TRACT\*
- LAT. C. / ANT. CORTICOSPINAL TRACT\*
- MEDULLARY PYRAMID\*
- LATERAL FUNICULUS\*
- ANTERIOR FUNICULUS\*
- FINAL COMMON PATHWAY:\*
- LOWER MOTOR NEURON\*
- EFFECTOR\*

Voluntary movement is initiated in the motor cortex (precentral gyrus) on the opposite side where the movement is desired. The axons of the cortical motor neurons (upper motor neurons) descend the corona radiata, the internal capsule, the cerebral peduncles, and the pons—without synapse—as the corticospinal tract. In the medulla, these axons form the anterior swellings called the pyramids (thus, pyramidal tract). Here at the decussation of the pyramids, about 80% of the fibers cross to the opposite side and enter the lateral funiculus. These fibers—and the uncrossed fibers on the same side—form the lateral corticospinal tract. The axons of the pyramidal tract leave the funiculus at one of many spinal levels to synapse with the anterior horn (lower) motor neurons.

PYRAMIDAL TRACT (Schematic)

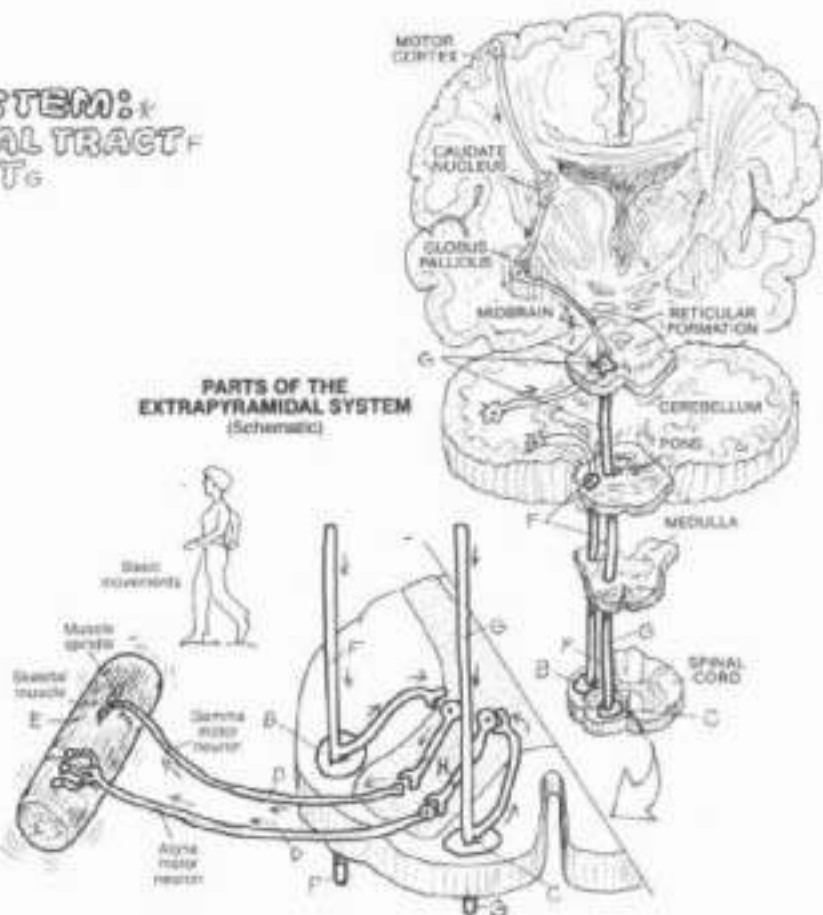


### EXTRAPYRAMIDAL SYSTEM:

- PONTINE RETICULOSPINAL TRACT\*
- VESTIBULOSPINAL TRACT\*
- INTERNEURON\*

The desired corticospinal-actuated command to the lower motor neuron is not influenced by body position, memory, and a host of other factors necessary to achieve the desired movement at the required moment. These collective inputs from the cerebral cortex, basal nuclei, cerebellum and elsewhere, arrive at the appropriate lower motor neurons by a number of descending pathways, none of which pass through the medullary pyramids (hence, extrapyramidal system or tracts). Two major extrapyramidal tracts are shown here: the reticulospinal tract from the brain stem reticular nuclei; the vestibulospinal tract from the vestibular nuclei in the brain stem. Other tracts include the rubrospinal and tectospinal tracts (not shown, but see glossary). The synaptic connections of these axons with each lower motor neuron (often by way of interneurons) are in the thousands. Depending on the neurotransmitter produced by the presynaptic neuron, the synapse may facilitate or inhibit production of an excitatory impulse from the lower motor neuron. Discharge of the lower motor neuron, or not, is dependent upon the sum of the facilitatory and inhibitory impulses impinging on it at any moment. Once generated, the electrochemical impulse moving down the axon of the lower motor neuron reaches the effector without further mediation. Thus, the anterior horn motor neuron is truly the "final common pathway" for the ultimate expression of all nervous activity: muscular contraction.

PARTS OF THE EXTRAPYRAMIDAL SYSTEM (Schematic)





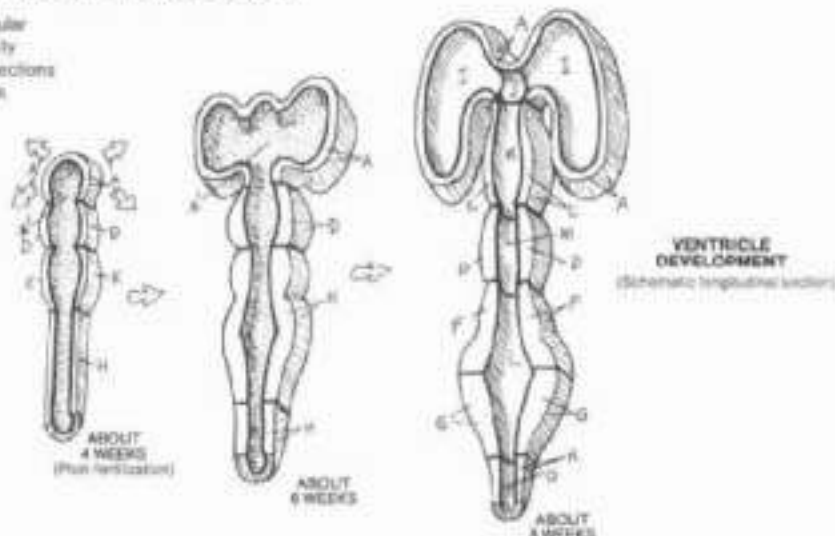
# XIV. NERVOUS SYSTEM

## CNS: VENTRICLES OF THE BRAIN

CN Use a light color for A. (1) Color the three drawings of ventricular development first. (2) Color the lateral and superior views of the fully developed ventricles. (3) Color the coronal and modified sagittal sections revealing the relationship of the ventricles to surrounding structure.

### VENTRICLE DEVELOPMENT:

- NEURAL CAVITY,
- FOUR BRAIN,
- TELENCEPHALON,
- DIENCEPHALON,
- MESENCEPHALON,
- HIND BRAIN,
- METENCEPHALON,
- MYELENCEPHALON,
- SPINAL CORD



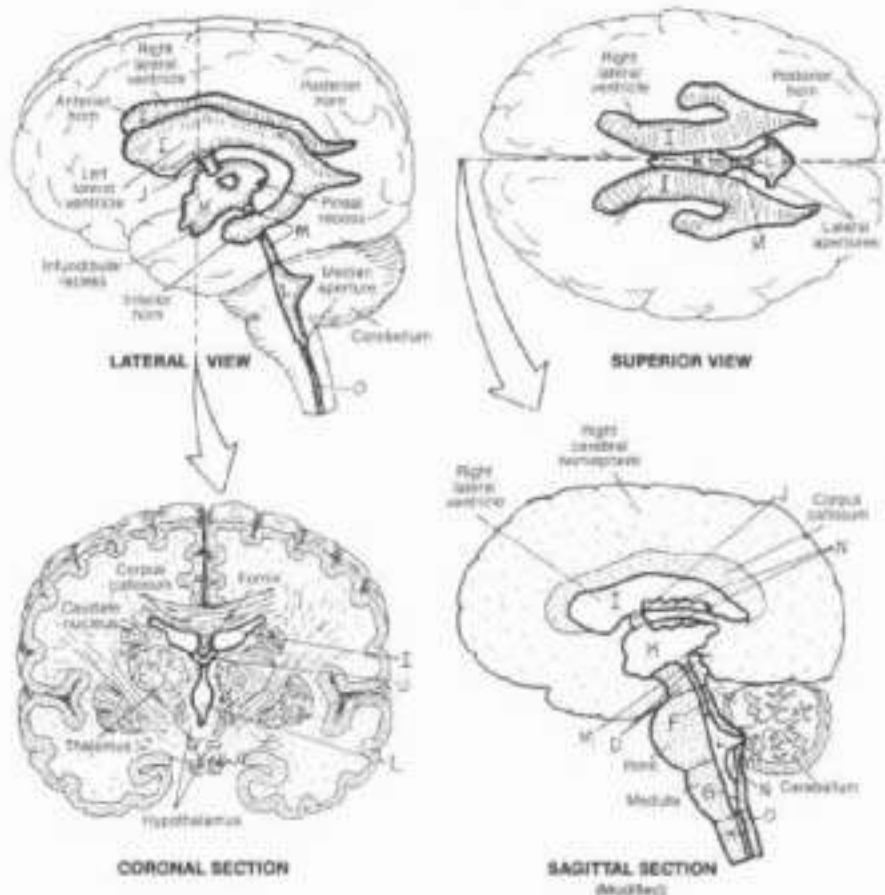
### DERIVATIVES:

- LATERAL VENTRICLE (1 & 2)
- INTERVENTRICULAR FORAMEN,
- 3RD VENTRICLE,
- 4TH VENTRICLE,
- CEREBRAL AQUEDUCT,
- CHOROID PLEXUS,
- CENTRAL CANAL.

The central nervous system develops from a hollow neural tube near the dorsal surface of the embryo. The neural cavity undergoes extraordinary revision in association with development of the brain regions. The shape of this cavity in each brain region reflects the local changes and mechanical pressures imposed by the developing brain. The ventricles may be identified by name or by roman numerals.

The cavity of the developing forebrain expands remarkably with the development of its walls into the paired cerebral hemispheres (telencephalon). These cavernous spaces will become the lateral (I, II, left to right) ventricles. Almost pinched off from these cavities and compressed to a thin, purse-like space by the enlarging hemispheres is the centrally located third (III) ventricle, connected to the lateral ventricles by small, paired inter-ventricular foramina. The derivatives of the diencephalon develop in the walls of the third ventricle. The inferior recess of this ventricle dips into the infundibulum of the hypophysis (pituitary gland); the hypothalamus develops in the walls of this recess. The pineal develops in the wall of the pineal recess. The mesencephalon undergoes the least physical change of the early brain regions, and this is reflected in the shape of the narrow, tubular cerebral aqueduct. The fourth (IV) ventricle forms in the developing hindbrain and is particularly affected by the growth of the cerebellar hemispheres into which it projects lateral recesses. The tips of these recesses open into the sub-arachnoid spaces (lateral apertures). Another opening (median aperture) is on the floor of the IV ventricle at the cerebellar level. The ventricle narrows progressively throughout the myelencephalon. At the medullary/spinal cord junction, the cavity thins to a narrow often occluded canal (central canal) in the spinal cord.

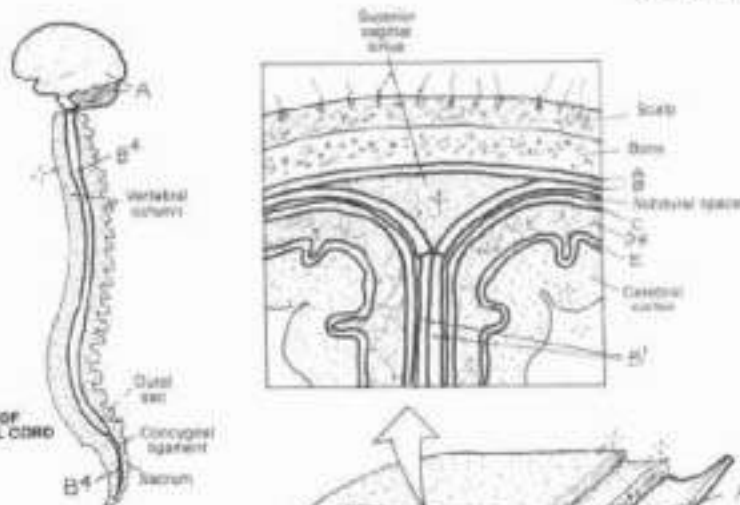
In each of the developing ventricles (cerebral aqueduct excepted) a highly vascular tissue forms from the pia mater covering the brain and the lining (ependymal) cells of the ventricles. Called choroid plexus, this tissue secretes cerebrospinal fluid or CSF (see Plate 143).



# XIV. NERVOUS SYSTEM

## CNS: MENINGES

CA. Use very light colors. (1) Begin with the diagram of the brain and spinal cord. Note that the dura mater conceals the convolutions of the brain. (2) Color the upper two illustrations depicting the cranial meninges. The subarachnoid space (D), which is colored gray, can only be seen in the enlarged portion. Note where the inner layers of the dura mater (B) converge to form the falx cerebri (B'). (3) Color the infoldings of the dura mater in the large cranial view below. Note the outer layer (A) adjacent to the skull bones.



DURA MATER OF BRAIN AND SPINAL CORD

### CRAVIAL MENINGES:

#### DURA MATER:

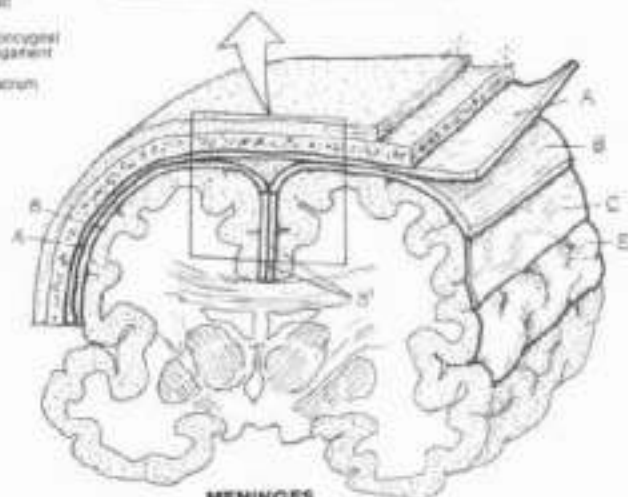
- OUTER (PERIOSTEAL) LAYER A
- INNER (MENINGEAL) LAYER B
- FALX CEREBRI B'
- TENTORUM CEREBELLI C
- FALX CEREBELLI D

#### ARACHNOID:

#### SUBARACHNOID SPACE (CSF): D

#### PIA MATER:

#### SPINAL DURA MATER: A'

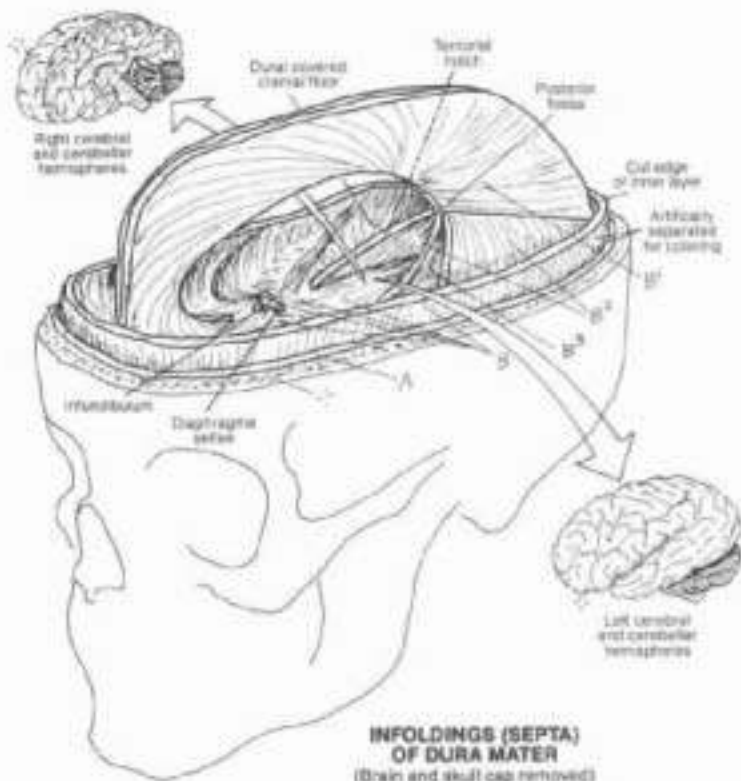


MENINGES OF THE BRAIN  
(Modified coronal section)

The brain and spinal cord are enveloped in fibrous coverings called meninges. The meninges of the spinal cord have been presented in Plate 138, and are the inferior extent of the cranial membranes presented here.

The outer meningeal covering (meninx) is the dense, fibrous dura mater. The outer layer is closely applied to the skull bone as periosteum. The inner layer splits off the cranial roof in the midline bilaterally, encloses the large venous superior sagittal sinus, and descends between the cerebral hemispheres in the longitudinal cerebral fissure as the falx cerebri. This sheet of dura is attached anteriorly at the crista galli and posteriorly at the internal occipital protuberance. It arches over the corpus callosum. It encloses the inferior sagittal sinus in its free border. The posterior part of the falx splits over the cerebellum to form the tent-like tentorium cerebelli, separating the cerebellum and other contents of the posterior fossa from the occipital lobes. The free edge of the tentorium forms a notch accommodating the midbrain; the tentorial notch or incisura. Given sufficient force, the incisura can incise the midbrain when the brain is rapidly loaded (accelerated) against the skull in serious head trauma. Extending vertically below the tentorium in the midline is the falx cerebelli which separates the paired cerebellar hemispheres. Note also the dural roof of the sella turcica (diaphragma sellae), enclosing the hypophysis. It is perforated to permit passage of the infundibulum. The inner layer of dura is continuous with the spinal dura mater.

The filmy, vulnerable arachnoid lies deep to and flush with the inner dura. The arachnoid is separated from the deeper pia mater by the subarachnoid space (filled with cerebrospinal fluid (CSF)). This space becomes voluminous at various locations (cisterns; Plate 143). The pia is a vascular layer of loose fibrous connective tissue, supporting the vessels reaching the brain (and spinal cord). It is inseparable from the surface of the brain and cord.

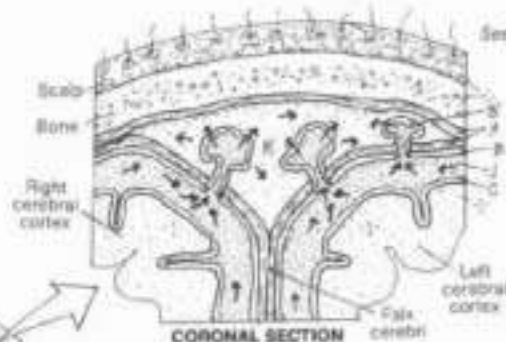


INFOLDINGS (SEPTA) OF DURA MATER  
(Brain and skull cap removed)

# XIV. NERVOUS SYSTEM

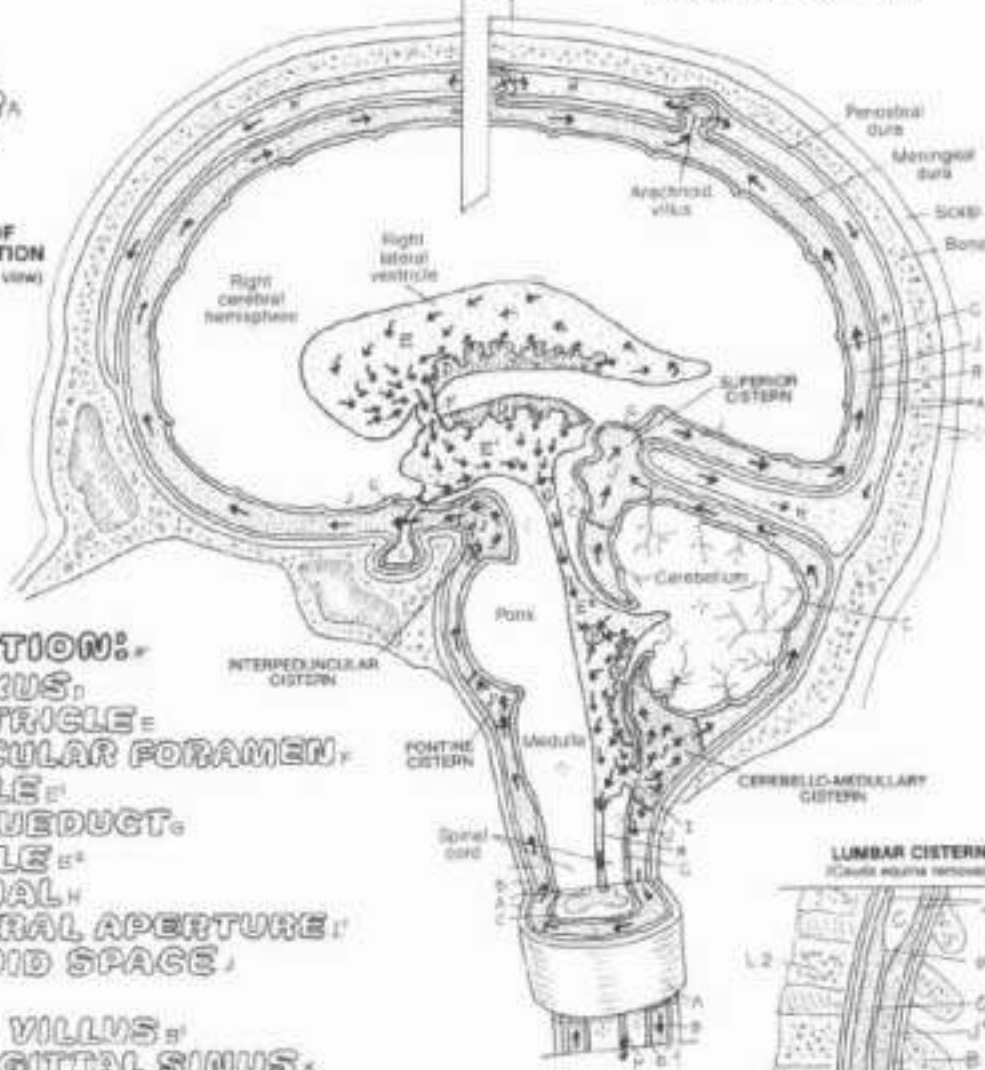
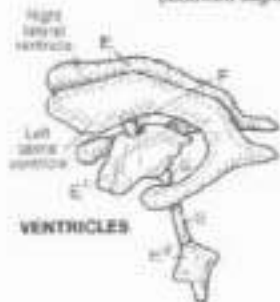
## CIRCULATION OF CEREBROSPINAL FLUID (CSF)

**CL:** Use the same colors as were used on the previous plate for the three meninges. Use blue for L and light blue for E through H, J and K. (1) Color the large illustration and the coronal section simultaneously, paying close attention to the arrows of directional flow. Note that both layers of dura (A) are given one color. (2) The four cisterns, part of the subarachnoid space, all receive one color (J'), including the lumbar cistern at lower right. (3) Color the medial and lateral apertures of the IV ventricle. (4) Complete the illustration at lower right.

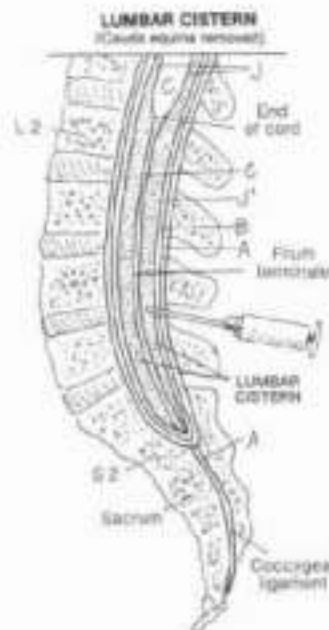


**MENINGES:**  
**DURA MATER,**  
**ARACHNOID,**  
**PIA MATER.**

**SCHEME OF CSF CIRCULATION**  
 (Modified sagittal view)



**CSF CIRCULATION:**  
**CHOROID PLEXUS,**  
**LATERAL VENTRICLE =**  
**INTERVENTRICULAR FORAMEN,**  
**3RD VENTRICLE =**  
**CEREBRAL AQUEDUCT,**  
**4TH VENTRICLE =**  
**CENTRAL CANAL,**  
**MEDIAN LATERAL APERTURE,**  
**SUBARACHNOID SPACE,**  
**CISTERN,**  
**ARACHNOID VILLUS,**  
**SUPERIOR SAGITTAL SINUS.**



Cerebrospinal fluid (CSF) is a clear, largely acellular fluid secreted by the choroid plexus (70%) and vessels near the ventricular walls into the lateral, third, and fourth ventricles. About 150 ml of CSF circulate through the ventricles and around the subarachnoid spaces (including cisterns). CSF flow through the central canal is minimal to non-existent. Although the fluid is an exudate of plasma from the capillaries (in the pia mater infolded with ependymal cells lining the ventricles), it has significantly less density and protein than plasma. CSF drains into the subarachnoid space via median and lateral apertures (foramina of Magendie and Luschka, respectively) located in the fourth ventricle. Cisterns are dilated subarachnoid spaces formed at flexures of the brain. The most notable of the cisterns is the lumbar cistern (not the central canal) in which

float the lumbar and lower nerve roots (cauda equina). This cistern is a frequent site of puncture (at a level of about the 4th lumbar vertebra) for withdrawal and diagnostic testing of CSF. Anesthetic agents and radiopaque dyes can also be introduced at this site. Cerebrospinal fluid is resorbed by cauliflower-shaped outpocketings of arachnoid called villi. These villi project into the superior sagittal sinus, one of the large veins draining the brain. CSF has a shock-absorbing function of great significance; the CNS literally floats within it. Cerebral injury from blows to the head are mitigated to a high degree by this fluid cushion. On the other hand, high intracerebral pressure induced by ventricular enlargement secondary to decreased CSF absorption or ventricular blockage (hydrocephalus) can cause significant brain damage.




# XIV. NERVOUS SYSTEM

## PNS: CRANIAL NERVES

Use light colors throughout. (1) Beginning with the first cranial nerve, color the life on the left, the large Roman numeral, the cranial nerve (out), and the related function arrow at lower left; and the roman numeral and accompanying illustration at upper right. The illustrations generally depict larger organs/areas. (2) Note carefully the direction of the function arrows at lower left (sensory/afferent is incoming; motor/efferent is outgoing).

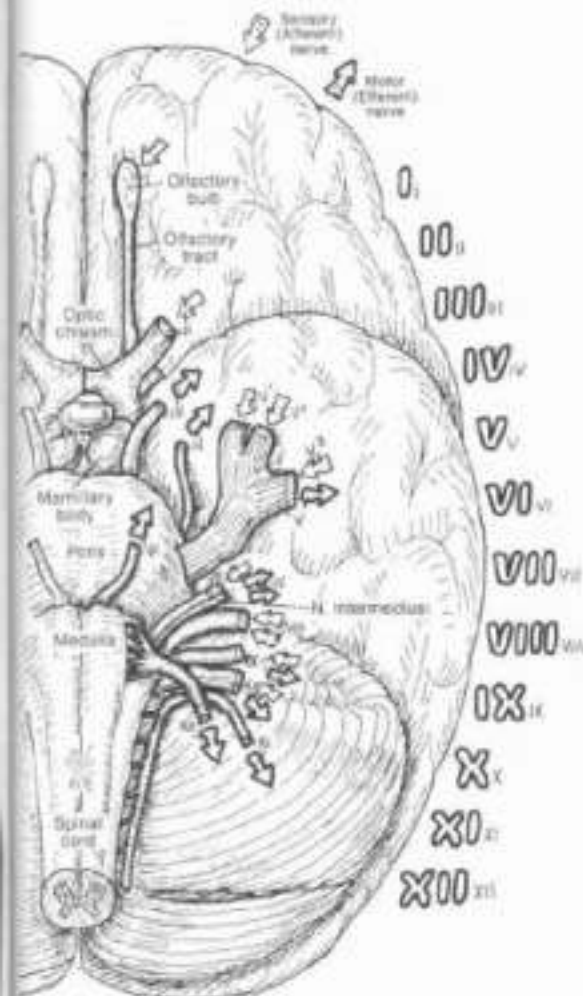
### CRANIAL NERVES:

- OLFACTORY (I)
- OPTIC (II)
- OCULOMOTOR (III)
- TROCHLEAR (IV)
- TRIGEMINAL (V)
- ABDUCENS (VI)
- FACIAL (VII)
- VESTIBULOCOCHLEAR (VIII)
- GLOSSOPHARYNGEAL (IX)
- VAGUS (X)
- ACCESSORY (XI)
- HYPOGLOSSAL (XII)



Here cranial nerves and their general target organs/areas are shown. All motor nerves include proprioceptive (sensory) fibers as well. Cranial nerves I and II are derived from the forebrain; all others are brain stem-derived. Cranial nerve nuclei (neuronal cell bodies) are arranged into seven longitudinal columns in the brain stem. Functionally, these columns are general somatic afferent (GSA) or efferent (GSE), general visceral afferent (GVA) or efferent (GVE), special visceral afferent (SVA) or efferent (SVE), and special somatic afferent (SSA). General columns also exist in the spinal cord for spinal nerves; special columns do not. Somatic includes skin, eye, fascial, and musculoskeletal structures; visceral includes smooth muscle and glands of organs with hollow cavities.

- I SVA: smell-sensitive (olfactory) receptors in roof/walls of nasal cavity
- II SSA: light-sensitive (visual) receptors in retina of eye
- III GSE: to extrinsic eye muscles (exc. lat. rectus and sup. oblique); GVE: parasympathetic to ciliary and pupillary sphincter (eye) muscles via ciliary ganglion in orbit
- IV GSE: to superior oblique muscle of the eye
- V GSA: from face via three divisions indicated; SVE: to muscles of mastication, tensor tympani, tensor veli palatini, mylohyoid, and digastric muscles
- VI GSE: to lateral rectus muscle of the eye
- VII SVA: from taste receptors ant. tongue; GSA: from ext. ear; GVE: parasympathetic to glands of nasal/oral cavity, lacrimal gland (via trigeminal ganglion in fossa of same name), submandibular/sublingual salivary glands (via submandibular ganglion in region of same name); SVE: to facial muscles, stapedius (int. ear), stylohyoid, post. digastric muscles
- VIII SSA: cochlear part is sound-sensitive; vestibular part is sensitive to head balance and movement (equilibrium)
- IX SVA: from taste receptors post. one-third tongue; GSA: from ext. ear and ext. auditory canal; GVA: from mucous membranes of posterior mouth, pharynx, auditory tube, and middle ear; from pressure and chemical receptors in carotid body and common carotid artery; SVE: to sup. constrictor m. of the pharynx, stylopharyngeus; GVE: parasymp. to parotid gland (via otic ganglion in infratemporal fossa)
- X SVA: from taste receptors at base of tongue and epiglottis; GSA: from ext. ear and ext. aud. canal; GVA: from pharynx, larynx, thoracic and abdominal viscera; SVE: to muscles of palate, pharynx, and larynx; GVE: parasymp. to muscles of thoracic and abdominal viscera (via intramural ganglia)
- XI Cranial root: joins vagus (GVA to laryngeal muscles); spinal root (C1-C5) innervates trapezius and sternocleidomastoid muscles
- XII GSE: to extrinsic and intrinsic muscles of tongue



ANTERIOR-INFERIOR SURFACE  
(Left brain, brainstem, and cerebellum)

# XIV. NERVOUS SYSTEM

## PNS: SPINAL NERVES & ROOTS

CN. Use very light colors D through G. (1) Begin with the upper illustration. Color all three pairs of spinal nerves as they emerge from the intervertebral foramina (M). (2) Color the cross-sectional view in the center. (3) Color the spinal nerve axons and the arrows representing direction of impulse flow.

**SPINAL NERVE ROOTS:**  
**POSTERIOR ROOT,**  
**SENSORY AXON,**  
**CELL BODY,**  
**POSTERIOR ROOT GANGLION,**  
**ANTERIOR ROOT,**  
**MOTOR AXON,**  
**CELL BODY.**

**SPINAL NERVE, RAMUS,**

Spinal nerves are collections of axons of sensory and motor neurons (part of the peripheral nervous system or PNS). They are formed from nerve roots that arise directly from the spinal cord. Axons of sensory neurons make up the posterior root, and axons of motor neurons make up most of the anterior root (it has been reported that some 30% of anterior root axons are sensory). The spinal nerves and their roots are arranged segmentally and bilaterally along the length of the spinal cord. Spinal nerves are very short, formed within the intervertebral foramina, they branch just beyond into anterior and posterior rami. The branches of these rami are distributed bodywide below the head and provide a vehicle for acquisition by the central nervous system (CNS) of sensory information from external and internal receptors, and a means of disseminating motor commands to skeletal, smooth, and cardiac muscle, and to glands.

Spinal nerves and their roots have fairly light quarters. The relations of these nerves and roots can best be appreciated in the cross-sectional view. Nerve roots are vulnerable to irritation (radiculitis) from encroaching, hypertrophic bone in the lateral recesses (degenerative joint disease), from bulging intervertebral discs (degenerative disc disease), or from cysts, meningeal tumors, and so on. With compression of axons or blood vessels supplying the axons, functional deficits can result (radiculopathy; sensory loss, motor loss, and/or tendon reflex change).

**NERVE ROOT RELATIONS:**

**VERTEBRA:**

**BODY,**

**LAMINA,**

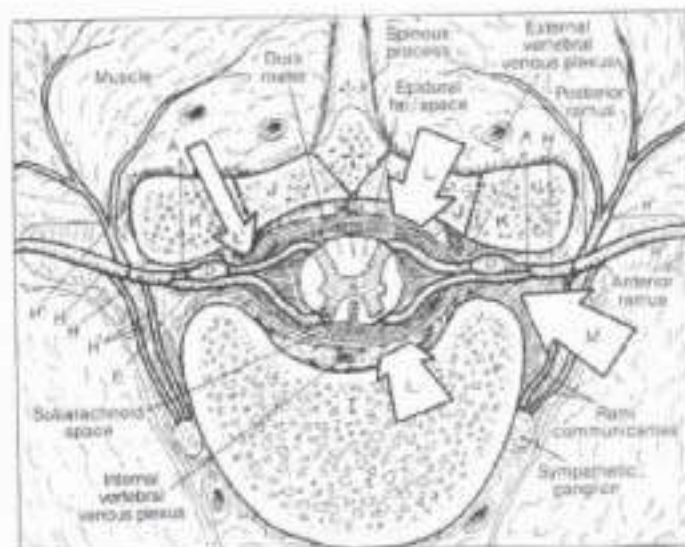
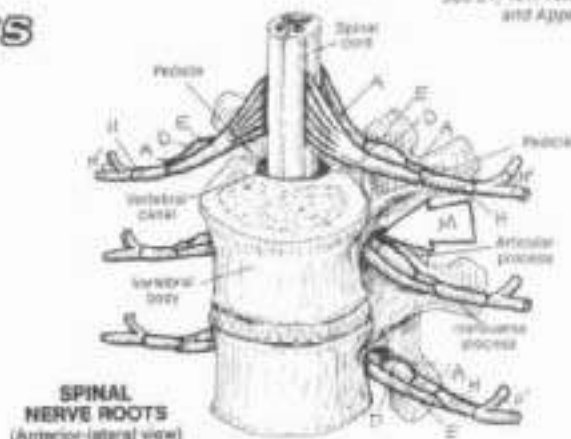
**ARTICULAR PROCESS,**

**VERTEBRAL CANAL,**

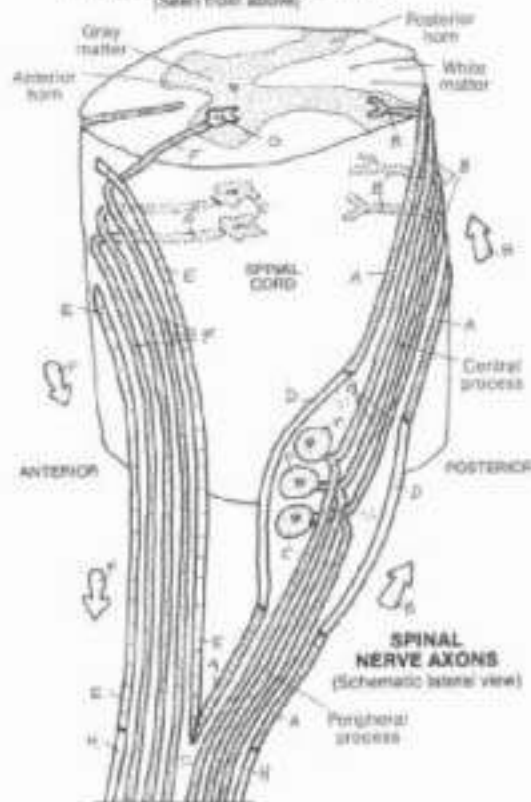
**LATERAL RECESS,**

**INTERVERTEBRAL FORAMEN.**

The posterior roots of spinal nerves consist of peripheral processes (axons) of sensory neurons, unipolar or pseudo-unipolar neuron cell bodies (aggregations of which are called spinal or posterior root ganglia), and central processes (axons) of sensory neurons. The ganglia form obvious swellings in the area of the intervertebral foramina. The axonal endings synapse with neurons in the posterior horn of the spinal cord or enter the posterior columns (recall Plate 139). The anterior roots consist of axons of motor (multipolar) neurons whose cell bodies reside in the anterior horns of the spinal cord. These neurons are known as lower motor neurons or anterior horn cells and represent the final common pathway for motor commands to skeletal muscles. In the T1-L2 regions of the cord, motor neurons of the sympathetic division of the autonomic (visceral) nervous system reside in the lateral horns (not shown); their axons join the anterior roots.



**CROSS SECTION THROUGH T8**  
(Seen from above)





# XIV. NERVOUS SYSTEM

## PNS: STRETCH REFLEXES

**CN:** Use light colors for A and C, and use the same colors you used on Pl. 145 for structures D-F. (1) Color the upper two illustrations simultaneously, in numerical sequence 1-6, including the arrows. The small arrows at the end of the muscle segments indicate contraction or stretch. (2) Color the lower two illustrations similarly. Note that the motor neuron synapsing with the inhibitory interneuron, and the related effector, are not colored.

**MONOSYNAPTIC REFLEX:**  
**STRETCH RECEPTOR,**  
**SENSORY NEURON,**  
**SPINAL CORD,**  
**MOTOR NEURON,**  
**END PLATE,**  
**EFFECTOR:**

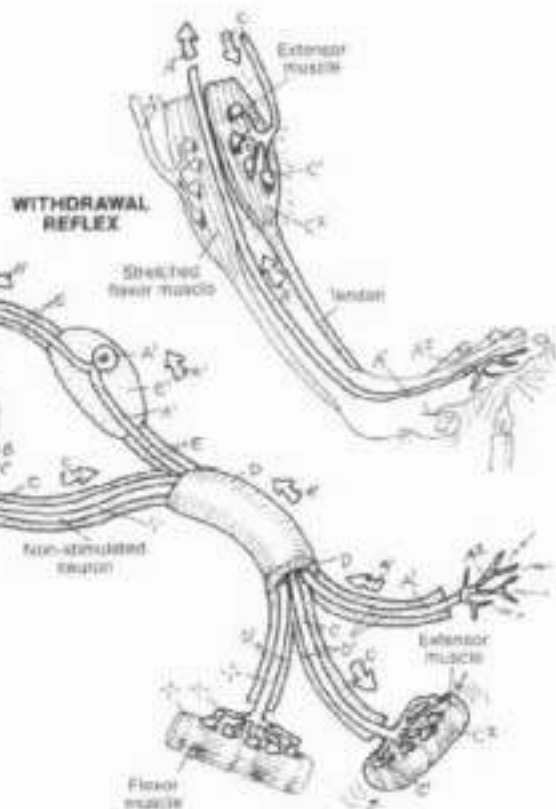
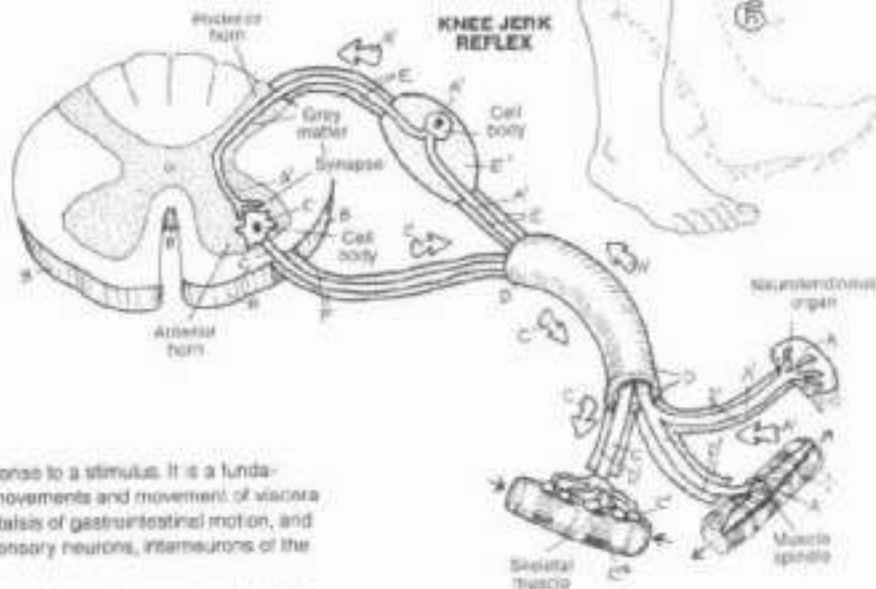
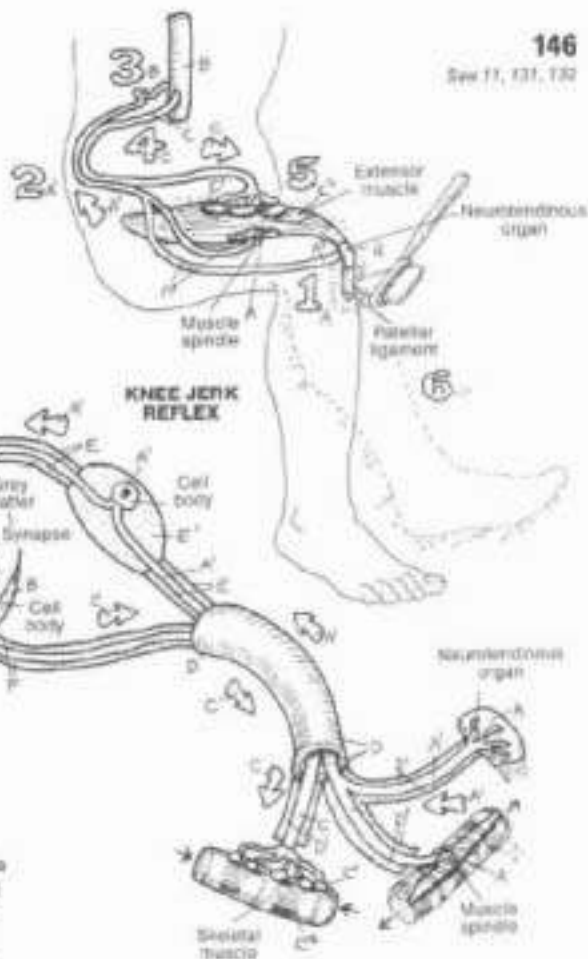
**SPINAL NERVES/**  
**ROOTS:**  
**SPINAL NERVE,**  
**BRANCH,**  
**POSTERIOR ROOT,**  
**GANGLION,**  
**ANTERIOR ROOT,**

A reflex (hard back) is an involuntary muscle response to a stimulus. It is a fundamental activity of the nervous system; most body movements and movements of viscera are reflexive, e.g., heart rate, respiratory rate, peristalsis of gastrointestinal motion, and so on. Spinal reflexes involve sensory receptors, sensory neurons, interneurons of the spinal cord, motor neurons, and effectors.

The simplest spinal reflex is a monosynaptic reflex involving two neurons and one synapse (myotatic, stretch, or deep tendon reflex). The reflex is activated by stretching the tendon of a specific muscle, such as the tendon of quadriceps femoris at the knee. This can be done with the sharp tap of a small mallet used for such purposes (or with the 5th-digit-side of a hand). The receptors responsive to such a stretch are the neurotendinous (Golgi) tendon organ and the muscle spindle (specialized muscle fibers with nerve endings sensitive to muscle stretch and motor nerves to those muscles which resist stretch and "unload" the spindle). Impulses generated in these receptors (1) are conducted by sensory neurons (2) to the spinal cord (3); these synapse in the grey matter with the anterior horn motor neurons (4). The motor neuron conducts impulses to the end plates of the effector muscle (5). The muscle contracts sufficiently, in the case of the knee reflex ("jerk"), to extend the knee joint momentarily (6).

**POLYSYNAPTIC REFLEX:**  
**PAIN RECEPTORS,**  
**INTERNEURON,**  
**FACILITATING (+),**  
**INHIBITING (-)**

Polysynaptic reflexes range from simple withdrawal reflexes to complex reflexes involving several segments of the spinal cord and the brain. In the withdrawal reflex shown, extreme heat applied to the hand of an unsuspecting person induces an involuntary hyperextension of the wrist joint by wrist extensors, associated with a simultaneous relaxation and stretch of the antagonist wrist flexor muscles. Obviously, the former cannot occur without yielding of the latter. The main difference between this reflex and the stretch reflex is the interneuron, two facilitating the withdrawal, and one inhibiting contraction of the antagonist (flexors) to the withdrawal.





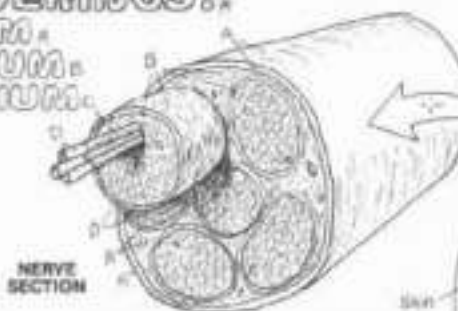
# XIV. NERVOUS SYSTEM

## PNS: DISTRIBUTION OF SPINAL NERVES

Ch. Use the same colors for E-G that were used for those structures in the preceding plate. Use light colors for A-D. (1) Begin with the nerve coverings. Note that the endoneurium (C) is shown only on the protected axons. (2) Color the typical thoracic spinal nerve and its branches in the cross section of the thorax. (3) Color the spinal nerves and their branches in the lowest drawing. Note especially the difference between intercostal nerves (one spinal nerve each) and nerves of the plexuses and their branches (combined spinal nerves).

### NERVE COVERINGS:

- EPINEURIUM,
- PERINEURIUM,
- ENDONEURIUM,
- AXON,



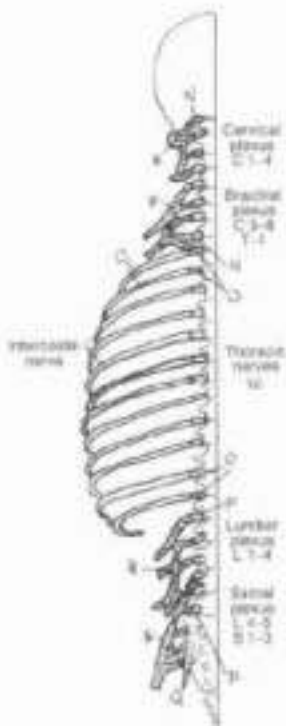
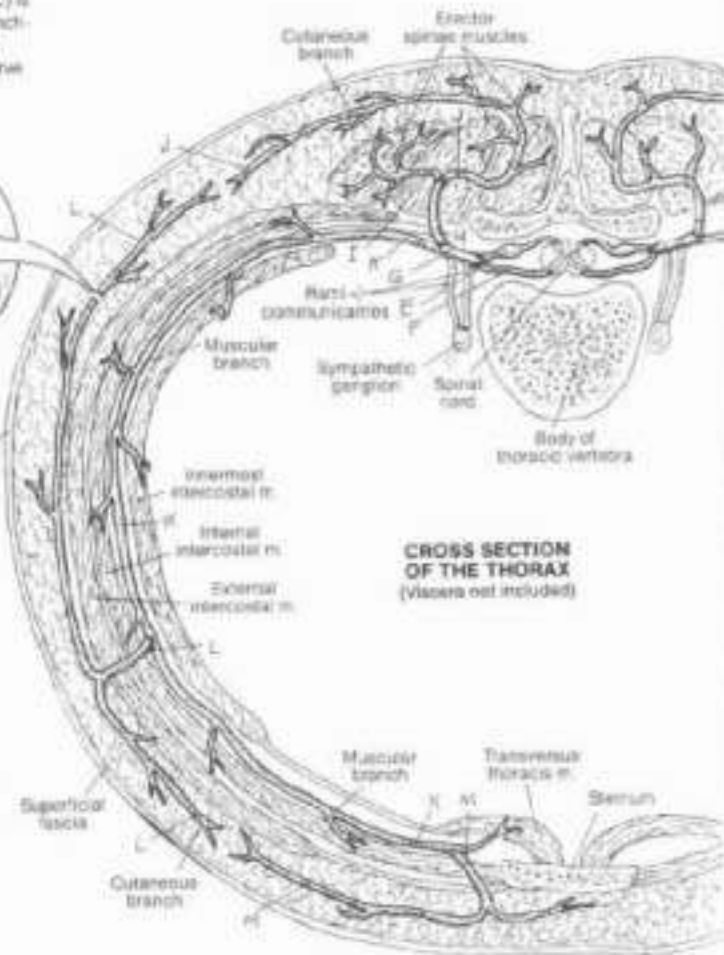
Spinal nerves and their branches consist of axons of sensory and/or motor neurons ensheathed in fibrous connective tissue. Individual axons are surrounded by thin envelopes of fibrous tissue (endoneurium) containing nerves and capillaries that supply the living axon. Bundles (fascicles) of axons are bound by thicker, more dense coats of fibrous tissue (perineurium). Between (and within) the fascicles are relatively large vessels and nerve bundles. Surrounding the fascicles are circumferentially arranged loose arrays of fibrous tissue contiguous with deep or superficial fascia (epineurium). These supporting tissues stabilize the neurovascular elements and provide a framework for the nerve in its environment.

### THORAGIC SPINAL NERVE:

- POSTERIOR ROOT,
- ANTERIOR ROOT,
- SPINAL NERVE,
- POSTERIOR RAMUS,
- LATERAL BRANCH,
- MEDIAL BRANCH,
- ANTERIOR RAMUS,
- (INTERCOSTAL NERVE),
- LAT. CUTANEOUS BR.,
- ANT. CUTANEOUS BR.

Each spinal nerve leaves an intervertebral foramen and divides into anterior and posterior (primary) rami. The anterior rami supply all parts of the body except the deep (intrinsic) muscles and skin of the back; thus, the anterior ramus is generally larger than its posterior fellow. The anterior rami contribute to networks of interconnecting nerves (plexuses or plexi) supplying the neck, upper limb, pelvis/perineum, and lower limb. In the torso, anterior rami form the intercostal nerves. The distribution pattern of a typical thoracic spinal nerve is shown in the cross section of the thorax. Note the rami communicantes; these will be presented in Plate 151. Note the muscular branches of the anterior ramus passing between innermost and internal intercostal muscles, as well as the lateral and anterior cutaneous branches and their distribution in the superficial fascia. Note the areas of overlap between the cutaneous branches of the anterior rami and those of the posterior rami. This pattern occurs segmentally and bilaterally throughout the thorax; the lower thoracic spinal nerves also supply most of the abdominal wall.

The anterior rami of the cervical spinal nerves (and T1 spinal nerve) form interconnecting networks from which the nerves to the neck and the upper limb are derived (next plate). The anterior rami of the lumbar and sacral spinal nerves form interconnecting plexuses from which the nerves to the pelvis, perineum and lower limb are derived (Plate 149). Thus, the source of an intercostal nerve can be traced to the single spinal nerve forming it, e.g., T6 spinal nerve, whereas the source of a nerve to the limbs is traced to the collection of spinal nerves that form it, e.g., C5-C8 spinal nerves.



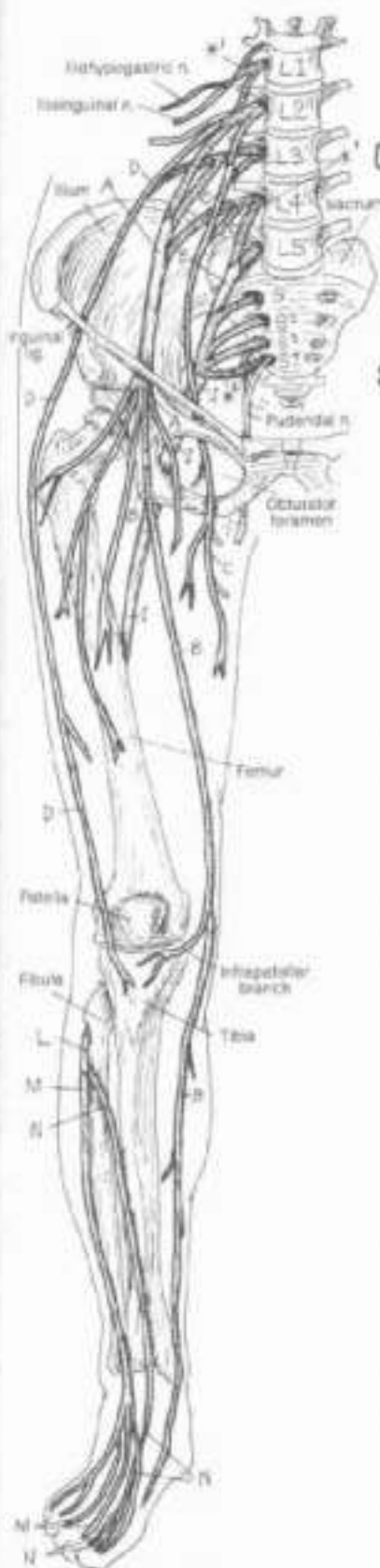
**SPINAL NERVES & BRANCHES:**  
 CERVICAL,  
 THORACIC,  
 LUMBAR,  
 SACRAL.





# XIV. NERVOUS SYSTEM

## PNS: NERVES OF THE LOWER LIMB



ANTERIOR VIEW

CR: Use a bright color for J. (1) Begin with the anterior view. Color the lumbar and sacral plexuses gray; note that they have been dotted for easy identification. Note the longest branch of the femoral nerve, saphenous nerve. (2) Color the posterior view which includes almost entirely the sciatic nerve and its branches.

### LUMBAR PLEXUS \*1

- FEMORAL N. A
- SAPHENOUS N. B
- OBTURATOR N. C
- LAT. FEMORAL CUTAN. N. D
- LUMBOSACRAL TRUNK E

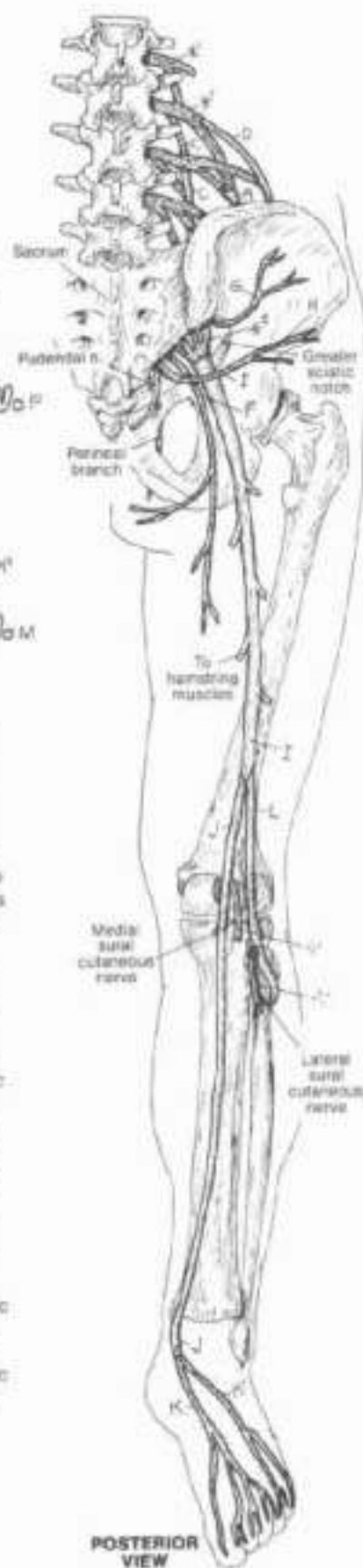### SACRAL PLEXUS \*2

- POST. FEMORAL CUTAN. N. F
- SUPERIOR GLUTEAL N. G
- INFERIOR GLUTEAL N. H

### SCIATIC N. I

- TIBIAL N. J
- MED. LAT. PLANTAR N. K
- COMMON PERONEAL N. L
- SUPERFICIAL PERON. N. M
- DEEP PERON. N. N

The nerves to the lower limb arise from the lumbar (L1-L4) and sacral (S1-S3) plexuses. These plexuses are formed from anterior rami of the spinal nerves noted. The lumbar plexus is located in the retroperitoneum against the posterior abdominal wall; it is the source of two major nerves to the lower limb. The femoral nerve (L2-L4), giving forth an effusion of nerves just below the inguinal ligament, and in company with the (superficial) femoral artery and vein, innervates quadriceps femoris and sartorius and is sensory to the anterior thigh. Trauma to this nerve is most likely in the pelvis as it passes through or near the psoas muscle (hemorrhage, surgical misadventure, and so on). The obturator nerve (L2-L4) passes along the lateral pelvic wall and through the obturator foramen to break up into branches supplying the adductor muscle group. Like the femoral, it too is subject to trauma in the pelvis. Compressions of the L2-L4 nerve roots can be manifested by complaints in the anterior and medial femoral region. The sacral plexus gives rise to a number of important nerves, the most significant being the sciatic nerve (L4-S3). Roughly the size of your thumb, this nerve passes deep to gluteus maximus into the posterior thigh, innervating the "hamstring" muscles. Just above and behind the knee, it splits into peroneal and tibial components. The common peroneal nerve supplies the lateral leg muscles (superficial peroneal) and the antero-lateral leg muscles (deep peroneal). The tibial nerve supplies the posterior leg muscles and the plantar muscles (sole of the foot). Compression of the L4-S1 nerve roots commonly affects the sciatic distribution (e.g., sciatica or pain in the lower limb along the sciatic distribution). More significant compression results in specific leg or foot muscle weakness and sensory loss. S1 radiculopathy is characterized by a loss of the achilles (ferrocalcaneus) reflex or "ankle jerk." The sciatic can be injured as it exits the greater sciatic notch or in the buttock. The common peroneal nerve is vulnerable as it rounds the subcutaneous fibular neck; trauma to this nerve may be expressed as "foot drop" (loss of ankle/toe extensors). See the appendix for listing of lower limb muscles and their nerve supply.



POSTERIOR VIEW

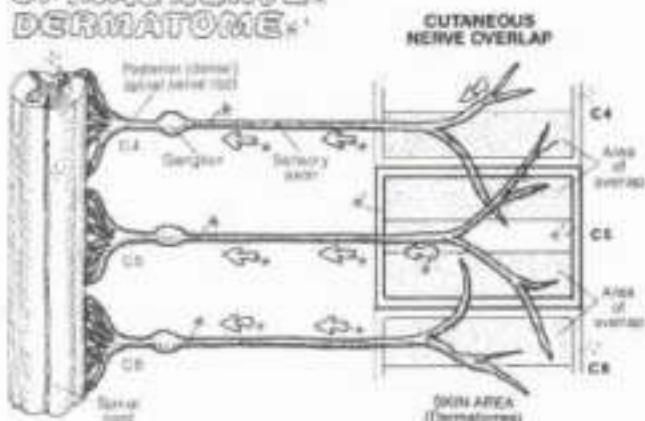


## XIV. NERVOUS SYSTEM

### DERMATOMES

ON: (1) Begin with the diagram at left, depicting sensory innervation of an area of skin (dermatome) and the degree of overlap among contiguous spinal nerve cutaneous branches and the dermatomes they supply. Color gray the three spinal nerves and the rectangular borders of the related dermatomes. Note the overlap. (2) Use very light colors for the four groups of dermatomes. Use one color for all dermatomes (represented by bordered spaces) with the letter C; another color for the dermatomes marked with a T, and so on with L and S. Suggestion: carefully outline the collection of C dermatomes with the color used for C, then color in the enclosed area, focusing on the skin areas served by the related spinal nerve; repeat with T, L, and S dermatomes.

### SPINAL NERVE-DERMATOME



**DERMATOMES OF:**

**CERVICAL NERVES:**  
C2 - C8

**THORACIC NERVES:**  
T1 - T12

**LUMBAR NERVES:**  
L1 - L5

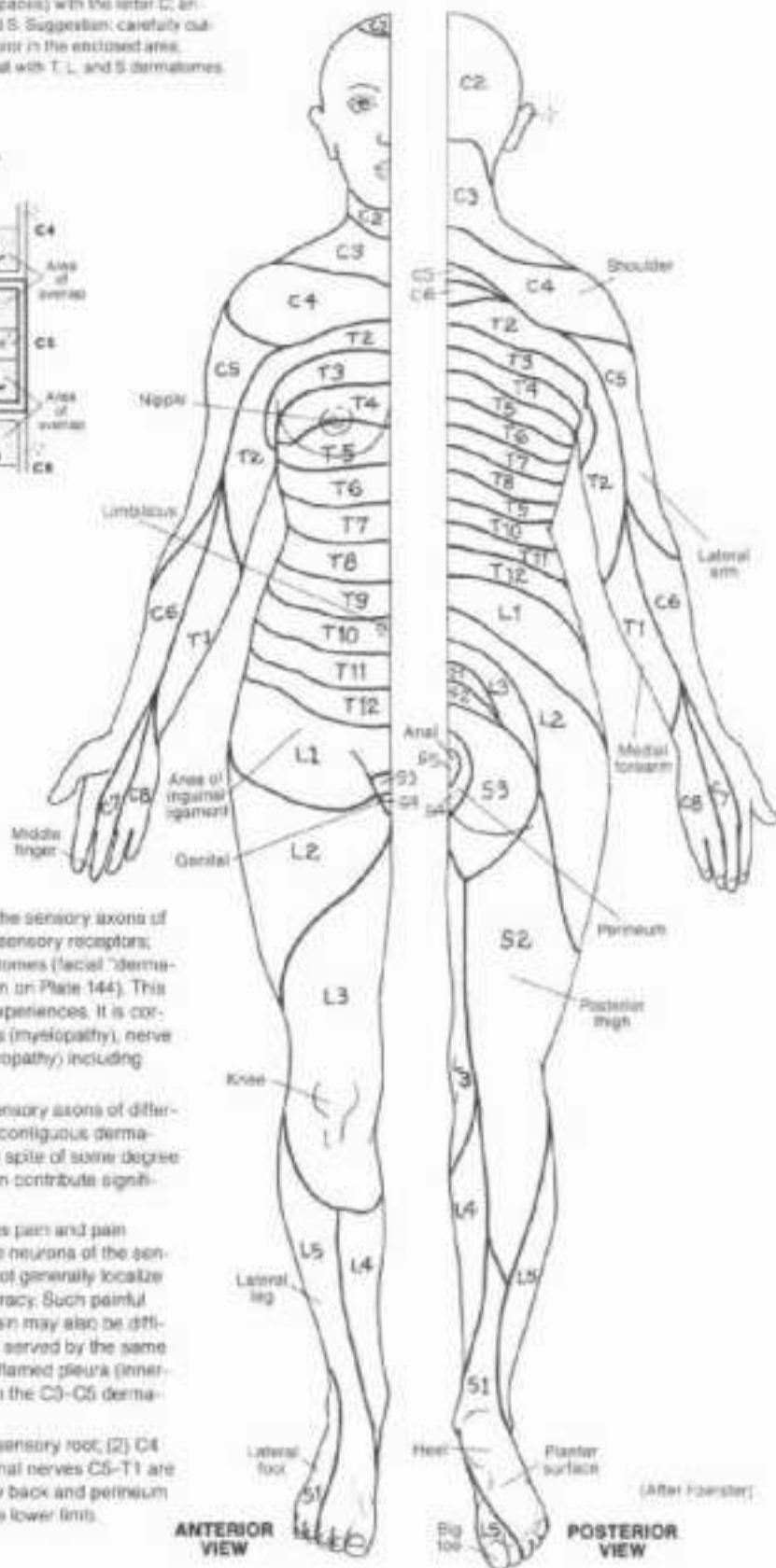
**SACRAL NERVES:**  
S1 - S5

A dermatome is an area of skin (cutaneous area) supplied by the sensory axons of a single spinal nerve. The body surface is globally covered by sensory receptors; thus the entire surface can be appreciated as a map of dermatomes (facial "dermatomes" supplied by divisions of the V cranial nerve can be seen on Plate 144). This map was generated from experimental, clinical, and surgical experiences. It is corroborated in patients presenting with limited spinal cord deficits (myelopathy), nerve root deficits (radiculopathy), and peripheral nerve lesions (neuropathy) including facial pain (trigeminal neuralgia).

There is overlap among cutaneous branches of neighboring sensory axons of different spinal nerves. Thus, the border zone between each pair of contiguous dermatomes is covered by two branches of different spinal nerves. In spite of some degree of dermatomal overlap, dermatomal pain or sensory deficits can contribute significantly to diagnoses of certain neurologic disorders.

It is important to realize that dermatomes reflect only cutaneous pain and pain referred to the skin (e.g., nerve root irritator, visceral pain). The neurons of the sensory cortex of the cerebral hemisphere and the thalamus cannot generally localize myofascial and musculoskeletal pain with strict anatomic accuracy. Such painful areas usually "cross" dermatomal lines. Commonly, visceral pain may also be difficult to localize; however, it may be referred to cutaneous areas served by the same spinal nerve(s), making the diagnosis easier, e.g., the pain of inflamed pleura (innervated by C3-C5 spinal nerves) in the lower chest may be felt in the C3-C5 dermatomes (shoulder) during deep inspiration.

Finally, note that: (1) C1 has no dermatome because it has no sensory root; (2) C4 and T2 dermatomes overlap on the chest wall because the spinal nerves C5-T1 are committed to the upper limb; (3) and the same is true in the low back and perineum with respect to spinal nerves L4-S2 which are committed to the lower limb.



ANTERIOR VIEW

POSTERIOR VIEW

(After Foerster)

# XIV. NERVOUS SYSTEM

## ANS: SYMPATHETIC DIVISION (1)

OK. This plate is part one of a two-part presentation of the sympathetic division, and many structures on this and the next plate with the same titles and subscripts should receive the same color. (1) Begin with the schematic of the spinal cord segments containing the cell bodies of preganglionic neurons. These neurons (not shown) leave the spinal cord to enter or pass through the sympathetic chain. (2) Color the sympathetic chain and relations at upper right. (3) Color the pathways of the preganglionic and postganglionic neurons below. (4) Color the inset illustration.

### SPINAL CORD SEGMENTS T1-L2

#### PREGANGLIONIC CELL BODY:

#### PREGANGLIONIC AXON:

#### WHITE COMM. RAMUS:

#### SPLANCHNIC NERVE:

#### PREVERTEBRAL GANGLION:

#### SYMPATHETIC CHAIN:

#### POSTGANGLIONIC CELL BODY:

#### POSTGANGLIONIC AXON:

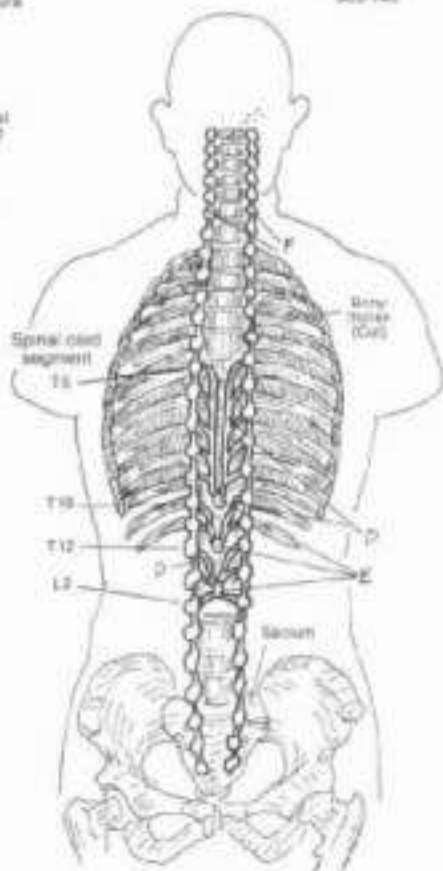
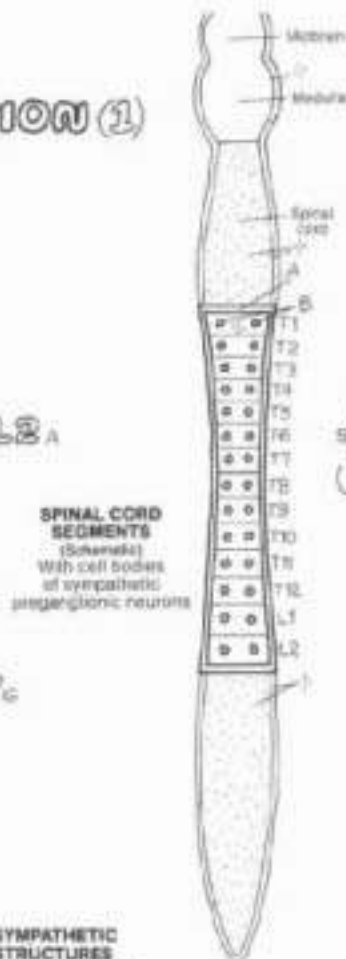
#### GRAY COMM. RAMUS:

#### SPINAL NERVE:

The autonomic nervous system (ANS; also visceral nervous system or VNS) is a part of the peripheral nervous system (PNS) responsible for the innervation of smooth muscle and glands in viscera and skin, and specialized cardiac muscle. It is a motor system uniquely characterized by two-neuron linkages and motor ganglia (pre- and post-ganglionic neurons). Sensory impulses from viscera are conducted by typical sensory neurons not generally described with the ANS but considered part of the VNS. The sympathetic (thoracolumbar) division of the ANS is concerned with degrees of "fight or flight" responses to stimuli: pupilary dilatation, increased heart and respiratory rates, increased blood flow to brain and skeletal muscles, and other related reactions.

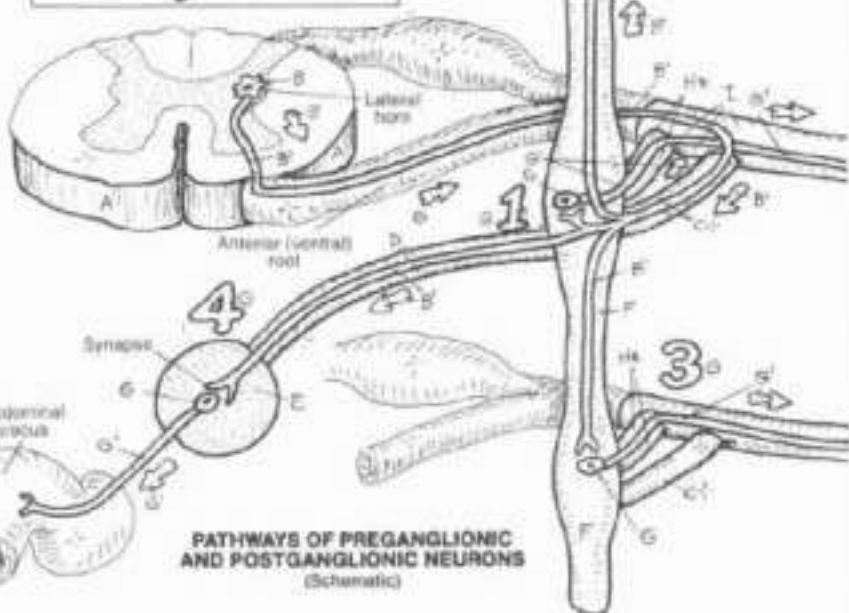
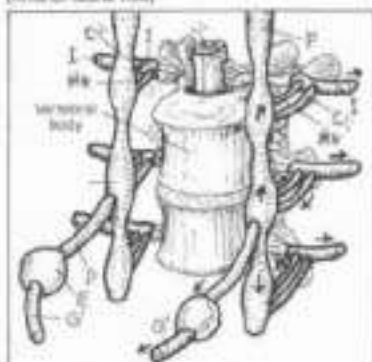
The cell bodies of preganglionic neurons are restricted to the lateral horns of the spinal cord segments T1 through L2. The axons of these neurons leave the cord via the anterior roots, join with spinal nerves for a very short distance, and turn medially to enter the sympathetic chain of ganglia via the white communicating rami (white because the axons are myelinated and "white"). The chain is located bilaterally alongside the vertebral column (see inset illustration). Once in the chain, the preganglionic axons can take one or more of four courses: (1) synapse with the postganglionic neuron at the same level it entered the chain; (2) ascend and synapse at a higher level of the chain; (3) descend and synapse at a lower level of the chain; (4) pass straight through the chain, forming a nerve that runs from the chain to the front of the vertebral column (splanchnic nerve), and synapse with a postganglionic neuron there (prevertebral ganglia).

The postganglionic neuron within the chain leaves via the gray communicating ramus to join the spinal nerve. There are gray rami bilaterally at every segment of the spinal cord, while rami exist only from T1-L2. Gray rami are so-called because the resident axons are unmyelinated and collectively have a duller color than those of the white rami. Postganglionic axons from prevertebral ganglia travel in a plexus-configuration to the viscera they supply. Plate 152 puts this division into a more meaningful perspective.



SPINAL CORD SEGMENTS (Schematic) With cell bodies of sympathetic preganglionic neurons

ANTERIOR VIEW (Schematic)



PATHWAYS OF PREGANGLIONIC AND POSTGANGLIONIC NEURONS (Schematic)



# XIV. NERVOUS SYSTEM

## AUS: SYMPATHETIC DIVISION (2)

On Use the same colors as you used on the preceding class for preganglionic neurons (B), splanchnic nerves (D), and postganglionic neurons (G), all of which have been given the subscripts they had on Plate 151. (1) First orient yourself to this diagram. Note the spinal cord in the center with sympathetic chains of ganglia on either side. Not all connections of both chains are shown. Here, the pathways on the left are to the skin. Pathways on the right are to viscera in the head and body cavities. (2) Start with the preganglionic neurons on the left, and color the chain and related parts on the left. Then read the related text. (3) Color the preganglionic neurons on the right and the splanchnic nerves to the abdominal viscera. (4) Color the postganglions to the head and thorax, and then the postganglions from the prevertebral ganglia to the abdominal and pelvic/perineal organs.

### PRYGANGLIONIC NEURONS:

### SPLANCHNIC N.:

### POSTGANGLIONIC NEURONS:

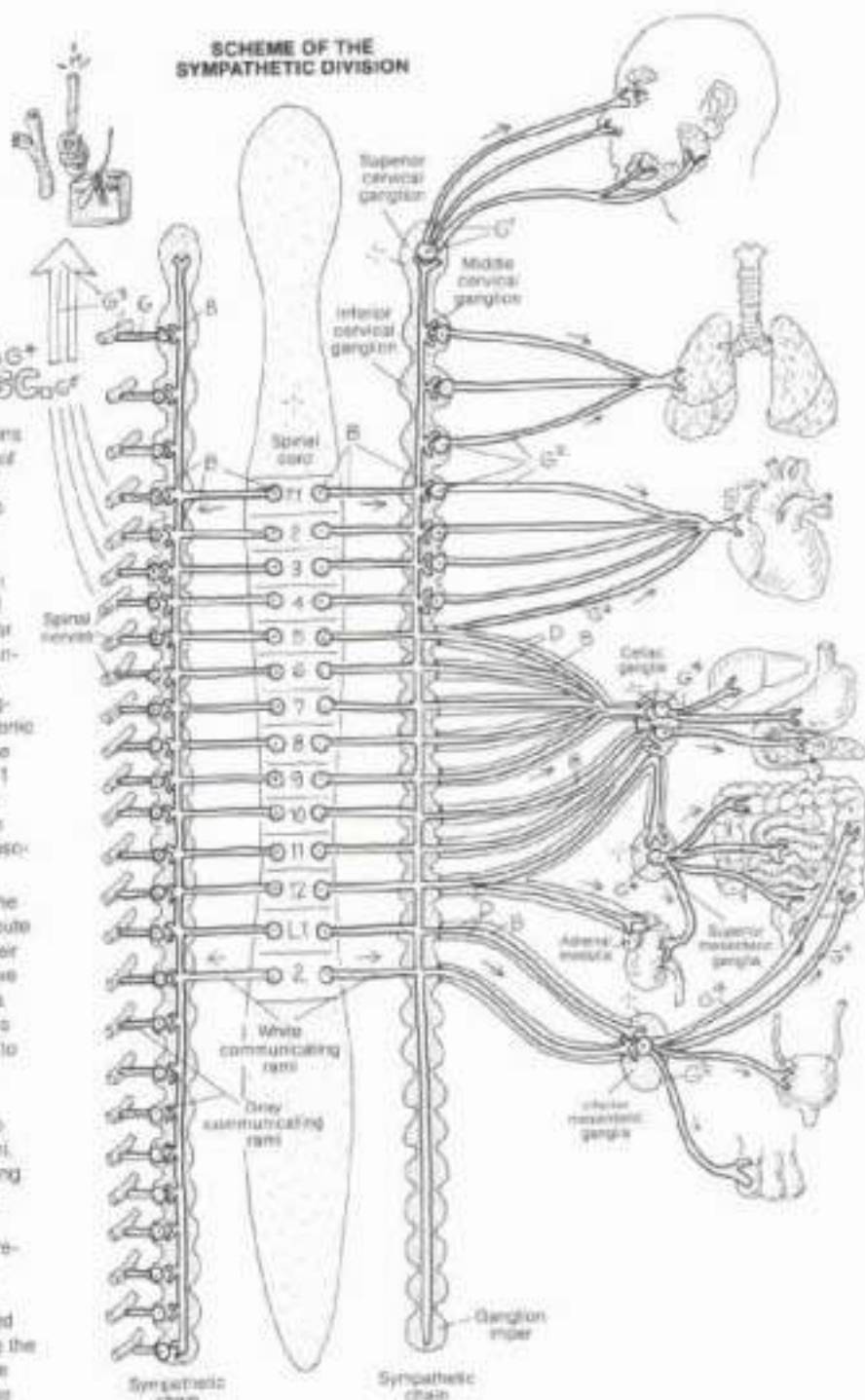
TO HEAD & NECK  
TO THORACIC VISCERA  
TO SKIN

SWEAT GLANDS  
ARRECTOR PILI  
BLOOD VESSELS  
TO ABDOMINAL VISCERA  
TO PELVIC/PERINEAL VISC.

Sympathetic innervation of skin (and viscera as well) begins with the preganglionic neurons in the thoracolumbar part of the spinal cord. The axons leave the cord via the anterior rami of spinal nerves, enter and leave the spinal nerves to join the white communicating rami. These rami bring the axons into the sympathetic chain. Axons from the upper thoracic cord ascend the chain up to the highest ganglion (superior cervical ganglion at the level of the first cervical vertebra). Axons from the lower thoracic and upper lumbar cord enter the chain and descend as far as the lowest ganglion (ganglion impar at the level of the coccyx). At every level of the chain (roughly coincident with spinal cord segments), the preganglionic axons synapse with postganglionic neurons. The postganglionic axons leave the chain via the gray communicating rami, enter the spinal nerves from C1 through Co1, and reach the skin via cutaneous branches of these nerves. These axons induce secretory activity in sweat glands, contraction of arrector pili muscles, and vasoconstriction in skin arterial vessels.

Postganglions to the head (vessels and glands) leave the superior cervical ganglia and entwine about arteries enroute to the head (in the absence of spinal nerves) to reach their target organs. Postganglions to the heart and lungs leave the upper ganglia of the chain, reaching these organs via cardiac nerves and the pulmonary plexus. These neurons act on heart muscle and the cardiac conduction system to increase heart rate; they induce relaxation of bronchial musculature, facilitating easier breathing.

Preganglions to abdominal and pelvic viscera leave the cord at levels T5-L2, enter the white communicating rami, and pass through the sympathetic chain without synapsing. They form three pairs of splanchnic nerves between the chain and the prevertebral ganglia on the aorta. These axons synapse with the postganglionic neurons in the prevertebral ganglia. The axons of these neurons reach for smooth muscle, inducing contraction of sphincters and decreasing intestinal motility, relaxing bladder muscle and constricting the urinary sphincter. These axons stimulate the adrenal medulla to secrete mostly epinephrine and some norepinephrine, stimulate secretion of glands and muscle contraction in the male genital ducts (ejaculation), and stimulate uterine contractions.





# XIV. NERVOUS SYSTEM

## ANS: PARASYMPATHETIC DIVISION

CN. Continue using the same colors you used on Plates 151 and 152 for subscripts B, D, and G. Use a bright color for E. This drawing shows the parasympathetic scheme on one side of the body only. (1) Start with the preganglionic neurons in the head and work through the postganglionic neurons, noting the structures innervated. Note particularly the extensive pattern associated with the vagus nerve. (2) Continue with the sacral preganglionics and postganglionics, noting the target organs. (3) Color the diagram describing ganglia location in the two ANS divisions.

### REGANGLIONIC NEURONS:

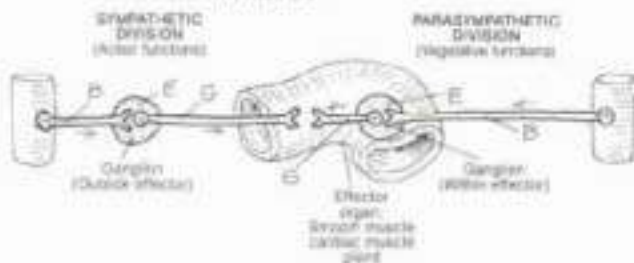
WITH: III CRANIAL N.  
VII CRANIAL N. IN CRANIAL N.  
X CRANIAL N.

### PELVIC SPANCHNIC N.

GANGLIA: CILIARY, PTERYGO-PALATINE, SUBMANDIBULAR, OTIC, INTRAMURAL

POSTGANGLIONIC NEURONS:  
TO: EYE, NASAL/ORAL CAVITIES, SALIVARY GLANDS, THORACIC/ABDOMINAL VISCERA, PELVIC/PERINEAL VISCERA

#### LOCATION OF GANGLIA IN THE ANS



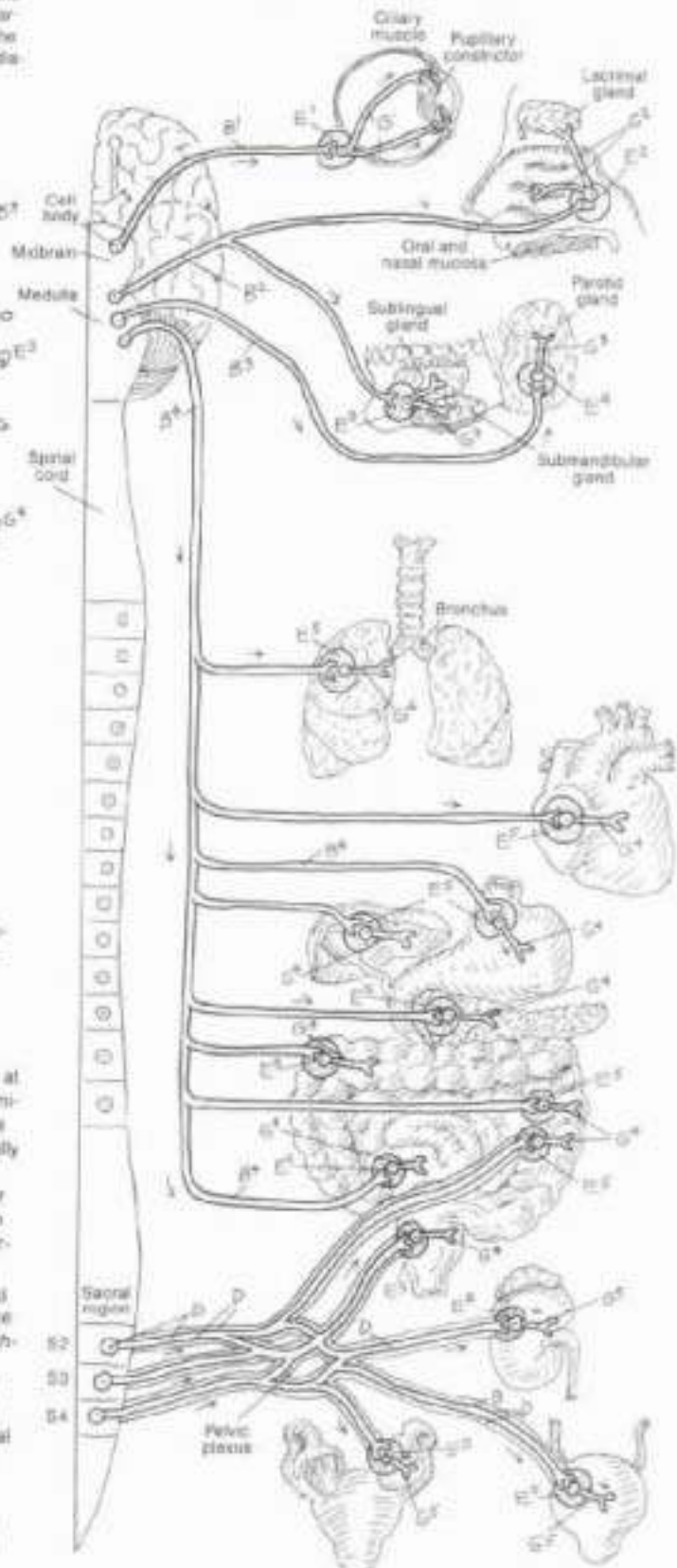
The parasympathetic division of the ANS is concerned with vegetative functions, e.g., encourages secretory activity on the body's mucous and serous membranes, promotes digestion by increased peristalsis and glandular secretion, and induces contraction of the urinary bladder.

The parasympathetic preganglionic neuronal cell bodies in the head are located in the brain stem associated with certain cranial nerves. The preganglionic axons leave the brain stem with their cranial nerve, and synapse at one of the cranial ganglia. The postganglionic neurons tend to be short, terminating in salivary glands and other glands of the nasal and oral cavities. The preganglionic fibers associated with the vagus (X cranial) nerve are unusually long, descending the neck, the esophagus, and through the esophageal hiatus to the gastrointestinal tract. The axons of these neurons extend as far as the descending colon. The ganglia are in the muscular walls of the organ they supply (intramural ganglia); the postganglionic axons are very short, terminating in smooth muscle and glands.

The cell bodies of the sacral preganglionic neurons are located in the lateral horns of sacral segments 2, 3, and 4 of the spinal cord. Their axons leave the cord via the anterior rami but form their own nerves called the pelvic splanchnic nerves (nervi splanchnici). These nerves project to the pelvis, mix with sympathetic postganglionics in the pelvic plexus, and depart for their target organs. They synapse with the postganglionic neurons in intramural ganglia in the wall of the organ supplied. These fibers stimulate contraction of rectal and bladder musculature, and induce vasodilation of vessels to the penis and clitoris (erection).

The parasympathetic and sympathetic divisions of the autonomic nervous system are not antagonistic. Their respective activities are coordinated and synchronized to achieve dynamic stability of body function during a broad range of life functions such as eating, running, fear, relaxation, and so on.

#### SCHEME OF THE PARASYMPATHETIC DIVISION



# XIV. NERVOUS SYSTEM

## PNS: SENSORY RECEPTORS

CH: Use your lightest colors for A and E. (1) Begin with the overview of a sensory pathway. (2) Color the general exteroceptors. Note that each receptor is connected to a sensory neuron (3) of a different color. (3) Color the proprioceptors in the lower illustration. Color over the entire muscle spindle, but not the surrounding muscle fibers.

Sensory receptors provide information to the brain about the internal and external environment of the body. Most receptors are transducers; they convert mechanical, chemical, electrical or light stimuli to electrochemical impulses that can be conducted by the nervous system. Once generated, informational or sensory impulses travel to the CNS via sensory neurons, ultimately reaching the thalamus. Here impulses are relayed to the sensory cortex (conscious interpretation) or to motor centers for appropriate (reflexive) response.

### EXTEROCEPTORS: A

SPECIAL: A  
GENERAL: A

- TOUCH / TACTILE R. A
- THERMORECEPTOR A
- MEISSNER'S ENDING A
- FREE NERVE ENDING A

Exteroceptors are located near the body surface. Special exteroceptors (not shown here) include the photoreceptors of the retina (light stimuli), taste receptors (chemical stimuli), and auditory receptors (sound stimuli). General exteroceptors include free nerve endings and encapsulated endings sensitive to touch, temperature change, and pain at the body surface. Touch receptors include those that encircle hair follicles and hair shafts, and tactile discs (of Merkel) below the epidermis. Touch-sensitive Meissner's endings (corpuscles) occur mainly in thick skin without hair, fitting in the cones of dermal papillae. Thermoreceptors (sensitive to temperature change) may be free endings or encapsulated bodies. Free nerve endings in the skin can be found in and deep to the epidermis. They may be sensitive to touch, heat, cold, and/or pain (nociception). Free nerve endings sensitive to a number of different stimuli are called polymodal receptors (sensitive to more than one kind of stimulus).

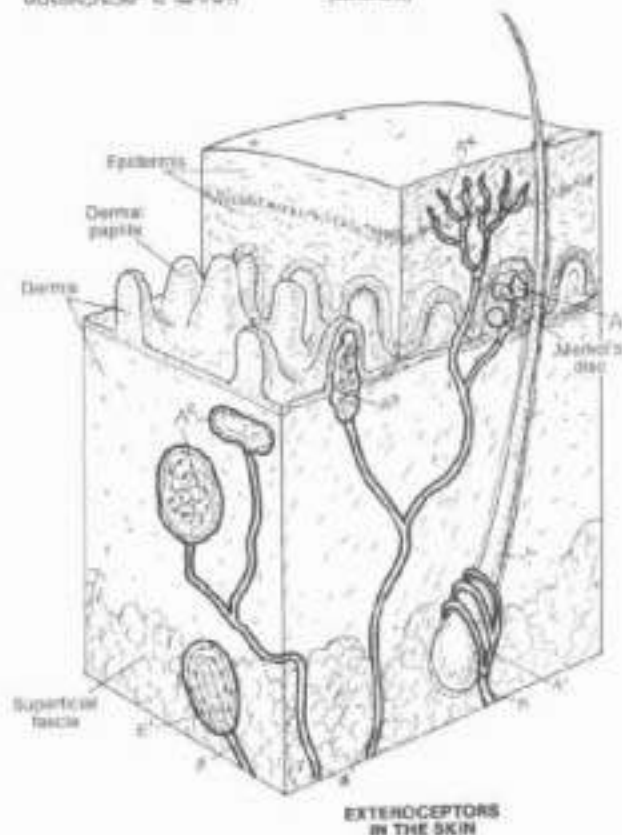
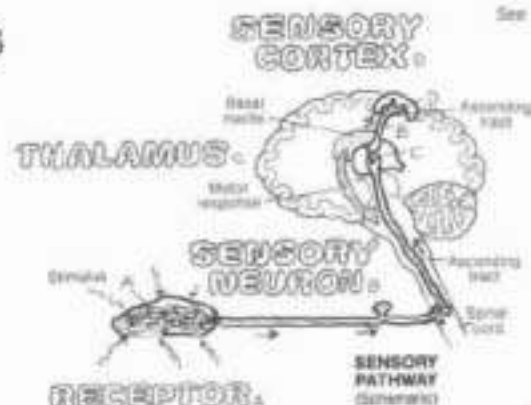
### PROPRIOCEPTORS: E

FACINIAN CORPUSCLE: E  
MUSCLE SPINDLE: E  
NEUROTENDINOUS ORGAN: E

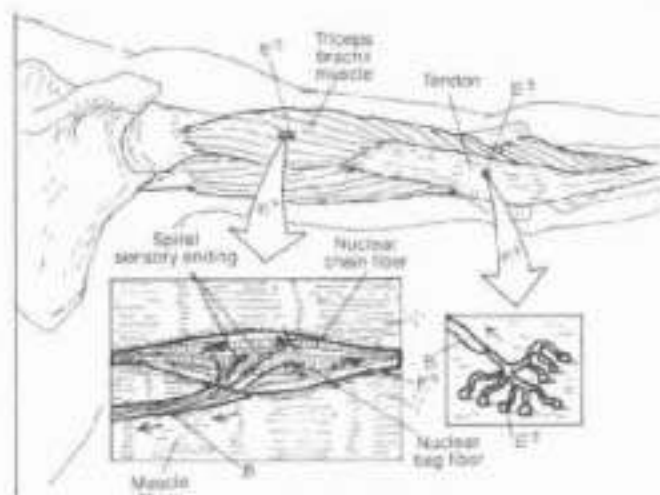
Proprioceptors are found in deeper tissues (superficial fascia, deep fascia, tendons, ligaments, muscles, joint capsules, and so on) of the musculoskeletal system. They are sensitive to stretch, movement, pressure, and changes in position. The Pacinian corpuscles are large lamellar bodies acting as mechanoreceptors; distortion of their onion skin-like lamellae induces generation of an electrochemical impulse. Muscle spindles, sensitive to stretch, consist of two types of special muscle fibers (nuclear bag and nuclear chain) entrained with spiral or flower-spray sensory endings. Stretch of these spindles (and the skeletal muscle in which they are located) induces discharges in the sensory fibers. These impulses reach the cerebellum. Reflexive motor commands tighten the special muscle fibers and increase resistance of the skeletal muscle to stretch. By these spindles, the CNS controls muscle tone and muscle contraction. Neurotendinous organs (Golgi) are nerve endings enclosed in capsules located at muscle/tendon junctions or in tendons. They are induced to generate electrochemical impulses in response to tendon deformation or stretch.

### INTEROCEPTORS: E

Interoceptors (not shown) are free or encapsulated nerve endings, often in association with special epithelial cells, located in the walls of vessels and viscera. These receptors include chemoreceptors, baroreceptors (pressure), and nociceptors. They generally are not sensitive to the same stimuli to which exteroceptors react.



EXTEROCEPTORS IN THE SKIN



PROPRIOCEPTORS IN DEEP TISSUE



# XIV. NERVOUS SYSTEM

## SPECIAL SENSES: VISUAL SYSTEM 1

On the yellow for M, red for N, blue for O, and very light colors for C, H, L, and K. (1) Color the sagittal section of the eyeball and the uppermost illustration simultaneously. (2) When coloring the retinal layers, color gray the arrows (in dark outlines) representing the nerve impulse traveling opposite to the direction of the light rays.

### EYE LAYERS:

SCLEERA / CORNEA

CHOROID

CILIARY BODY / PROCESS

IRIS

RETINA

OPTIC DISC

FOVEA CENTRALIS

### FLUIDS:

VITREOUS BODY

AQUEOUS HUMOR

### OTHER STRUCTURES:

LENS

SUSPENSORY LIG.

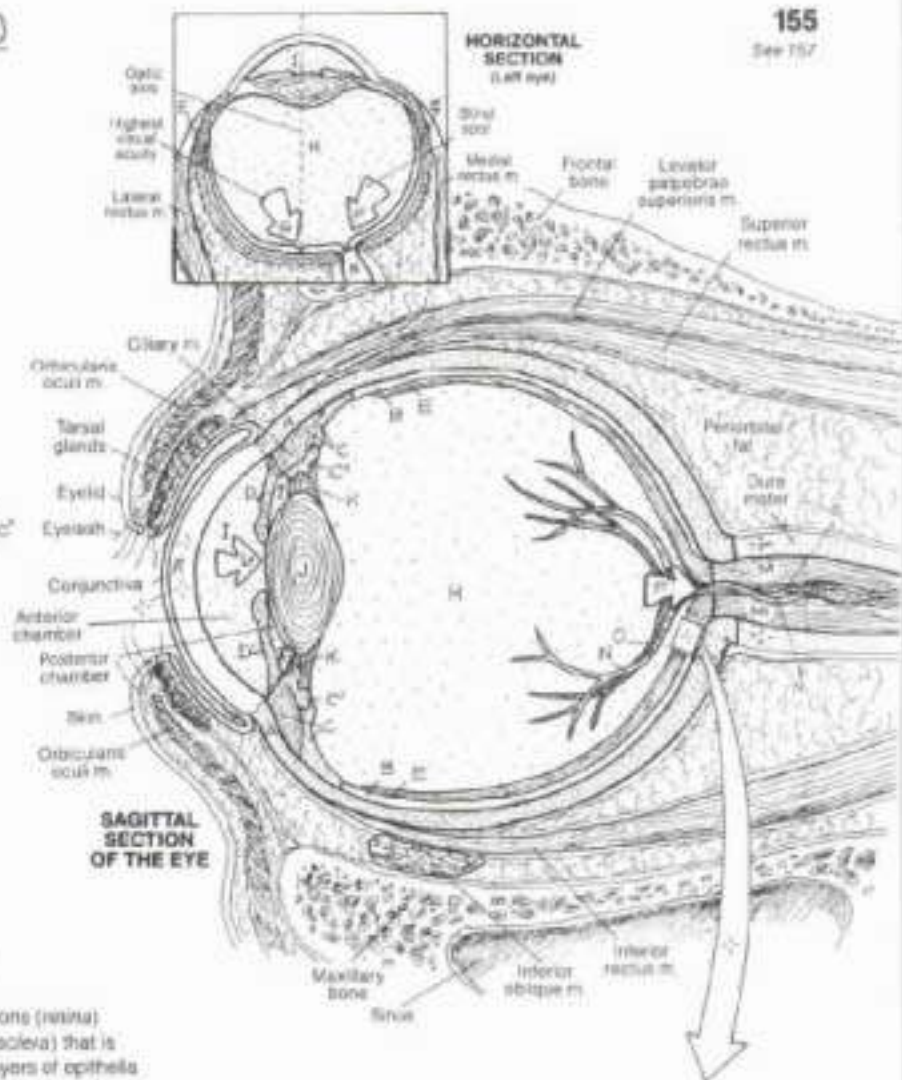
PUPIL

OPTIC NERVE

RETINAL ARTERY / VEIN

The eye is a layer of photoreceptor cells and associated neurons (retina) packaged within a white, fibrous, rubberlike protective globe (sclera) that is transparent in front (cornea). The cornea, composed of five layers of epithelia and fibrous tissue, is the chief refractive medium of the eye, focusing light rays onto the retina. The lens (slightly packed, encapsulated non-elastic lens fibers derived from epithelial cells) also refracts light, and up to middle age, can vary its shape (and refractive index). The aqueous humor (extracellular fluid) filling the anterior and posterior chambers of the eye, and the more gelatinous (99% water) vitreous humor taking up 80% of the globe's volume, all function as refractive media. The inner surface of the posterior two-thirds of the sclera is lined with a vascular, highly pigmented layer (choroid) that absorbs and prevents scattering of light. The choroid thickens anteriorly as the pigmented, fibromuscular ciliary body that surrounds the lens. The ciliary body projects outpocketings (processes) to which suspensory ligaments from the lens attach. On the anterior aspect of the ciliary body, a thin, pigmented, epithelial and fibromuscular layer (iris) circumscribes the hole (pupil) in front of the lens.

The retina lines a bit more than the posterior half of the globe, lying superficial to the choroid and against the vitreous. It is a highly vascular membrane, complexly composed of several interlacing layers of cells. At about the center of the retina, a yellow pigmented area (macula lutea) with a clearly depressed region characterized by a dense accumulation of light-sensitive cells (cones) occurs. This site (fovea centralis) represents the center of greatest visual acuity (clarity of form and color) under lighted conditions. About 3mm to the nose-side of the macula lutea, the axons of the optic tract (nerve) and retinal arteries/veins stream out of the globe (optic disc). Absent neurons, it is an area from which no vision is possible (blind spot). The retina, derived from an evagination of the diencephalon, consists of a deep layer of photoreceptor cells (cones sensitive to form and color; rods with greatest sensitivity to light) that synapse with bipolar cells (neurons) that synapse with ganglion cells (neurons) whose axons form the optic tract (nerve) fibers. Not shown are interneurons and related multiple synapses. The visual stimulus is initiated by light rays interacting with visual purple pigment (rhodopsin) in rod cells and the pigment iodopsin in cone cells. These interactions induce an electrochemical stimulus that can be conducted through neurons on to the CNS.



### LAYERS OF RETINA:

AXON

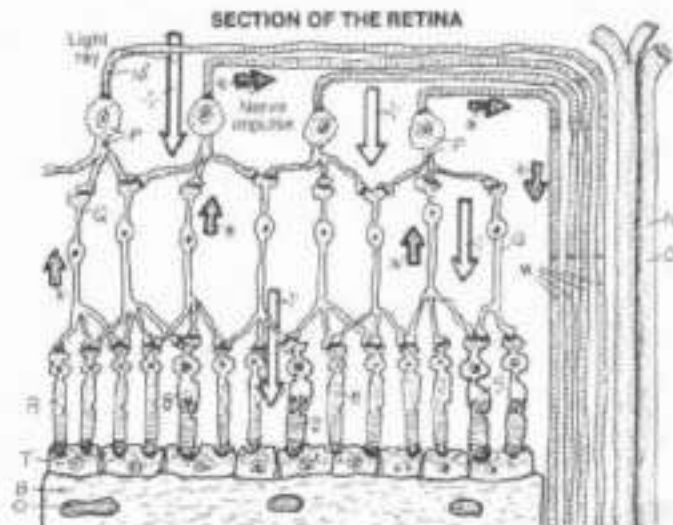
GANGLION CELL

BIPOLAR CELL

ROD CELL

CONE CELL

PIGMENTED EPITHELIUM





## XIV. NERVOUS SYSTEM

### SPECIAL SENSES: VISUAL SYSTEM (2)

CH. Use the same colors as were used on the previous plate (with different subscripts) for structures J, K, L, M, N, and O. Use light colors for A, G, H, and I. Note that various structures in the central illustration also appear in the illustration below it.

### ACCESSORY STRUCTURES:

#### LACRIMAL APPARATUS:

LACRIMAL GLAND, TEAR  
DUCT,

LACRIMAL PUNCTA,  
CANAL,

LACRIMAL SAC,  
NASOLACRIMAL DUCT,

#### INFERIOR MEATUS OF NASAL CAVITY:

#### TARSAL PLATE/GLAND + CONJUNCTIVA:

Fluid (tears) interfacing the conjunctivae of the eyelid (palpebrae) and the cornea facilitate easy movement of the lids over the cornea without inducing irritation. Tears also function as a vehicle for moving epithelial debris and microorganisms from the corneal surface and undersurface of the eyelids into the nasal cavity via the lacrimal apparatus. Thus, there is an anatomic basis for blowing your nose after a good cry. The absence of tears can cause remarkable pain and even blindness. The principal gland for tears is the lacrimal gland, located in the anterior, superior and lateral (temporal) aspect of the orbit. Other glands and sources of tears include unicellular (goblet) glands of the conjunctiva and tarsal glands of the lids. Episodic blinking (rapid cycle of lid approximation and retraction) maintains a film of tears on the conjunctiva and resists "dry eye." Routine closing of the lids occurs with muscle relaxation; energetic closure requires the orbicularis oculi muscle. Retraction of the eyelids is accomplished by smooth muscle fibers (tarsal muscle of Muller, sympathetic innervation) and the levator palpebrae muscle in the upper lid.

### SECRETION / DRAINAGE OF AQUEOUS HUMOR:

#### FLOW OF AQUEOUS HUMOR:

SCLERA / CORNEA,

CILIARY BODY, PROCESS,

POSTERIOR CHAMBER,

IRIS,

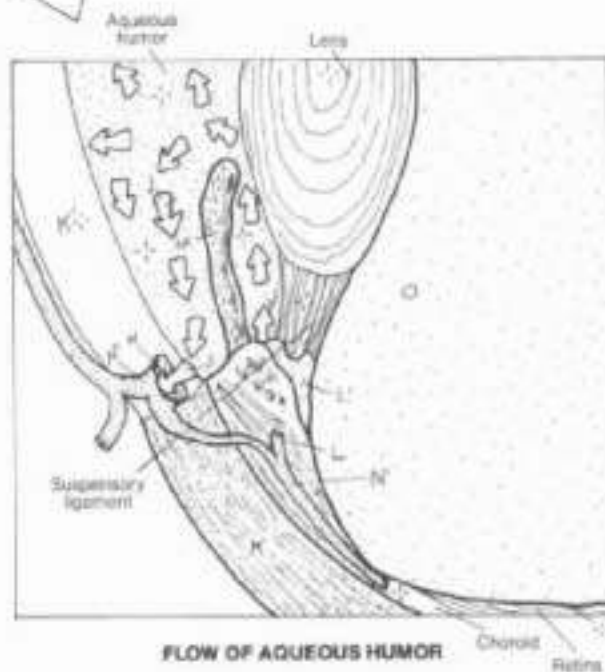
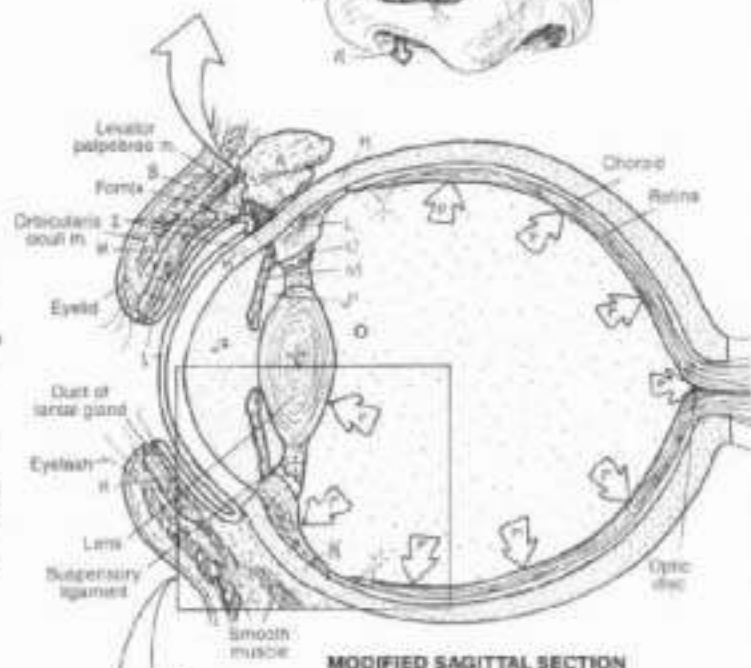
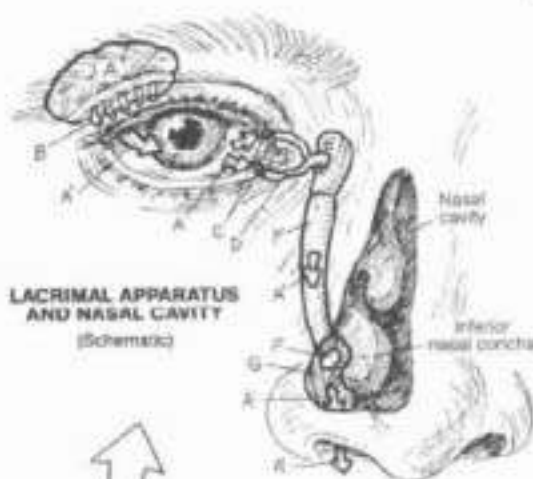
ANTERIOR CHAMBER,

CANAL OF SCHLEMM, VEIN,

#### VITREOUS BODY,

#### INTRACULAR PRESSURE (IOP):

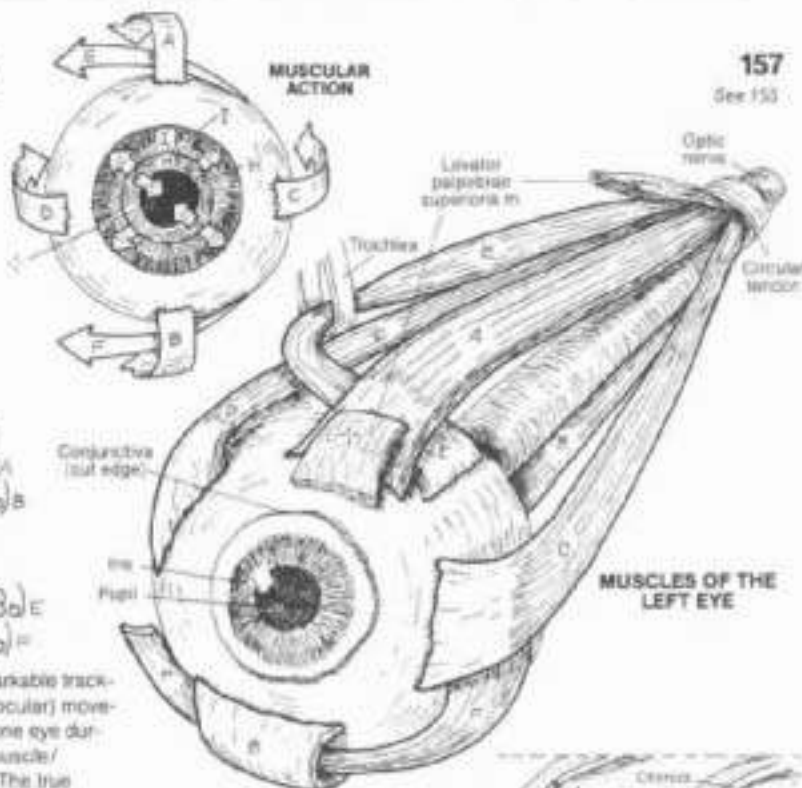
Aqueous humor is a fluid in the anterior and posterior chambers of the eye, secreted by cells of the ciliary processes. Fluid and electrolytes also enter by diffusion from the ciliary body. Aqueous humor is a clear, plasma-like fluid (but constituted differently). It is filtered into the canal of Schlemm (scleral venous sinus), a modified vein filled with fibrous trabeculae, located at the sclero-corneal junction. Fluid in the canal drains into nearby veins. Obstruction to drainage is one of several causes of increased intraocular pressure, in which the increasing pressure in the anterior/posterior chambers presses on the lens which presses on the vitreous (99% water). As water cannot be compressed, pressure is applied to the contiguous retina. Unrelenting pressure compresses vessels to the axons and neurons of the retina, damages neurons, and can result in blindness (glaucoma).



# XIV. NERVOUS SYSTEM

## SPECIAL SENSES: VISUAL SYSTEM (3)

Dir. Use light colors for A-F, H, and I. Use contrasting colors for J and K. (1) After coloring each eye muscle, color its functional arrow in the upper diagram. (2) In the drawing on ciliary action, only color the contracted ciliary muscles. (3) Carefully color the diagram below, noting that only the first 'tiles' (visual field) receive J and K colors. The rest of the tiles are to be colored grey but use two colors on the structures in the diagram.



- EXTRAOCULAR MUSCLES:**
- 1. SUPERIOR RECTUS (ELEV.)<sub>A</sub>
  - 2. INFERIOR RECTUS (DEPR.)<sub>B</sub>
  - 3. LATERAL RECTUS (ABD.)<sub>C</sub>
  - 4. MEDIAL RECTUS (ADD.)<sub>D</sub>
  - 5. SUPERIOR OBLIQUE (ROT. R.)<sub>E</sub>
  - 6. INFERIOR OBLIQUE (ROT. L.)<sub>F</sub>

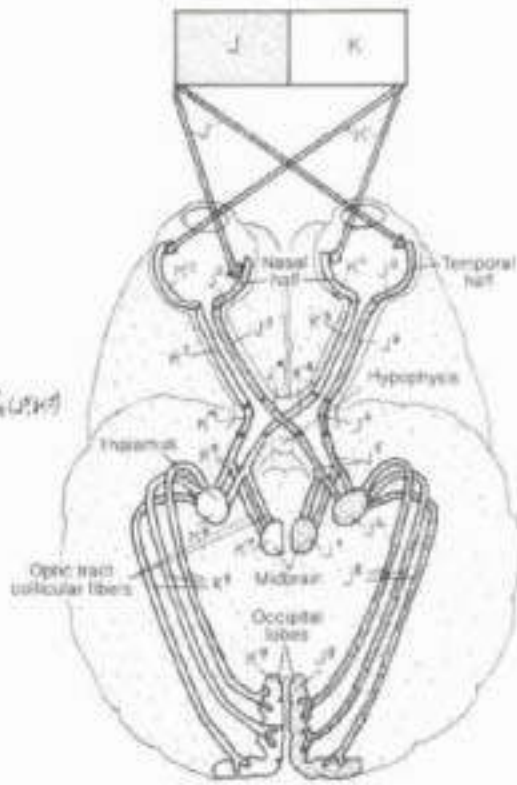
The extraocular (extrinsic) muscles of the eye provide for a remarkable tracking capacity of the eyes. CNS mechanisms permit conjugate (binocular) movement of both eyes. Slowed, incomplete, or absent movement of one eye during tracking movements suggests cranial nerve dysfunction or muscle/lendon incarceration, as might occur in an orbital plate fracture. The true functions of these muscles is more complex than shown, one reason being eye rotation and torsion requiring multiple muscle action. Deviation from coequal alignment of the eyes is called strabismus.

- INTRINSIC MUSCLES:**
- 7. CILIARY:
  - 8. SPHINCTER PUPILLAE<sub>H</sub>
  - 9. DILATOR PUPILLAE<sub>I</sub>

The intrinsic muscles are located in the ciliary body (ciliary muscle) and the iris (pupillary dilator and sphincter). Contraction of the ciliary muscles (1) wrinkles the ciliary body tissue and puts slack in the processes, giving slack to the suspensory ligaments (2) and permitting the lens to round up on its own accord (tension in lens fibers) (3). These muscles function (by parasympathetic innervation) during near vision in which greater refractivity is desired. The dilator pupillae consists of myoepithelial cells that pull the iris toward the ciliary body, dilating the pupil (sympathetic innervation). The sphincter pupillae circumscribes the inner iris; its contraction constricts the iris, narrowing the pupil (parasympathetic innervation). See the uppermost drawing.

- VISUAL PATHWAYS:**
- 10. VISUAL FIELD<sub>J</sub> / VISUAL FIELD<sub>K</sub>
  - 11. LIGHT WAVE<sub>L, K</sub>
  - 12. RETINA<sub>M, N</sub>
  - 13. OPTIC NERVE<sub>O, P, Q</sub> / CHIASMA<sub>R, S, T</sub> / TRACT<sub>U, V, W</sub>
  - 14. LATERAL GENICULATE BODY<sub>X, Y, Z</sub>
  - 15. SUPERIOR COLLICULUS<sub>AA, AB, AC</sub>
  - 16. OPTIC RADIATION<sub>AD, AE, AF</sub>
  - 17. VISUAL CORTEX<sub>AG, AH, AI</sub>

As you color the lower diagram, note that the axons (K) from the retina on the temporal side of the optic axis do not cross at the chiasma. Note further that an expanding tumor of the hypophysis is likely to impair visual acuity in the temporal visual fields only ("tunnel vision"). The thalamus functions as a visual relay center, informing multiple memory areas and other centers of the stimulus. The superior colliculi are visual reflex centers, making possible rapid head and body movements in response to a visual threat. Finally, note that the image of the stimulus impinging on the visual cortex (K/J) is the reverse of that which was actually seen (J/K). Integration of visual and memory centers at the visual cortex makes possible perception of the image as actually seen.



**VISUAL PATHWAYS**  
(Horizontal brain section, schematic)



## KIV. NERVOUS SYSTEM

### SPECIAL SENSES: AUDITORY & VESTIBULAR SYSTEMS (1)

On Use yellow for Z, and light colors for A, B, G, I, M, N, S, and X. The view of the internal ear is magnified in the upper illustration for coloring purposes. Color your way down the plate, beginning with the diagram at the top.

#### EXTERNAL EAR:

AURICLE.  
EXT. AUDITORY MEATUS:  
TYMPANIC MEMBRANE:

#### MIDDLE EAR:

MALLEUS.  
INCUS.  
STAPES.  
AUDITORY TUBE.

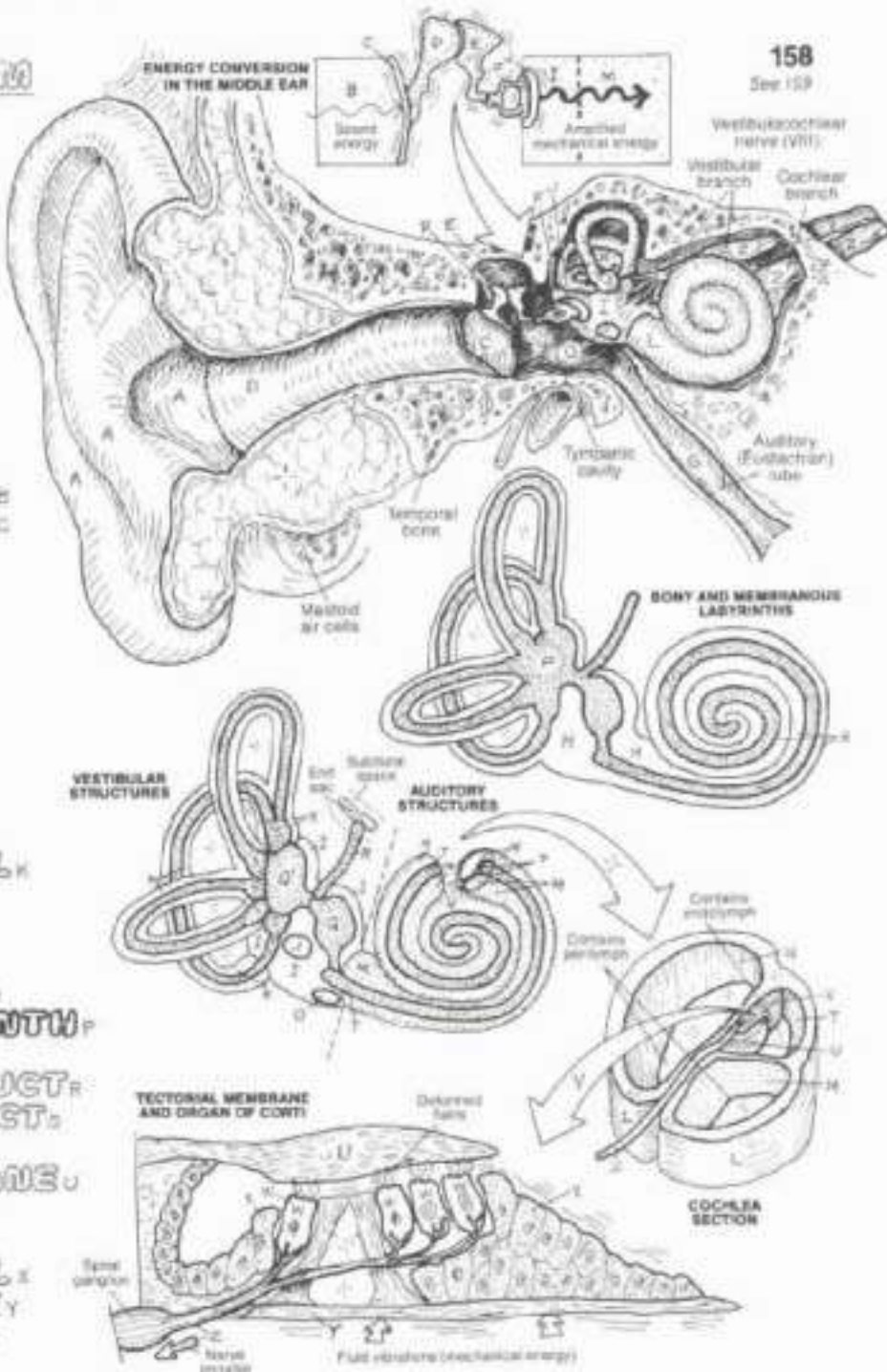
#### INTERNAL EAR: BONY LABYRINTH:

VESTIBULE:  
OVAL WINDOW.  
SEMICIRCULAR CANAL:  
COCHLEA.

SCALA VESTIBULI:  
SCALA TYMPANI:  
ROUND WINDOW.  
MEMBRANOUS LABYRINTH:

SACCULE, UTRICLE:  
ENDOLYMPHATIC DUCT:  
SEMICIRCULAR DUCT:  
COCHLEAR DUCT:  
TECTORIAL MEMBRANE:  
ORGAN OF CORTI.

HAIR CELL:  
SUPPORTING CELL:  
BASILAR MEMBRANE:  
CRANIAL NERVE VIII:



The ear is the organ of hearing and equilibrium (auditory and vestibular systems). It is organized into external, middle, and internal parts. The external ear includes the auricle (collector of sound energy) and the external auditory meatus or canal (a narrow passageway conducting sound energy to the tympanic membrane). This membrane, lined externally by skin and internally by respiratory mucosa, converts sound energy into mechanical energy by vibrating in response to incoming sound waves.

The middle ear is a small area filled with much structure, including three small bones (malleus, incus, stapes) joined together by synovial joints. These ossicles vibrate with movement of the tympanic membrane, amplify and conduct the mechanical energy imparted to them to the waters of the inner ear at the flexible, water-tight oval window (middle ear/inner ear interface). At the anterior-medial aspect of the middle ear cavity, the auditory tube runs to the nasopharynx, permitting equilibration of air pressure between nasal cavity (outside) and the middle ear. The internal ear carved out within the petrous portion of the temporal

bone, consists of a series of interconnecting bony-walled chambers and passageways (bony labyrinth: vestibule, semicircular canals, and cochlea) filled with perilymph (extracellular-like) fluid. Within the bony labyrinth is a series of interconnecting membranous chambers and passageways (membranous labyrinth: saccule, utricle, cochlear duct, and semicircular ducts), filled with endolymph (intracellular-like) fluid. The endolymphatic duct, derived from the saccule, ends in a blind sac under the dura mater near the internal auditory meatus (see Plate 20). It drains endolymph and discharges it into veins in the subdural space. Within the coiled, membranous cochlear duct, supported by bone and the fibrous basilar membrane, a ribbon of specialized receptor (hair) cells exists integrated with supporting cells, both covered with a flexible, fibrous glycoprotein blanket (tectorial membrane). This device (Organ of Corti) converts the mechanical energy of the oscillating tectorial membrane scraping against the receptor hair cells into electrical energy. The impulses generated are conducted along bipolar sensory (auditory) neurons of the VIII cranial nerve. Continued on the next plate.

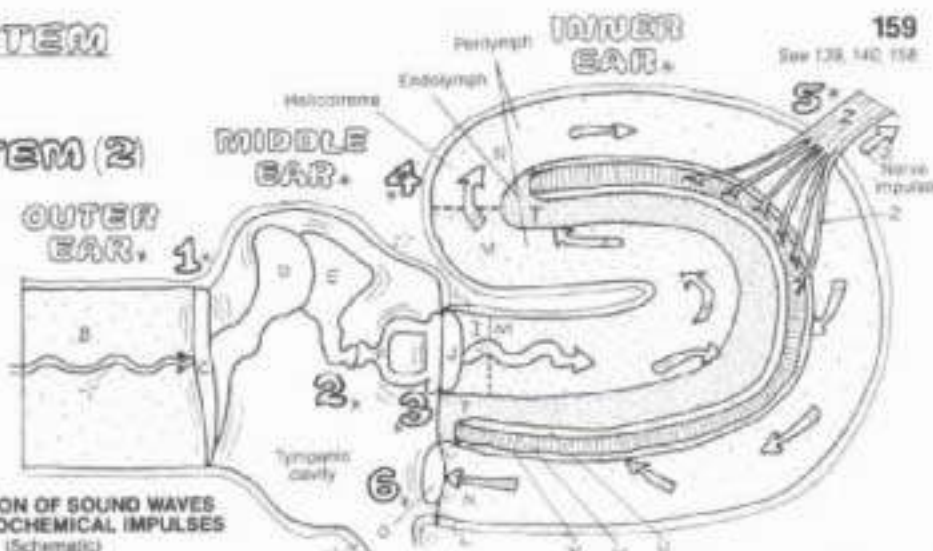


# XIV. NERVOUS SYSTEM

## SPECIAL SENSES: AUDITORY & VESTIBULAR SYSTEM (2)

CR: Titles with subscripts 1, 2, and 3 require new colors, all other subscripts refer to lines and colors used on the preceding plate which should be frequently referred to when using those same colors on this plate. (1) Color the step numerals gray as you follow the sequence of events in the simplified diagram to the right. See the previous plate for the more accurate anatomical structure. (2) Color the parts of the vestibular system concerned with the maintenance of dynamic and static balance.

### CONVERSION OF SOUND WAVES TO ELECTROCHEMICAL IMPULSES (Schematic)

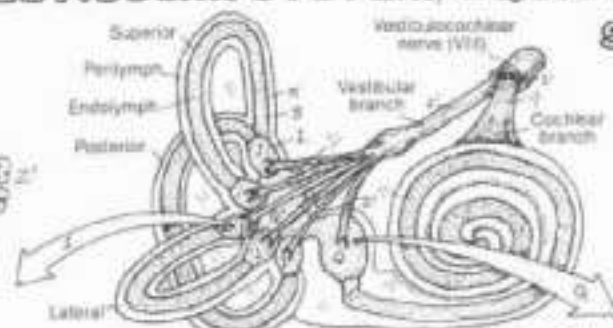


In review: the external ear collects sound waves and rifles them to the tympanic membrane which converts the sound energy into mechanical energy. The leverage of ossicles increases the amplitude of the energy and transmits the force to the oval window of the bony labyrinth of the inner ear. Vibratory movements of the stapes in the window are transmitted to the perilymph of the vestibule of the bony labyrinth, creating wave-like motions of the fluid. These waves spread throughout the vestibule, enter and move through the scala vestibuli of the cochlea to the helicotrema at the apex of the cochlea (taking two and a half turns), and on around to the scala tympani which terminates at the round win-

dow. Here, fluid waves and vibrations are dampened. The fluid motion in the scala vestibuli vibrates the roof of the membranous cochlear duct, creating endolymph waves in the cochlear duct. This motion stirs the tectorial membrane which rubs against and bends the hair-like processes of the receptor (hair) cells, depolarizing them, inducing electrochemical impulses. These impulses are conducted by the sensory neurons of the cochlear division of the VIII cranial nerve. Stimulation of the hair cells at the base of the cochlea produces perceptions of high-pitched sounds; stimulation of the hair cells at the helicotrema produce perceptions of low-pitched sounds.

## VESTIBULAR SYSTEM / EQUILIBRIUM.

**AMPULLA:**  
**CRISTA:**  
**CUPOLA:**  
**HAIR CELL:**  
**NERVE FIBER:**  
**SUPPORTING CELL:**

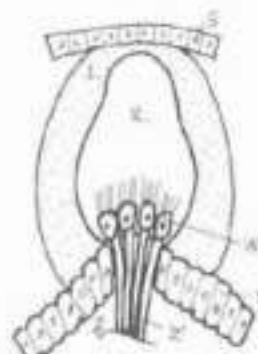


**SAGGULE, UTRICLE:**  
**MACULA:**  
**GELATINOUS LAYER:**  
**OTOLITH:**  
**HAIR CELL:**  
**NERVE FIBER:**  
**SUPPORTING CELL:**

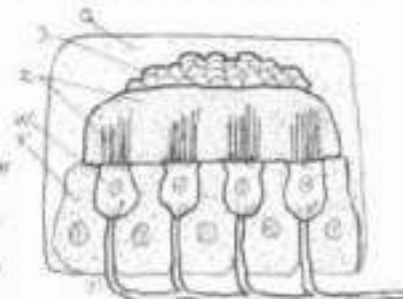
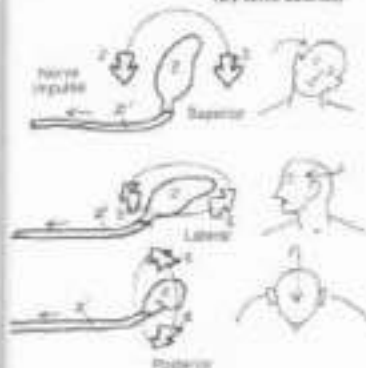
### SEMICIRCULAR CANAL / SEMICIRCULAR DUCT.

In review: the vestibular system is located in the inner ear. The bony semicircular canals are oriented at 90° to one another. Within these canals are the membranous semicircular ducts. Directly communicating with the utricle at one end, each duct terminates at the other end in an ampulla. Within the saccule/utricle and the ampullae are sensors responsive to fluid (endolymph) movement. Each ampulla has a hillock of cells (crista or crist) consisting of receptor (hair) and supporting cells. The hair-like processes of these receptor cells are embedded in a top-heavy, gelatinous cupola (like an inverted cup). Movement of endolymph in response to head turning, and especially rotation, pushes these cupolas, bending the hair cells, and causing them to depolarize, generating an electrochemical impulse. The impulses travel out the vestibular part of the VIII nerve to the vestibular nuclei in the lower brain stem. When the body is rotated rapidly, horizontal, oscillatory eye movements occur (nystagmus). These eye movements are mediated by ampullary sensory input to the brain stem. Such movements represent the brain's attempt to maintain spatial orientation (by momentary visual fixation) during head and/or body rotation. Sensations of rotational movement in the absence of body rotation is called vertigo.

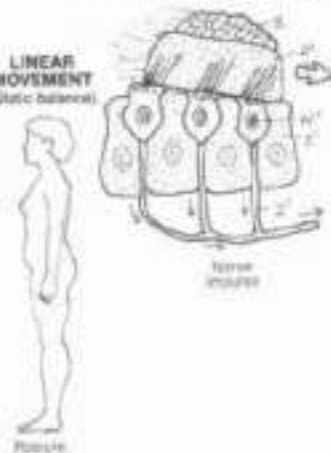
Within the utricle/sacculus, hair cells and their supporting cells are covered with a gelatinous layer in which are embedded small calcareous bodies (otoliths). Movement of the endolymph induces movement of the gelatinous layer against the hair cells, with responses identical to those of the ampullary receptors. Receptor activity in the utricle/sacculus is influenced by linear (horizontal and vertical, but non-rotational) acceleration of the body. Vestibular receptors have strong neural connections with cranial nerve nuclei concerned with eye movement and with postural motor centers.



#### ROTATIONAL MOVEMENT (Dynamic balance)



#### LINEAR MOVEMENT (Static balance)



# XIV. NERVOUS SYSTEM

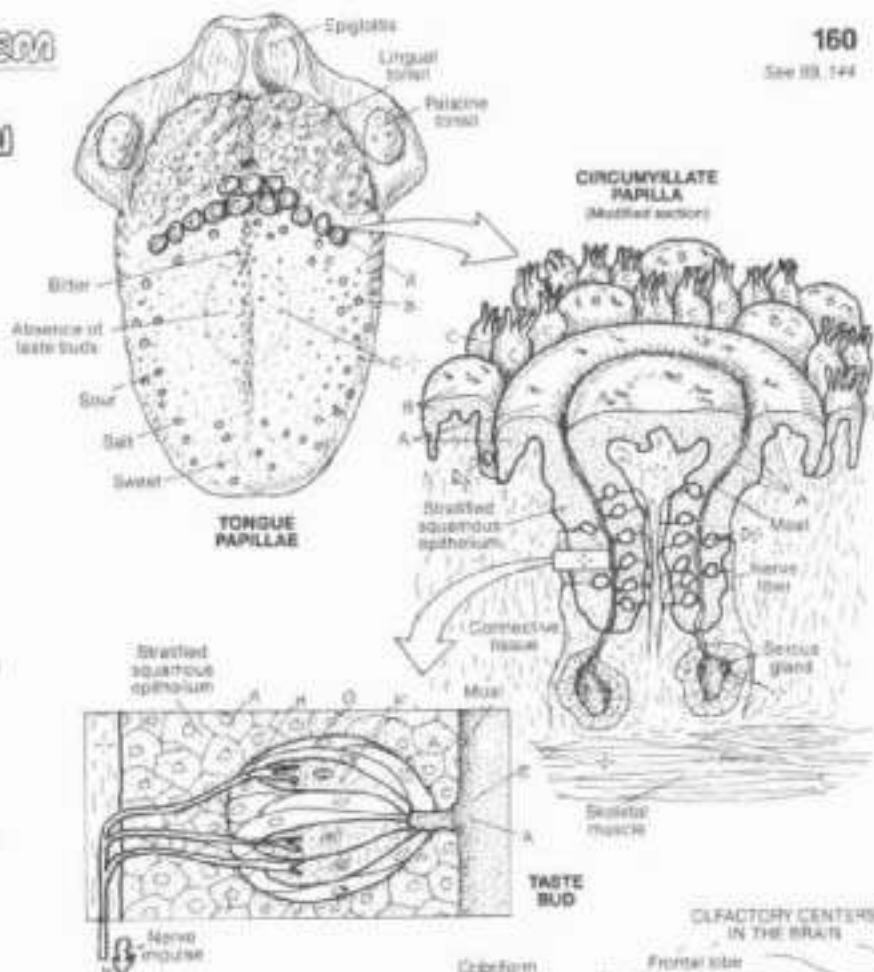
## SPECIAL SENSES: TASTE & OLFACTION

24. Use yellow for H and light colors for A, B, C, G, and I. (1) Do not color the taste buds in the circumvallate papillae in the modified section at right. (2) In the lowest illustration, color over the neurons within the olfactory bulb.

**PAPILLAE:**  
CIRCUMVALLATE,  
FUNGIFORM,  
FILIFORM

**TASTE BUD:**  
PORE CANAL,  
RECEPTOR CELL,  
SUPPORTING CELL,  
NERVE FIBER

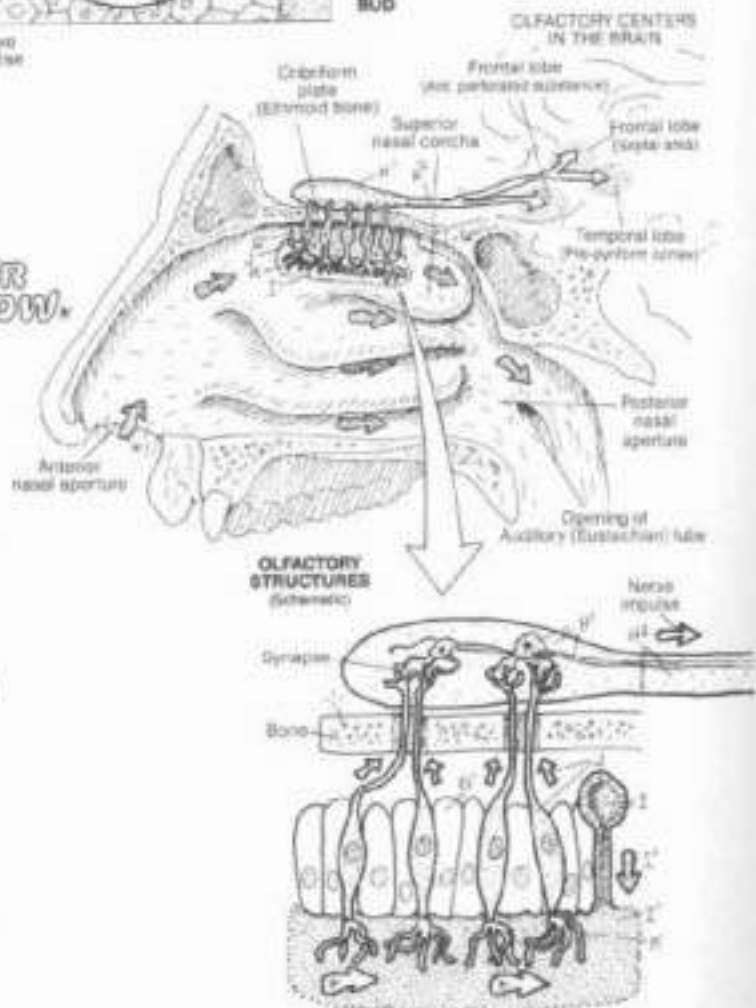
Taste receptors (taste buds) are located within the stratified squamous epithelial lining of the sides (moats) of circumvallate, foliate (not shown) and fungiform papillae on the tongue, and to a lesser extent, on the soft palate and lingual side of the epiglottis. They are not seen in the tiny filiform papillae. Each taste bud consists of a number of receptor cells and their supporting cells. The apes of this oval cell complex faces the moat; here it opens on to the papillary surface via a taste pore or pore canal. Dissolved material enters the pore, stimulating the chemoreceptor (gustatory) cells. The impulses generated are conducted along sensory axons which reach the brain stem via the VII, IX, and X cranial nerves (recall Plate 144). Taste interpretation occurs at the lower reaches of the sensory cortex (post-central gyrus). Basic tastes (sweet, sour, salt, and bitter) notwithstanding, interpretation of taste, as a practical matter, is a function of smell, food texture, and temperature in association with taste bud sensations.



**AIR FLOW.**

**OLFACTION (SMELL):**  
OLFACTORY GLAND,  
OLFACTORY MUCOSA,  
OLFACTORY NEURON,  
OLFACTORY HAIR (CILIA),  
SUPPORTING CELL,  
OLFACTORY BULB,  
OLFACTORY TRACT

Olfactory receptors are olfactory hairs or cilia (actually modified peripheral processes) of olfactory bipolar (sensory) neurons, buried in the olfactory mucosa at the roof of the nasal cavity. The olfactory mucosa also has tubulo-alkveolar olfactory glands that function to keep the chemoreceptor endings clean and, along with nasal mucous secretions, dissolve the chemicals that are sensed by these receptors. The olfactory neurons ascend the roof of the nasal cavity, through the cribriform plate of the ethmoid bone, and their central processes synapse with second order neurons in the olfactory bulb. The axons of these neurons form three olfactory bundles (stria) as part of the olfactory tract, terminating in the inferior frontal lobe and medial temporal lobe. Here exists the neural basis for olfactory relationships with memory, eating, survival, sex, and other emotional behavior.





# XV. INTEGUMENTARY SYSTEM

## THE INTEGUMENT

Ch. Use yellow for G, red for H, blue for I, and green for J like light colors for A, D, F, R and Q. (1) Note that for every structure shown, there are many more within each section. (2) The atrium lucidum (B) is found only in sections of hairless skin.

### EPIDERMIS:

STRATUM CORNEUM<sup>A</sup>  
STRATUM LUCIDUM<sup>B</sup>  
STRATUM GRANULOSUM<sup>C</sup>  
STRATUM SPINOSUM<sup>D</sup>  
STRATUM BASALE<sup>E</sup>  
(GERMINATING LAYER)<sup>E</sup>


### DERMIS:

CONNECTIVE TISSUE<sup>F</sup>  
PAPILLAE<sup>F</sup>  
NERVE / RECEPTOR<sup>G</sup>  
ARTERY, VEIN<sup>H</sup>  
LYMPHATIC VESSEL<sup>I</sup>

### HAIR:

SHAFT<sup>J</sup>  
FOLLICLE<sup>K</sup>  
BULB<sup>L</sup> MATRIX<sup>M</sup>  
DERMAL PAPILLA<sup>N</sup>  
ARRECTOR PILI MUSCLE<sup>O</sup>  
SEBACEOUS GLAND<sup>P</sup>  
SWEAT GLAND<sup>Q</sup>

### SUPERFICIAL FASCIA<sup>R</sup>



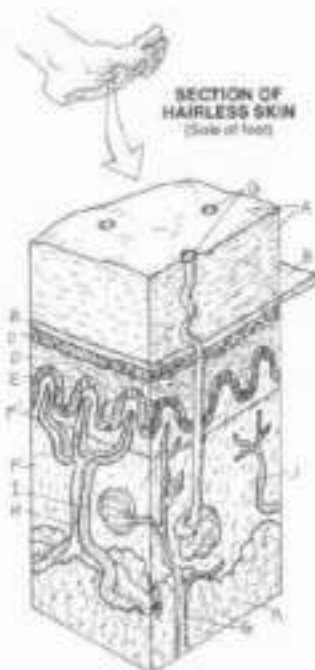
"There is no magician's mantle to compare with the skin in its diverse roles of waterproof, overcoat, sunshade, suit of armour and refrigerator, sensitive to the touch of a feather, to temperature, and to pain, withstanding the wear and tear of three score years and ten, and executing its own running repairs. This vital organ of the body, 16-20 square feet in extent (the child at birth has three times the area relative to the body weight), holds the mirror to age and health even revealing general conditions such as fever, jaundice, syphilis, deficiency diseases and poisons."

The integument is variably thick, from the sole of the foot with tens of layers of keratinized stratified squamous epithelia to the eyelid skin with about four layers of epidermis. Some skin is hairy, some is not. Some skin is exquisitely sensitive (face, finger tips) and some not (back, soles). It comes in a variety of colors. No matter these variations, all skin has common structural characteristics. It has an epidermal layer of stratified squamous epithelium with a number of different layers. The atrium basale (germinativum) is the germinating layer from which all epidermal cells arise. This is convenient, for a significant vascular network (nutritional source) lies just deep to the avascular epidermis in the dermal cones or papillae. As epidermal cells get further away from this nutritional source, they dehydrate (stratum corneum) and die to be cast off with sweat or bath. Pigment-containing

cells (melanin, carotenes) are found in the stratum germinativum layer, skin color is a function of the concentration of these pigments primarily, but is influenced by the number of blood vessels, and the degree of vasoconstriction.

The dermis is replete with thick bundles of fibrous connective tissue, blood and lymphatic vessels, sensory receptors and related nerves, and glands. Sweat glands help stabilize body temperature by excreting in response to excessive body heat. Sebaceous glands, associated with hair follicles, excrete an oily substance (sebum) that resists dehydration. Hair arises from an ingrowth of epidermal (bulb) cells that pushed down into the dermis during development. The base or bottom of the follicle is the hair bulb which is invaginated (dermal papilla) and encloses capillaries. The bulb consists of a hair shaft (central medulla, outer cortex, outermost cuticle) surrounded by layers of cells (root sheath, membranes). Non-striated arrector pili muscles attach to the hair follicles and to the upper parts of the dermis. They straighten the hairs, perhaps enhancing preservation of body temperature. The skin is contiguous with the superficial fascia, a more fatty, loose connective tissue layer. Sense receptors of the skin are presented in Plate 154.

Quote taken with permission from Lockhart, R.D., Hamilton, G.F. and Pyle, F.W. ANATOMY OF THE HUMAN BODY, 2nd ed. Taylor and Francis Publishers, Ltd., London, 1965.



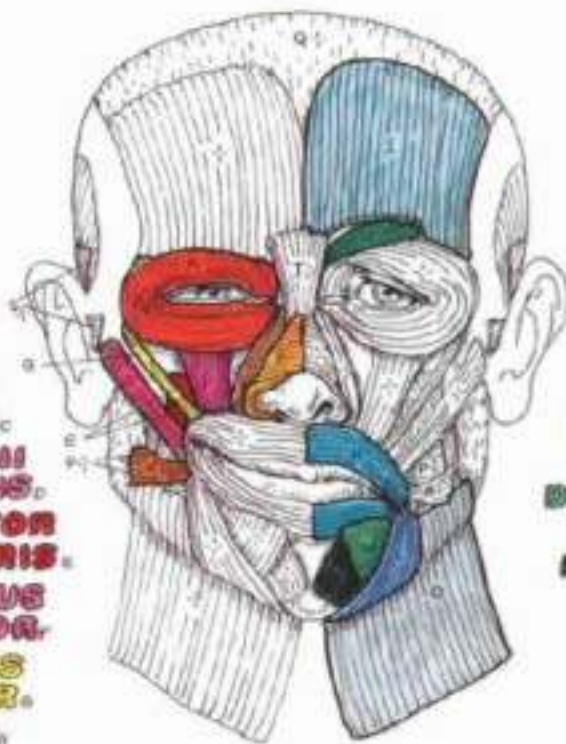
SECTION OF HAIRLESS SKIN  
(Sole of foot)



The **ANATOMY**  
**COLORING BOOK**

2nd Edition  
Revised and Expanded

**ORBICULARIS**  
**OCULI.**  
**MASSALIS.**  
**LEVATOR LABII**  
**SUPERIORIS**  
**ALAEQUE NASI.**  
**LEVATOR LABII**  
**SUPERIORIS.**  
**LEVATOR**  
**ANGULI ORIS.**  
**ZYGOMATICUS**  
**MAJOR.**  
**ZYGOMATICUS**  
**MINOR.**  
**RIGIDUS.**



**FRONTALIS.**  
**CORRUGATOR**  
**SUPERCILII.**  
**ORBICULARIS**  
**ORIS.**  
**DEPRESSOR**  
**ANGULI ORIS.**  
**DEPRESSOR LABII**  
**INFERIORIS.**  
**MENTALIS.**  
**PLATYSMA.**

This is the NEW, original ANATOMY COLORING BOOK! The illustrations have been redrawn, anatomically accurate, they have a fresh, crisp look ready for imaginative coloring. The text has been rewritten and updated, the print has been enlarged for easier reading. An index has been added for rapid referencing. A glossary of terms is a new feature, with phonetic spelling of unusual words enabling you to correctly pronounce and understand medical and anatomic terms.

A new section on the Immune System has been added, introducing the fundamentals of inflammation and immune responses in specific lymphoid organs and tissues, as well as a timely summary of the mechanism and effects of viral induced suppression of immune functions (AIDS).

This book offers an opportunity to all "students" of the body, formal or informal, professional health care student/practitioner or not, young and senior, to achieve a working understanding of body structure and related functions effectively and thoroughly . . . and find satisfaction doing it through active involvement in the coloring process!

ISBN 0-06-455016-8



9 780064 550161

90000